

<https://doi.org/10.33472/AFJBS.6.6.2024.1841-1847>



African Journal of Biological Sciences

Journal homepage: <http://www.afjbs.com>



Research Paper

Open Access

## Efficacy of Dexmedetomidine as an Adjuvant to Ropivacaine versus Ropivacaine Alone in Ultrasound-Guided Interscalene Block for Upper Limb Orthopedic Surgeries: A Randomized Controlled Trial

Rucha P. Patil<sup>1</sup>, Sumita V. Bhargava<sup>2</sup>, Ketaki S. Marodkar<sup>3</sup>, Anjali R Bhure<sup>4</sup>, Akanksha N. Upase<sup>5</sup>, Siddhi R. Rathod<sup>6\*</sup>, Aishwarya S. Pingley<sup>7</sup>

<sup>1,2,3,4,5,6\*,7</sup>Department of anaesthesiology NKP salve institute of medical sciences and research centre, Nagpur.

Corresponding author: Siddhi R. Rathod<sup>6\*</sup>

### Article Info

Volume 6, Issue 6, June 2024

Received: 16 March 2024

Accepted: 26 April 2024

Published: 01 June 2024

[doi: 10.33472/AFJBS.6.6.2024.1841-1847](https://doi.org/10.33472/AFJBS.6.6.2024.1841-1847)

### ABSTRACT:

Introduction According to a number of descriptions of retrospective analysis about the patient satisfaction level, compared with general anesthesia, the peripheral nerve block has many advantages. Peripheral nerve blocks in upper extremity surgeries improve postoperative pain management and reduce the need for narcotics, as well as the side effects of narcotics such as nausea and vomiting. Interscalene nerve block is performed in shoulder surgeries and lateral end clavicle surgeries. The results of brachial plexus blocks aided by ultrasound are promising and imply that ultrasonic imaging can help in nerve location and direct needle placement. Ropivacaine, a more recent local anesthetic, is an enantiomer of bupivacaine that has fewer neurotoxic and cardiac side effects. As it has no negative side effects, combining ropivacaine and dexmedetomidine in an interscalene block (ISB) results in earlier onset, longer duration, and superior patient satisfaction scores. This study was carried out to evaluate the effect of the combination of ropivacaine and dexmedetomidine for ultrasound-guided (USG) ISB in upper limb orthopedic surgeries in the local population.

**Keywords:** Interscalene brachial plexus block, ultrasound-guided blocks, ropivacaine, dexmedetomidine

© 2024 Rucha P. Patil, This is an open access article under the CC BY license (<https://creativecommons.org/licenses/by/4.0/>), which permits unrestricted use, distribution, and reproduction in any medium, provided you give appropriate credit to the original author(s) and the source, provide a link to the Creative Commons license, and indicate if changes were made

### **1. Settings and Design**

A hospital-based randomized double-blind study was conducted in the Department of Anesthesiology in a tertiary care center from January 2021 to December 2022, which comprised 64 patients who had undergone elective upper limb orthopedic surgeries. The study was performed after obtaining clearance from Institutional Ethics Committee and written informed consent from the study participants. The participants were randomly divided into two groups.

### **2. Materials and methods**

All patients received USG ISB. Group RA received 10 ml of 0.75% ropivacaine with 0.5 ml normal saline. Group RD received 10 ml of 0.75% ropivacaine with 50 µg dexmedetomidine. The onset and duration of sensory and motor blocks and postoperative analgesic effects were noted.

### **3. Results**

Demographic data were comparable for both groups. The onset of sensory and motor blocks was faster and statistically significant in Group RD ( $P < 0.05$ ). It was observed that the duration of block in group RD was prolonged, which was statistically significant ( $P < 0.05$ ). The duration of postoperative analgesia was longer in group RD, which was statistically significant ( $P < 0.05$ ). No complications or side effects were observed in both groups.

### **4. Conclusion**

This study concluded that the onset and duration of sensory and motor blockade was faster. The duration of post analgesia was longer with the addition of dexmedetomidine to ropivacaine in USG ISB with no significant difference in postoperative complications. Hence, it can be concluded that dexmedetomidine can be added to ropivacaine while performing USG ISB in upper limb orthopedic surgeries.

### **1. Introduction**

Interscalene nerve block is widely used in shoulder and lateral end clavicle surgeries and for postoperative pain management in total shoulder arthroplasty. However, ulnar nerve (C8-T1) is not included in the interscalene block (ISB), which encloses the majority of the brachial plexus. Under sterile settings, the interscalene space is identified using either the landmark technique or ultrasound visualization. Local anesthetics such as bupivacaine and ropivacaine are frequently employed [1]. This block can be executed by either peripheral nerve locator or ultrasound guidance. While nerve localization techniques such as paresthesia and nerve stimulation are beneficial for establishing a needle's proximity to a nerve or nerves, they do not specify the needle's exact path of penetration when puncturing the skin. Trial-and-error needle efforts can be time-consuming and stressful for anesthesiologists, and they might hurt the patient and lead to complications. The results of brachial plexus blocks guided by ultrasound are promising and imply that ultrasonic imaging can help with nerve location and direct needle placement [2]. As C-5 and C-6 are nerve roots, which are positioned in the groove in between ASM and MSM, they are the target of the traditional ultrasound-guided (USG) ISB, which is executed at about the cricoid cartilage level [3]. Ropivacaine, a more recent local anesthetic, is an enantiomer of bupivacaine with fewer neurotoxic and cardiac side effects. When compared with bupivacaine, it generates more potent analgesia with less motor blockage, making it the better choice for early mobilization [4, 5].

The idea of extending the analgesic effects of local anesthetic drugs has gained popularity in recent times. It is stated that on incorporation of adjuvants in local anesthetics, the block quality improves and the duration of analgesia is prolonged. These adjuvants include epinephrine, dexamethasone, narcotics, and alpha adrenoreceptor agonist (clonidine and dexmedetomidine) [6, 7]. With no negative side effects, combining ropivacaine and dexmedetomidine in an ISB results in earlier onset, longer duration, and superior patient satisfaction scores [8]. However, there are few reports on the effects of the use of ropivacaine with dexmedetomidine in USG ISB in upper limb orthopedic surgeries. Therefore, this study was performed to evaluate the effect of the use of a combination of ropivacaine and dexmedetomidine for USG ISB in upper limb orthopedic surgeries in the local population.

### **Aims and objectives**

In this study, we compared the efficacy of dexmedetomidine as an adjuvant to ropivacaine versus the use of ropivacaine alone in USG ISB in terms of:

1. The onset and duration of sensory and motor blocks
2. Postoperative analgesia
3. Complications

### **2. Methods**

Following the permission granted by the Institutional Ethics Committee, this study, a randomized control trial, was conducted at a tertiary care hospital. This study included patients aged 18–70 years scheduled for upper limb orthopedic surgeries, who met the inclusion criteria of American Society of Anesthesiologists (ASA) group I-II and had a body mass index (BMI) of  $<30 \text{ kg/m}^2$ . Patients who were allergic to study drugs, pregnant, unwilling to participate in the study, or on beta blockers and those who had neurological deficits on the operating arm were excluded. After obtaining written informed consent, a thorough preanesthetic checkup was done, and the patients were introduced to and informed about Visual Analogue Scale (VAS) as a tool. The participants were divided into two groups by randomization, using the computer-generated software RALLOC by Minitab Corporation 18: Group RD (n = 32) Study Group: 10 ml of 0.75% ropivacaine with 50  $\mu\text{g}$  of dexmedetomidine, and Group RA (n = 32) Control Group: 10 ml of 0.75% ropivacaine with 0.5 ml of normal saline.

Following surgery, the block's quality and duration as well as the postoperative hemodynamics were observed by a different individual than the one who made the drug solution. As per ASA fasting standards, all participants were kept on a nil by mouth and were given 4 mg of Ondansetron injection prior to the surgery. After gaining intravenous access with a 20-gauge intravenous cannula, infusion of 500 ml of Ringer's lactate solution was started. The heart rate (HR), the respiratory rate (RR), oxygen saturation ( $\text{SpO}_2$ ), systolic blood pressure, diastolic blood pressure, and the mean arterial pressure (MAP) were monitored. After positioning the patient with the head rotated to the other side, an ISB was administered under USG, and anesthetic drug was given in accordance to that allocated to the group. The time of completion of injection of the local anesthetic was labeled as 0 minutes. Following the administration of the local anesthetic, intraoperative hemodynamic parameters were checked every 10 minutes for 1 hour and then every 20 minutes until the operation was complete. If intraoperative pain was observed, patient was given a supplement of injection of 1  $\mu\text{g}$  of fentanyl per kg boluses. The onset of sensory block by pinprick, the onset of motor block by Bromage scale, and the duration of sensory and motor blocks parameters were assessed.

The time at which first rescue analgesia was given was noted. The patients were administered rescue analgesia in the form of 1 gm of Paracetamol IV injection infusion whenever they complained of pain or requested for analgesia or reported VAS  $\geq 4$ . Tramadol injection of 100 mg was given as a second rescue analgesia. The participants were kept in the Post Anesthesia Care Unit for further observation for the next 24 hours. Hemodynamic parameters were assessed serially at 1, 2, 3, 4, 5, 6, 8, 12, and 24 hr after surgery. The occurrence of any side effects or complications was noted.

### 3. Statistical methods

Using the variables from a previous published paper by Rashmi et al. [8], the sample size was calculated, which came to be 32 participants per group. With the help of the Chi-Square test or Fisher's exact probability test for a  $2 \times 2$  contingency table, it was determined whether there was a significant difference in the distribution of categorical data between the two research groups. The statistical significance of the variation in the averaged continuous data seen between two research groups was analyzed using an independent sample t test. P values of 0.05 or less were regarded as statistically significant. Statistical Package for Social Sciences (SPSS ver 22.0, IBM Corporation) for MS Windows was used to statistically analyze all of the data.

### 4. Results

A total of 64 participants who met the ASA 1 and 2 status inclusion criteria were included in this study. As shown in Table 1, the demographic characteristics were comparable in both groups.

Variables	Group RA	Group RD
Age (years)	42.63 $\pm$ 14.54	<b>38.59<math>\pm</math>14.56</b>
Gender (%)		
Male	50	75
Female	50	25
Body mass index	22.3 $\pm$ 2.99	21.63 $\pm$ 2.01

Table 1: Demographic characteristics of the study participants.

As shown in Table 2, the distribution of the mean onset of sensory block was significantly higher in Group RA compared with Group RD (P value < 0.05), while the distribution of the mean onset of motor block was significantly higher in Group RA compared with Group RD (P value < 0.05). The distribution of mean duration of sensory block was significantly higher in Group RD compared with Group RA (P value < 0.05), while the distribution of the mean duration of motor block was significantly higher in Group RD compared with Group RA (P value < 0.05). The distribution of mean time for first rescue analgesia was significantly higher in Group RD compared with Group RA (P value < 0.05). The distribution of mean total analgesia required in 24 hours was significantly higher in Group RA compared with Group RD (P value < 0.05).

Onset (Min)	Group RD (n = 32)		Group RA (n = 32)		P value
	Mean	SD	Mean	SD	
Sensory block	2.19	0.74	6.17	0.96	0.001*

Motor block	4.47	1.11	8.63	0.82	0.001*
<b>Duration (Min)</b>					
Sensory block	708.91	41.50	529.79	20.82	0.001*
Motor block	642.34	46.32	456.67	18.45	0.001*
<b>Time for first rescue analgesia (Min)</b>	856.09	58.35	588.13	20.47	0.001*
<b>Total analgesia required in 24 hours</b>	1.00	0.00	1.29	0.46	0.001*
*statistically significant SD: standard deviation					

Table 2: Onset and duration of sensory block and motor block, time for first rescue analgesia, and total analgesic requirement.

The hemodynamic parameters were measured. As shown in Figure 1, the distribution of mean MAP at 0 min, 10 min, 20 min, and 30 min did not differ significantly in the two study groups (P value > 0.05 for all). The distribution of mean MAP at 40 min, 50 min, 1 hr, 1 hr 20 min, 1 hr 40 min, and 2 hr was significantly higher in Group RA compared with Group RD (P value < 0.05 for all).

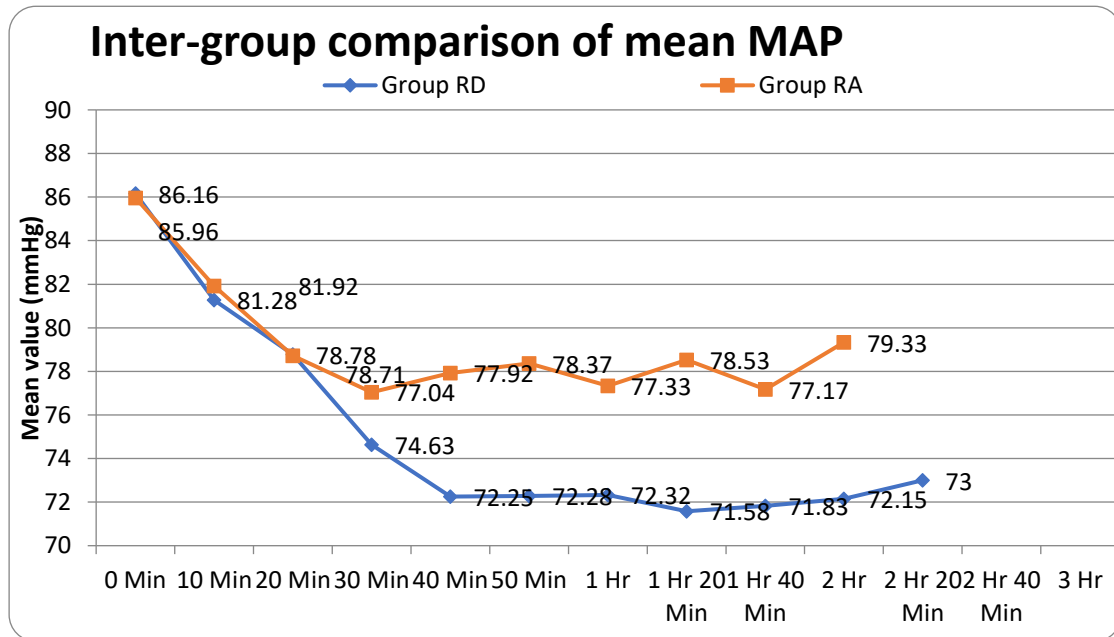


Figure 1: The mean MAP comparison between two groups.

As shown in Figure 2, the distribution of mean MAP at 1 hr postoperatively was significantly higher in Group RA compared with Group RD (P value < 0.05 for all). The distribution of mean MAP at 2 hr, 3 hr, 4 hr, 5 hr, 6 hr, 12 hr, and 24 hr did not differ significantly in the two study groups (P value > 0.05 for all).

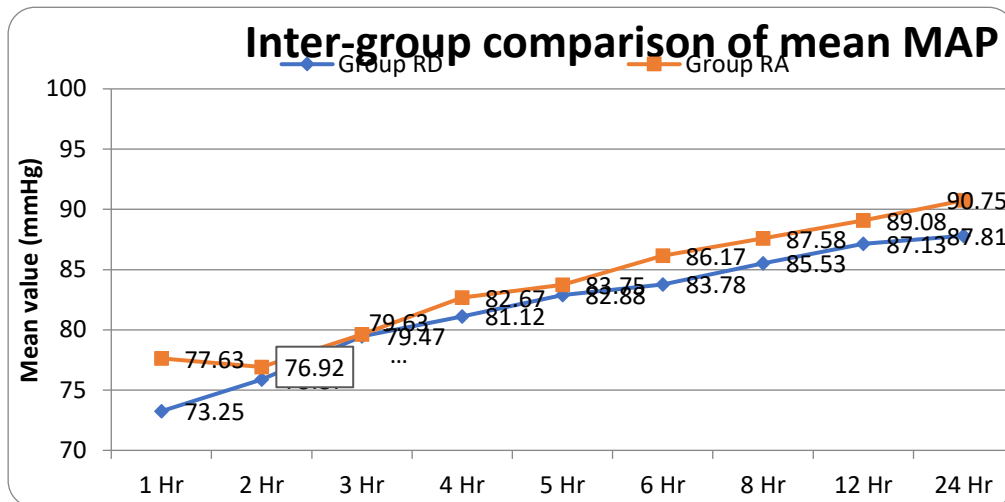


Figure 2: Mean MAP comparison postoperatively.

HR, RR, and SpO<sub>2</sub> were comparable at all times intraoperatively and postoperatively, but the difference was statistically insignificant. None of the patients belonging to either group had any side effects or complications.

## 5. Discussion

There is enhanced understanding that regional anesthesia might offer improvement in pain control and possibly improve patient outcomes. To satisfy the developing expectations of ambulatory, cost-effective procedures, there has been an ever-increasing demand for regional anesthesia from patients and doctors. Regional anesthesia has many advantages over general anesthesia, including decreased rates of major complications, greater postoperative analgesia, economic effectiveness, and reduced death and morbidity [9].

The interscalene brachial plexus block is a well-known and highly effective anesthetic technique. Ropivacaine is a long-acting regional anesthetic drug belonging to the amino amide group and is structurally related to bupivacaine. It is a pure (S)-enantiomer, unlike bupivacaine, which is a racemate, developed for the purpose of reducing potential toxicity and improving relative sensory and motor block profiles [4]. Zhai et al. [10] determined that using 50 mg of ropivacaine in 0.25%, 0.5%, or 0.75% solutions to block the interscalene brachial plexus before arthroscopic shoulder surgery results in a similar blockade with few side effects, while 0.75% solution is preferred due to its quicker onset time. Dexmedetomidine has a unique mechanism of action. It acts on alpha-2 adrenoceptors in the locus coeruleus [11]. Masuki et al. [12] suggested that dexmedetomidine induces vasoconstriction via  $\alpha_2$  adrenoceptors in the human forearm, possibly also causing vasoconstriction around the site of injection, delaying the absorption of the local anesthetic and hence prolonging its effect.

Rashmi et al. [8] studied the effect of the addition of dexmedetomidine to 30 ml of 0.75% ropivacaine and 30 ml of 0.75% ropivacaine alone by using the peripheral nerve stimulator. They found that the onset of motor and sensory block was longer in ropivacaine alone than on the addition of dexmedetomidine to ropivacaine, which was statistically significant ( $P < 0.05$ ). In this study, the onset of sensory and motor block was faster than the results of Rashmi et al.'s study as USG block was used, thus requiring a lesser volume of drug of 10 ml. Another study by Esmaglu et al. [13] assessed the effect of the addition of dexmedetomidine (100  $\mu$ g) to levobupivacaine in axillary brachial plexus block. It was a randomized control trial that

concluded that the addition of dexmedetomidine to levobupivacaine provided a faster onset of sensory and motor block. It was statistically significant ( $P < 0.005$ ). Their study showed higher incidence of bradycardia, attributed to a higher dose of dexmedetomidine. In this study, a lower dose of dexmedetomidine (50  $\mu\text{g}$ ) was used as the previous study indicated the occurrence of bradycardia due to high dose. Bradycardia was not reported in this study.

Marhofer et al. [14] carried out their study using 3 ml of ropivacaine (0.75%) (R), 3 ml of ropivacaine (0.75%) + 20  $\mu\text{g}$  of dexmedetomidine (RpD), or 3 ml of ropivacaine (0.75%) plus systemic 20 mg of dexmedetomidine (RsD) in USG ulnar nerve block (UNB). The sensory and motor scores related to UNB were assessed. They found out that the duration of sensory and motor block was longer with the addition of dexmedetomidine. Das et al. [15] studied the effect of the addition of dexmedetomidine to 0.5% ropivacaine in peripheral nerve stimulator-guided supraclavicular block. They found that the time for first rescue analgesia was more in the dexmedetomidine group. In their study, no effect was observed on the onset of block. In their study, as 0.75% ropivacaine was used there was prolonged duration of sensory and motor block compared with this study. And as a result, less volume was needed because of high concentration of drug and ultrasound guidance. In this study, the onset of sensory and motor block was faster.

However, phrenic nerve palsy is a complication of ISB. But with reduced volume and ultrasound usage, this complication has been reduced. In their study, Renes et al. [16] concluded that USG ISB at the level of root C7 using 10 mL of ropivacaine 0.75% leads to a significant reduction in the incidence of hemidiaphragmatic paresis. Phrenic nerve palsy was not studied in the patients in this study because of the nonavailability of equipment in the institute, which is a shortcoming. Therefore, further studies on evaluation of phrenic nerve palsy are required.

### **Limitations**

The incidence of phrenic nerve palsy, which is the most common complication of ISB as C ARM, was not studied as it was not accessible.

### **Conclusion**

This study concluded that the onset and duration of sensory and motor blockade was faster, and the duration of post analgesia was longer with the addition of dexmedetomidine to ropivacaine in USG ISB with no significant difference between postoperative complications. In addition, the total volume required of ropivacaine was lesser as compared with that in peripheral nerve stimulator-guided or landmark-guided techniques. Therefore, dexmedetomidine can be added to ropivacaine while performing USG ISB in upper limb orthopedic surgeries.

## **6. References**

1. Zisquit J, Nedeff N: Interscalene Block. StatPearls Publishing, Treasure Island (FL); 2019.
2. Chan VW: Applying ultrasound imaging to interscalene brachial plexus block. Reg Anesth Pain Med. 2003, 28:340–3.
3. Laurent DB, Chan V, Chin KJ: Refining the ultrasound-guided interscalene brachial plexus block: The superior trunk approach. Can J Anesth. 2014, 61:1098–102.
4. Kuthiala G, Chaudhary G: Ropivacaine: A review of its pharmacology and clinical use. Indian J Anaesth. 2011, 55:104.
5. Greengrass RA, Klein SM, D'Ercole FJ, Gleason DG, Shimer CL, and Steele SM:

- Lumbar plexus and sciatic nerve block for knee arthroplasty: Comparison of ropivacaine and bupivacaine. *Can J Anaesth.* 1998, 45:1094.
6. Abdallah FW, Brull R: Facilitatory effects of perineural dexmedetomidine on neuraxial and peripheral nerve block: A systematic review and meta-analysis. *Br J Anaesth.* 2013, 110:915–25.
  7. Swami SS, Keniya VM, Ladi SD, Rao R: Comparison of dexmedetomidine and clonidine ( $\alpha_2$  agonist drugs) as an adjuvant to local anaesthesia in supraclavicular brachial plexus block: A randomised double-blind prospective study. *Indian J Anaesth.* 2012, 56:243.
  8. Rashmi HD, Komala HK: Effect of dexmedetomidine as an adjuvant to 0.75% ropivacaine in interscalene brachial plexus block using nerve stimulator: A prospective, randomized double-blind study. *Anesth Essays Res.* 2017, 11(1):134.
  9. Salem MH: Interscalene block: a comparison between electrostimulation and ultrasound-guided techniques (Doctoral dissertation, Universität Ulm).
  10. Zhai W, Wang X, Rong Y, and Li M, Wang H: Effects of a fixed low-dose ropivacaine with different volume and concentrations on interscalene brachial plexus block: A randomized controlled trial. *BMC Anesthesiol.* 2015, 16:1–8.
  11. Giovannitti Jr JA, Thoms SM, and Crawford JJ: Alpha-2 adrenergic receptor agonists: a review of current clinical applications. *Anesth Prog.* 2015, 62:31–8.
  12. Masuki S, Dinunno FA, Joyner MJ, Eisenach JH: Selective  $\alpha_2$ -adrenergic properties of dexmedetomidine over clonidine in the human forearm. *J Appl Physiol.* 2005, 99:587–92.
  13. Esmaoglu A, Yegenoglu F, Akin A, Turk CY: Dexmedetomidine added to levobupivacaine prolongs axillary brachial plexus block. *Anesth Analg.* 2010, 111:1548–51.
  14. Marhofer D, Kettner SC, Marhofer P, Pils S, and Weber M, Zeitlinger M: Dexmedetomidine as an adjuvant to ropivacaine prolongs peripheral nerve block: a volunteer study. *Br J Anaesth.* 2013, 110:438–42.
  15. Das A, Majumdar S, Halder S, Chattopadhyay S, Pal S, Kundu R, and Mandal SK, Chattopadhyay S: Effect of dexmedetomidine as adjuvant in ropivacaine-induced supraclavicular brachial plexus block: A prospective, double-blinded and randomized controlled study. *Saudi J Anaesth.* 2014, 8:S72.
  16. Renes SH, Rettig HC, Gielen MJ, and Wilder-Smith OH, van Geffen GJ: Ultrasound-guided low-dose interscalene brachial plexus block reduces the incidence of hemidiaphragmatic paresis. *Reg Anesth Pain Med.* 2009, 34:498–502.