



## Toxicological studies on *Acanthus montanus* leaf extracts in male and female albino rats

Iwueke, Adaku. V.<sup>1</sup>, Chukwu, Ezinne. C.<sup>2\*</sup>, Onuoha, Obinna. U.<sup>3</sup> and Osuocha K.U.<sup>4</sup>

<sup>1</sup>Department of Biochemistry, PAMO University of Medical Sciences, Port-Harcourt Rivers State, Nigeria. E-mail: drvivien.89@gmail.com

<sup>2</sup>Department of Biochemistry, Federal University of Lafia, Nasarawa State, Nigeria. E-mail: chukwuezinne@gmail.com

<sup>3</sup>Department of Biochemistry, Michael Okpara University of Agriculture, Umudike, Nigeria. E-mail: dominusonuha@gmail.com

<sup>4</sup>Biochemistry Unit, Department of Science Laboratory Technology, Federal University of Lafia, Nasarawa State, Nigeria. E-mail: osuochak@gmail.com

### Article Info

Volume 3, Issue 1, January 2021

Received : 15 October 2019

Accepted : 14 April 2020

Published : 01 January 2021

doi: [10.33472/AFJBS.3.1.2021.34-51](https://doi.org/10.33472/AFJBS.3.1.2021.34-51)

### Abstract

Leaves of *Acanthus montanus* have been used traditionally in treatment of several diseases such as skin diseases. This work was designed to evaluate toxicological impact of *A. montanus* extracts in male and female albino rats. Ninety (90) albino rats of 45 male and 45 female rats were used for the study, divided into 18 groups of five rats. Alphabets and figures were used to identify the male and female rats. Groups A and 1 received normal rat chow, Groups B and 2, C and 3, D and 4, E and 5 received 200, 400, 600 and 800 mg/kg of aqueous extract of *A. montanus* leaves while groups F and 6, G and 7, H and 8, I and 9 received 200, 400, 600 and 800 mg/kg of methanol extract of *A. montanus*. Liver enzyme assays showed a dose dependent significant increase in the test groups while total protein and albumin showed significant decrease in the test groups. Total and direct bilirubin did not show significant difference in test groups compare to control. Creatinine level showed significant increase ( $p \leq 0.05$ ) in test groups while urea decreased in test groups. The histo architecture of liver and kidney, showed moderate to widespread impairments in the groups exposed to 800 mg/kg of aqueous extract, 400, 600 and 800 mg/kg of methanol extract. *A. montanus* leaves may exhibit renal and hepatic impairment with increased dosage; hence should be detoxified before usage.

**Keywords:** *Acanthus, Montanus, Toxicological, Albino rats*

© 2021 African Journal of Biological Sciences. This is an open access article under the CC BY license (<https://creativecommons.org/licenses/by/4.0/>), which permits unrestricted use, distribution, and reproduction in any medium, provided you give appropriate credit to the original author(s) and the source, provide a link to the Creative Commons license, and indicate if changes were made.

### 1. Introduction

Medicinal plants have been used in folk medicine for generations in most of the cultures throughout the world and are still one of the primary sources of treatment in many areas today. In Nigeria and most developing countries of the world, plant based traditional medicine system play essential role in health care with about 80% of the population relying on it due to its availability and cheap source (Owolabi et al., 2007). These medicinal plants have always been among the common sources of medicine either processed as traditional preparations or used to extract bioactive compounds that might serve as lead for the development of novel

\* Corresponding author: Chukwu, Ezinne. C, Department of Biochemistry, Federal University of Lafia, Nasarawa State, Nigeria. E-mail: [chukwuezinne@gmail.com](mailto:chukwuezinne@gmail.com)

drugs (Sakpa and UcheNwachi, 2014; and Salah et al., 2015). *Acanthus montanus* (Nees) T. Anders is a small stinging shrub belonging to the family of *Acanthaceae* and growing wild in grassland woods and rocky hills. It exists in Africa, the Balkans, Romania, Greece and Eastern Mediterranean (Okoli et al., 2008). It has been reported to be effective in the treatment of urogenital infections, urethral pain, endometritis, urinary disease, cystitis, leucorrhoea, aches and pains (Okoli et al., 2008). *A. montanus* leaves have been shown to display analgesic, anti-inflammatory and antipyretic activities (Adeyemi et al., 1999; 2004; Asongalem et al., 2004; and Okoli et al., 2008). Based on the reputed medicinal efficacy of this plant, there is need to ascertain the possible biochemical and toxicological changes that may accompany its usage.

## 2. Materials and methods

Fresh leaves of *A. montanus* were obtained from Umuoda Amuzu in Aboh Mbaise L.G.A of Imo state. They were identified by Professor G. G. E. Osuagwu of the Department of Plant Science and Biotechnology, Michael Okpara University of Agriculture, Umudike. The leaves were washed with tap water and spread on the laboratory bench to air dry. The dried leaves were ground to fine powder. A quantity was separately soaked in 500 ml of water and methanol respectively for 48 h. Each extraction mixture was filtered using whatman No4 filter paper and concentrated by evaporation to dryness forming the residue.

## 3. Experimental design

Ninety (90) albino rats consisting of 45 male and 45 female rats, aged about nine weeks and weighing between 116-122 g, were used for the study. The rats were purchased from the Animal house, Department of Pharmacology, University of Nigeria Nsukka. Alphabets were used to represent the male rats while the female rats were represented numerically. Members of each group of animals were housed in a steel cage and allowed to acclimatize to laboratory condition for one week prior to commencement of feeding experiments. Male and female rats groups A and 1 received normal rat chow and groups B and 2, C and 3, D and 4, E and 5 received 200, 400, 600 and 800 mg/kg of aqueous extract of *A. montanus* leaves while groups F and 6, G and 7, H and 8, I and 9 received 200, 400, 600 and 800 mg/kg of methanol extract of *A. montanus*. All rats were allowed free access to water and feed *ad libitum*. The extracts were administered orally for 28 days and the animals were fasted overnight, anaesthetized with methyl chloroform and sacrificed. The treatment of experimental animals was in accordance to the National Institute of Health (NIH) guidelines for the care and use of laboratory animals (NIH, 1985). Blood was collected by cardiac puncture into anticoagulant free tubes with corks for biochemical parameters test while that of hematology was collected in anticoagulant tubes.

## 4. Assessment of liver integrity status

Alkaline phosphatase (ALP) activity was determined by the method described by Bessey et al., (1946) using commercial diagnostic kit (Randox, United Kingdom), Serum alanin aminotransferase (ALT) and serum aspartate aminotransferase (AST) activity was determined according to the method of Reitman and Frankel (1957). Serum total protein was determined by the method described by Henry et al. (1974). Albumin concentration was determined by the method of Bromocresol Green (BCG) as described by Doumas et al. (1971). Colorimetric method described by Jendrassik and Grof (1938) was used for determination of serum total and conjugated bilirubin concentration.

### 4.1. Renal function assessment

Colorimetric method of Taursky (1956) was used for creatinine determination while urea level was determined with urease - Earthebt colorimetric method of Weatherburn (1967).

### 4.2. Histological studies

The method of Baker and Silverton (1985) was adopted in the preparation of slices of previously fixed tissues (liver and kidney) for histological examination

## 5. Statistical analysis

Statistical analysis of the results were done using Students Package for Social Sciences (SPSS) version 20 computer software and data collected was analyzed using Analysis of Variance (ANOVA). Means were separated using one-way ANOVA.

	ALP (U/L)	ALT (U/L)	AST (U/L)	T/P (g/dl)	AB (g/dl)	T/B (mg/dl)	D/B (mg/dl)
Group A	4.02 ± 0.06 <sup>a</sup>	5.02 ± 0.02 <sup>b</sup>	16.40 ± 0.03 <sup>a</sup>	7.28 ± 0.03 <sup>f</sup>	4.81 ± 0.02 <sup>h</sup>	1.07 ± 0.02 <sup>ab</sup>	0.31 ± 0.02 <sup>bc</sup>
Group B	4.69 ± 0.02 <sup>b</sup>	4.32 ± 0.03 <sup>a</sup>	16.93 ± 0.03 <sup>b</sup>	7.30 ± 0.02 <sup>f</sup>	4.84 ± 0.02 <sup>h</sup>	1.22 ± 0.02 <sup>bc</sup>	0.30 ± 0.02 <sup>bc</sup>
Group C	5.12 ± 0.03 <sup>c</sup>	5.38 ± 0.02 <sup>c</sup>	18.12 ± 0.03 <sup>d</sup>	6.98 ± 0.03 <sup>e</sup>	4.71 ± 0.03 <sup>g</sup>	0.98 ± 0.44 <sup>a</sup>	0.34 ± 0.02 <sup>bc</sup>
Group D	5.63 ± 0.03 <sup>d</sup>	5.69 ± 0.02 <sup>d</sup>	17.72 ± 0.02 <sup>c</sup>	6.72 ± 0.02 <sup>d</sup>	4.55 ± 0.04 <sup>f</sup>	1.36 ± 0.23 <sup>cd</sup>	0.18 ± 0.02 <sup>ab</sup>
Group E	6.23 ± 0.02 <sup>e</sup>	6.24 ± 0.43 <sup>e</sup>	19.98 ± 0.06 <sup>f</sup>	6.31 ± 0.08 <sup>c</sup>	4.01 ± 0.02 <sup>d</sup>	1.38 ± 0.03 <sup>cd</sup>	0.12 ± 0.02 <sup>ab</sup>
Group F	6.80 ± 0.04 <sup>f</sup>	5.76 ± 0.03 <sup>d</sup>	18.67 ± 0.06 <sup>e</sup>	6.86 ± 0.05 <sup>de</sup>	4.22 ± 0.04 <sup>e</sup>	1.43 ± 0.04 <sup>cde</sup>	0.19 ± 0.02 <sup>ab</sup>
Group G	8.02 ± 0.03 <sup>g</sup>	7.01 ± 0.02 <sup>f</sup>	22.49 ± 0.04 <sup>g</sup>	6.44 ± 0.53 <sup>c</sup>	3.91 ± 0.03 <sup>c</sup>	1.51 ± 0.04 <sup>de</sup>	0.10 ± 0.03 <sup>ab</sup>
Group H	8.39 ± 0.03 <sup>h</sup>	7.88 ± 0.16 <sup>g</sup>	26.04 ± 0.71 <sup>h</sup>	5.73 ± 0.05 <sup>b</sup>	3.82 ± 0.04 <sup>b</sup>	1.55 ± 0.04 <sup>de</sup>	0.44 ± 0.52 <sup>c</sup>
Group I	8.98 ± 0.04 <sup>i</sup>	9.28 ± 0.04 <sup>h</sup>	32.16 ± 0.11 <sup>i</sup>	4.98 ± 0.06 <sup>a</sup>	3.23 ± 0.04 <sup>a</sup>	1.63 ± 0.04 <sup>e</sup>	0.03 ± 0.02 <sup>a</sup>

**Note:** Results represent mean ± standard deviation ( $n = 5$ ). Different superscripts represent significant difference at 90% confidence level. Values in the same column having the same superscript are not significantly ( $p < 0.05$ ) different.

	ALP (U/L)	ALT (U/L)	AST (U/L)	T/P (g/dl)	AB (g/dl)	T/B (mg/dl)	D/B (mg/dl)
Group 1	3.76 ± 0.02 <sup>a</sup>	5.76 ± 0.05 <sup>a</sup>	13.09 ± 4.50 <sup>a</sup>	6.92 ± 0.04 <sup>f</sup>	4.09 ± 0.18 <sup>c</sup>	0.88 ± 0.06 <sup>a</sup>	0.28 ± 0.06 <sup>ab</sup>
Group 2	4.20 ± 0.04 <sup>b</sup>	6.01 ± 0.04 <sup>b</sup>	18.00 ± 0.07 <sup>b</sup>	6.92 ± 0.04 <sup>f</sup>	3.90 ± 0.08 <sup>bc</sup>	0.88 ± 0.02 <sup>a</sup>	0.27 ± 0.05 <sup>ab</sup>
Group 3	4.74 ± 0.02 <sup>c</sup>	6.40 ± 0.03 <sup>c</sup>	17.69 ± 0.02 <sup>b</sup>	6.88 ± 0.04 <sup>ef</sup>	3.92 ± 0.03 <sup>bc</sup>	0.95 ± 0.04 <sup>a</sup>	0.36 ± 0.03 <sup>ab</sup>
Group 4	5.88 ± 0.03 <sup>d</sup>	6.38 ± 0.02 <sup>c</sup>	19.03 ± 0.02 <sup>bc</sup>	6.75 ± 0.04 <sup>c</sup>	3.84 ± 0.03 <sup>bc</sup>	1.09 ± 0.03 <sup>b</sup>	0.22 ± 0.03 <sup>ab</sup>
Group 5	6.16 ± 0.02 <sup>e</sup>	7.12 ± 0.04 <sup>d</sup>	20.14 ± 0.03 <sup>c</sup>	6.68 ± 0.06 <sup>b</sup>	3.43 ± 0.03 <sup>a</sup>	1.21 ± 0.02 <sup>c</sup>	0.18 ± 0.04 <sup>a</sup>
Group 6	6.87 ± 0.02 <sup>f</sup>	8.02 ± 0.02 <sup>e</sup>	18.72 ± 0.02 <sup>bc</sup>	6.79 ± 0.07 <sup>cd</sup>	3.73 ± 0.03 <sup>b</sup>	1.10 ± 0.06 <sup>b</sup>	0.23 ± 0.02 <sup>ab</sup>
Group 7	7.02 ± 0.10 <sup>g</sup>	8.32 ± 0.03 <sup>f</sup>	24.48 ± 0.45 <sup>d</sup>	6.83 ± 0.06 <sup>de</sup>	3.80 ± 0.03 <sup>b</sup>	1.28 ± 0.06 <sup>c</sup>	0.18 ± 0.02 <sup>a</sup>
Group 8	7.24 ± 0.03 <sup>h</sup>	8.49 ± 0.03 <sup>g</sup>	28.42 ± 0.03 <sup>e</sup>	6.62 ± 0.06 <sup>b</sup>	3.23 ± 0.03 <sup>a</sup>	1.40 ± 0.16 <sup>d</sup>	0.13 ± 0.03 <sup>a</sup>
Group 9	7.88 ± 0.04 <sup>i</sup>	9.89 ± 0.06 <sup>h</sup>	29.67 ± 0.06 <sup>e</sup>	6.45 ± 0.04 <sup>a</sup>	3.44 ± 0.52 <sup>a</sup>	1.58 ± 0.06 <sup>e</sup>	0.47 ± 0.54 <sup>b</sup>

**Note:** Results represent mean ± standard deviation ( $n = 5$ ). Different superscripts represent significant difference at 90% confidence level; Values in the same column having the same superscript are not significantly ( $p < 0.05$ ) different.

## 6. Histological evaluation of the male albino rats hepatocytes

Sections of the liver from the animals in this group showed the normal histo-architecture of the mammalian liver. Normal hepatic sinusoids consisting of normal hepatocytes were observed. The hepatocytes were arranged in interconnecting chords (arrow) around the central vein (C), radiating towards the periphery of the sinusoids to the portal areas (P) which showed normal structures of the portal triad (hepatic artery, hepatic vein and bile duct). H&E × 100.

Just as observed in the control group, sections of the liver from the animals in this group showed the normal histo-architecture of the mammalian liver. Normal hepatic sinusoids consisting of normal hepatocytes were observed. The hepatocytes were arranged in interconnecting chords (arrow) around the central vein (C), radiating towards the periphery of the sinusoids to the portal areas which showed normal structures of the portal triad (hepatic artery, hepatic vein and bile duct). H&E × 100.

<b>Table 3: Renal function assessment of male albino rats</b>		
	<b>Creatinine (mg/dl)</b>	<b>Urea (mg/dl)</b>
Group A	0.90 ± 0.08 <sup>c</sup>	34.00 ± 3.16 <sup>f</sup>
Group B	0.69 ± 0.08 <sup>a</sup>	38.00 ± 1.58 <sup>f</sup>
Group C	0.78 ± 0.02 <sup>b</sup>	36.00 ± 2.24 <sup>f</sup>
Group D	1.12 ± 0.10 <sup>d</sup>	30.00 ± 1.58 <sup>e</sup>
Group E	1.19 ± 0.07 <sup>d</sup>	27.00 ± 2.23 <sup>cd</sup>
Group F	1.16 ± 0.29 <sup>d</sup>	29.00 ± 2.55 <sup>de</sup>
Group G	1.27 ± 0.05 <sup>e</sup>	26.00 ± 2.24 <sup>c</sup>
Group H	1.35 ± 0.03 <sup>f</sup>	20.00 ± 1.58 <sup>b</sup>
Group I	1.48 ± 0.03 <sup>f</sup>	14.40 ± 1.67 <sup>a</sup>

**Note:** Results represent mean ± standard deviation ( $n = 5$ ); Different superscripts represent significant difference at 90% confidence level; and Values in the same column having the same superscript are not significantly ( $p < 0.05$ ) different.

<b>Table 4: Renal function assessment of female albino rats</b>		
	<b>Creatinine (mg/dl)</b>	<b>Urea (mg/dl)</b>
Group 1	0.78 ± 0.04 <sup>a</sup>	38.20 ± 0.84 <sup>e</sup>
Group 2	0.92 ± 0.03 <sup>c</sup>	34.00 ± 2.55 <sup>d</sup>
Group 3	0.84 ± 0.04 <sup>b</sup>	39.00 ± 2.24 <sup>e</sup>
Group 4	0.92 ± 0.02 <sup>c</sup>	31.80 ± 2.59 <sup>cd</sup>
Group 5	0.99 ± 0.04 <sup>d</sup>	26.00 ± 2.55 <sup>b</sup>
Group 6	0.82 ± 0.02 <sup>a</sup>	31.00 ± 1.58 <sup>c</sup>
Group 7	0.97 ± 0.06 <sup>d</sup>	24.00 ± 2.55 <sup>b</sup>
Group 8	1.19 ± 0.03 <sup>e</sup>	20.60 ± 2.07 <sup>a</sup>
Group 9	1.30 ± 0.02 <sup>f</sup>	18.00 ± 1.58 <sup>a</sup>

**Note:** Results represent mean ± standard deviation ( $n = 5$ ); Different superscripts represent significant difference at 90% confidence level; and Values in the same column having the same superscript are not significantly ( $p < 0.05$ ) different.

Sections of the liver from the animals in this group showed a mild cellular swelling which appears to involve mainly the hepatocytes in the periportal zone (i.e., hepatocytes around the portal areas of the hepatic lobules) while the hepatocytes around the central veins appears relatively normal. The affected hepatocytes appear swollen, showing numerous, tiny, clear spaces in their cytoplasm (white arrow). Compare with normal hepatocytes (black arrow). Hepatic artery (A); Bile duct (B). H&E × 100

Sections of the liver collected from the animals in this group showed a mild vacuolar change in the hepatocytes of all the zones of the hepatic lobule. The hepatocytes appear slightly swollen, with minute, clear, cytoplasmic vacuoles (arrow). The nuclei appear normal. Central vein (V). H&E × 100.

Sections of the liver collected from the animals in this group showed a widespread, moderate vacuolar degeneration of the hepatocytes. The hepatocytes in the hepatic cords are swollen, with a compressing effect on the sinusoidal spaces (arrow), partially occluding the space and contains multiple coalescent clear cytoplasmic vacuoles (black arrow). Portal area [Bile duct (B); Hepatic vein (HV)]; Central vein (V). H&E × 100.



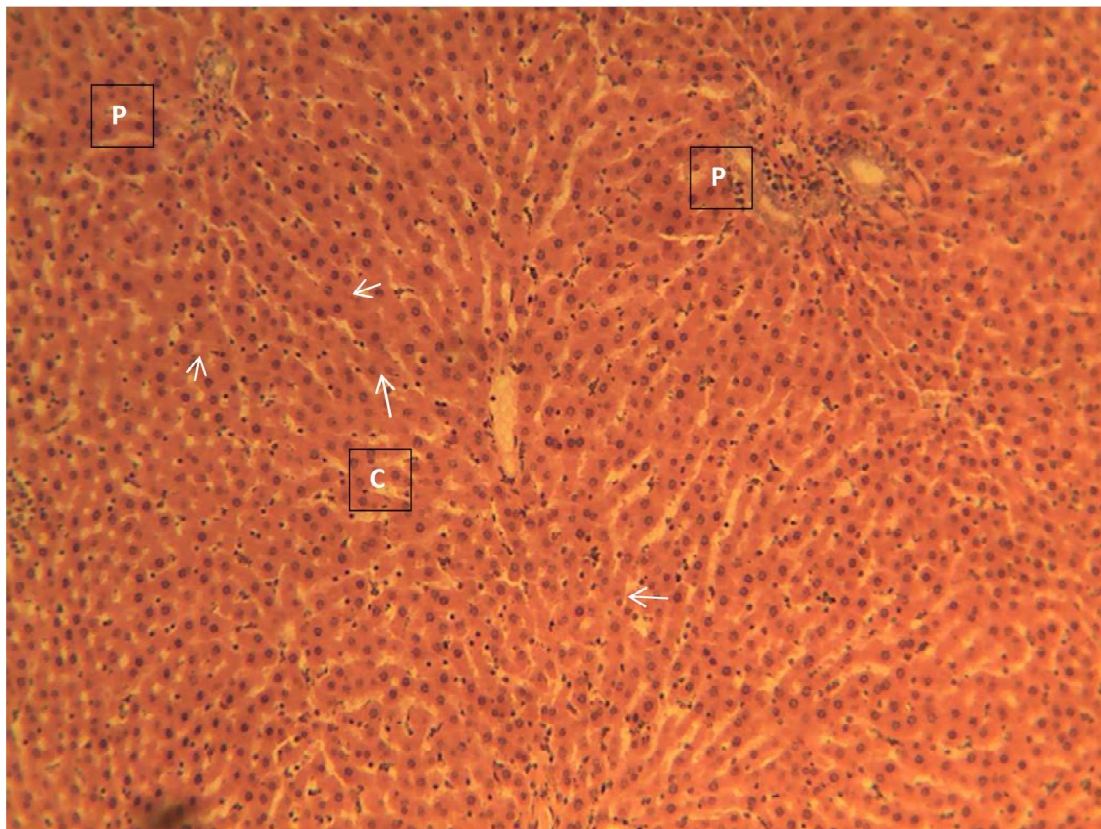


Plate 1: Control group of the male albino rats liver exposed to no extract

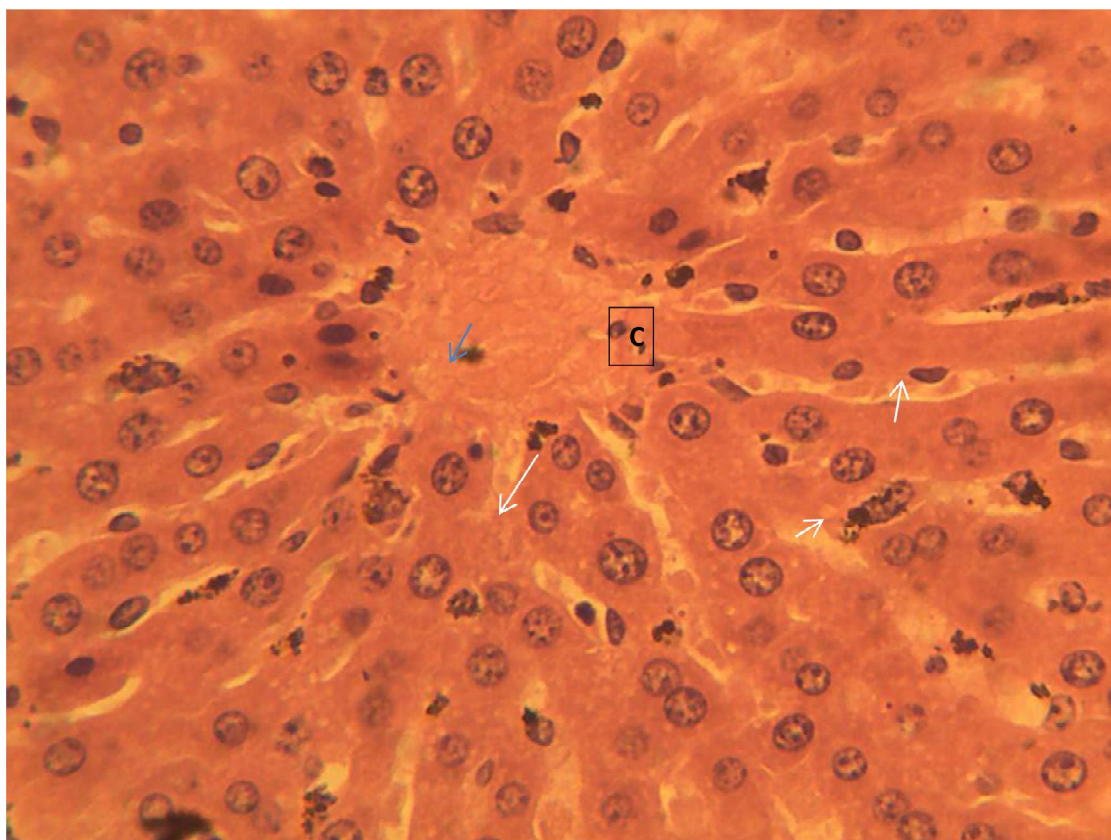


Plate 2: Male liver of the group exposed to 200 mg/kg of aqueous extract

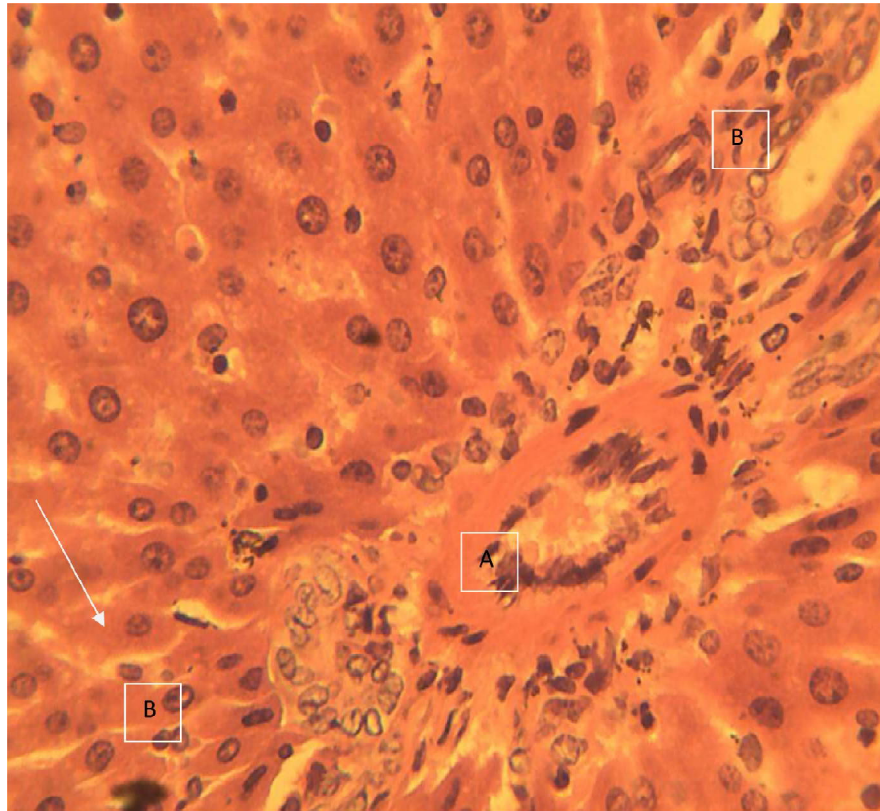


Plate 3: Male albino rats liver of the group exposed to 800 mg/kg of aqueous extract

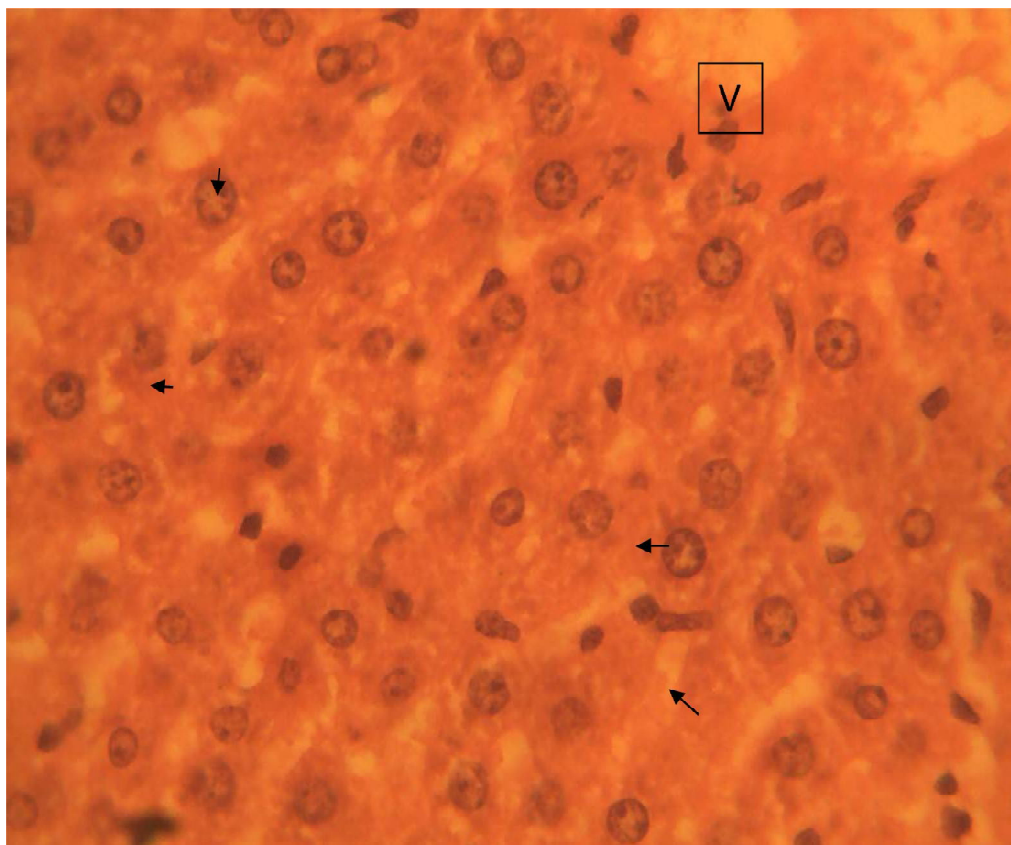



Plate 4: Male liver of the group exposed to 200 mg/kg of methanol extract





### 6.1. Male Kidney

Sections of the kidney collected from the animals in this group showed the normal histo-architecture of the mammalian kidney. Normal components of the cortex and medulla (both outer and inner medulla) were observed. The sections showed normal glomeruli in Bowman's capsules embedded in a sea of normal renal tubules (proximal convoluting tubules, pars recta, distal convoluting tubules and collecting ducts). Glomeruli (G); Bowman's capsule (arrow); Renal tubules (T); Blood vessel (V). H&E  $\times$  100.

Sections of the kidney collected from the animals in this group also showed the normal histo-architecture of the mammalian kidney. Just like in the control, normal components of the cortex and medulla (both outer and inner medulla) were observed. The sections showed normal glomeruli in Bowman's capsules embedded in a sea of normal renal tubules (proximal convoluting tubules, pars recta, distal convoluting tubules and collecting ducts). Glomeruli (G); Renal tubules (T). H&E  $\times$  100.

Sections of the kidney collected from the animals in this group showed a widespread moderate to severe vacuolar degeneration of the epithelial lining cells of the renal tubules (T) in the cortex and outer medulla. The affected tubules show epithelial cells that are variably swollen with numerous clear spaces in their cytoplasm. Some of the affected tubules show shrunken hyperchromatic nuclei (white arrow); compare with normal nuclei (blue arrow). Glomerulus (G); Bowman's capsule (black arrow); blood vessel (BV). H&E  $\times$  100

Sections of the kidney collected from the animals in this group showed the normal histo-architecture of the mammalian kidney. Just like in the control, normal components of the cortex and medulla (both outer and inner medulla) were observed. The sections showed normal glomeruli in Bowman's capsules embedded in a sea of normal renal tubules (proximal convoluting tubules, pars recta, distal convoluting tubules and collecting ducts). Glomeruli (G); Bowman's capsule (arrow); Renal tubules (T). H&E  $\times$  100.

Sections of the kidney collected from the animals in this group showed a widespread moderate to severe vacuolar degeneration of the epithelial lining cells of the renal tubules (T) in the cortex and outer medulla. The affected tubules show epithelial cells that are variably swollen with numerous clear spaces in their cytoplasm. Some of the affected tubules show shrunken hyperchromatic nuclei. Glomerulus (G); Bowman's capsule (black arrow); blood vessel (BV). H&E  $\times$  100



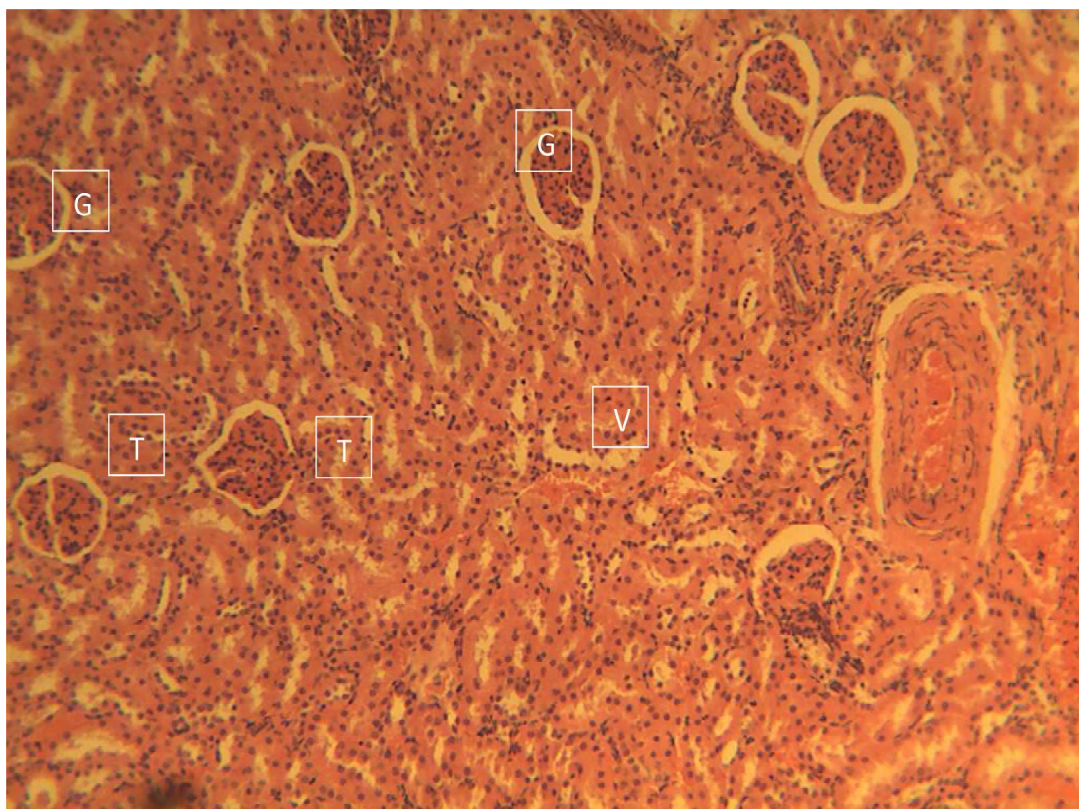


Plate 6: Control group of the male kidney exposed to no extract

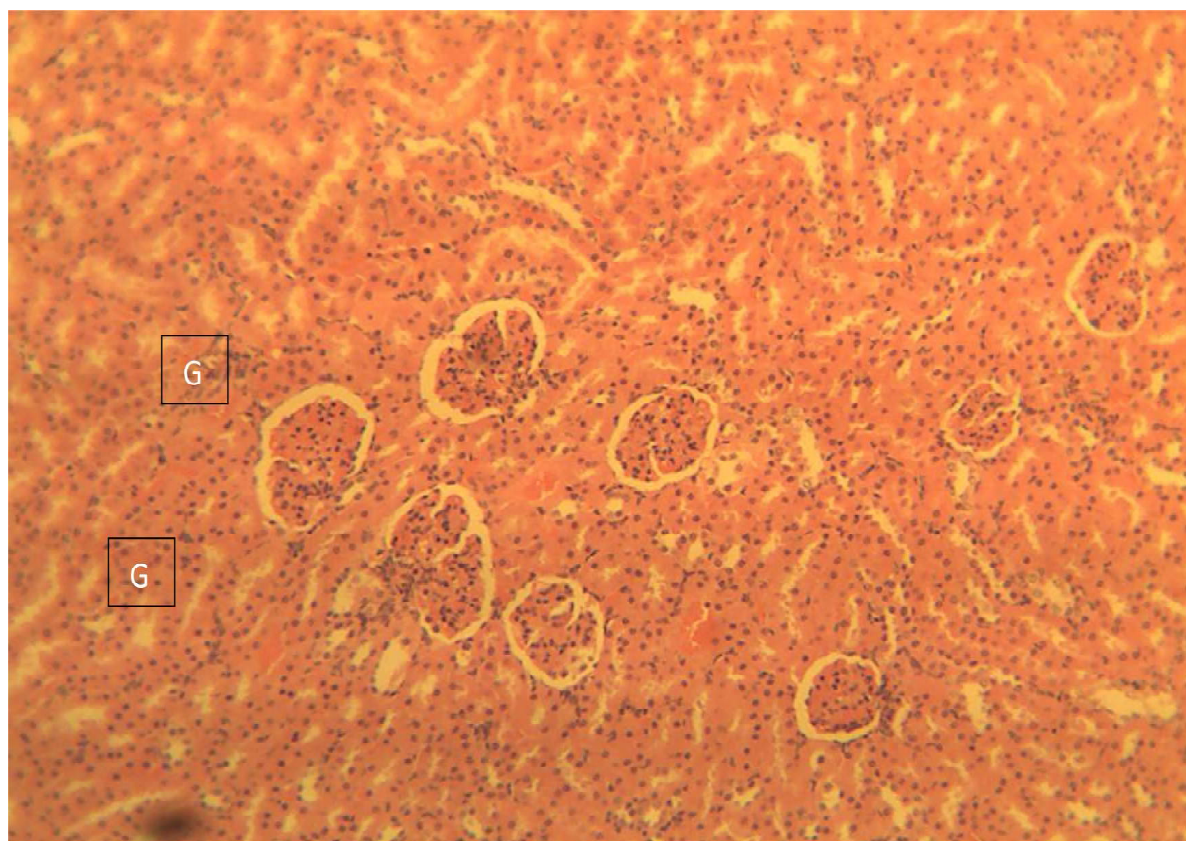


Plate 7: Male kidney of the group exposed to 200 mg/kg of aqueous extract



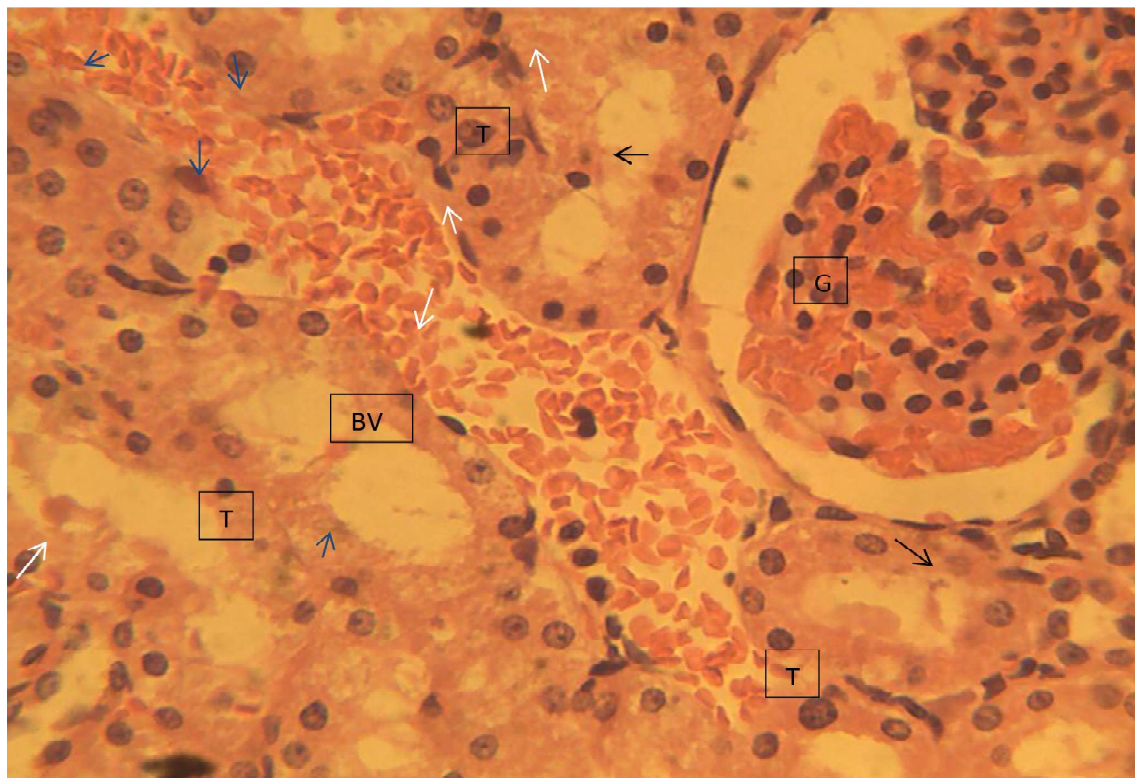


Plate 8: Male kidney of the group exposed to 800 mg/kg of aqueous extract

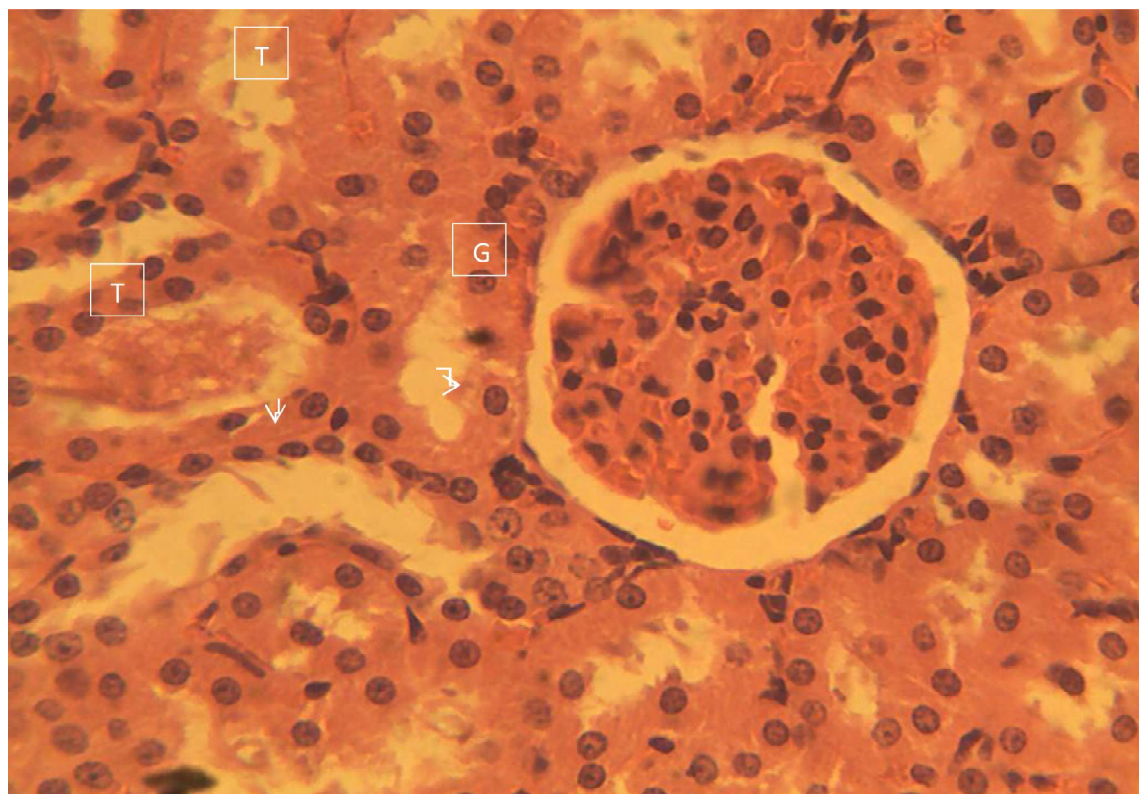
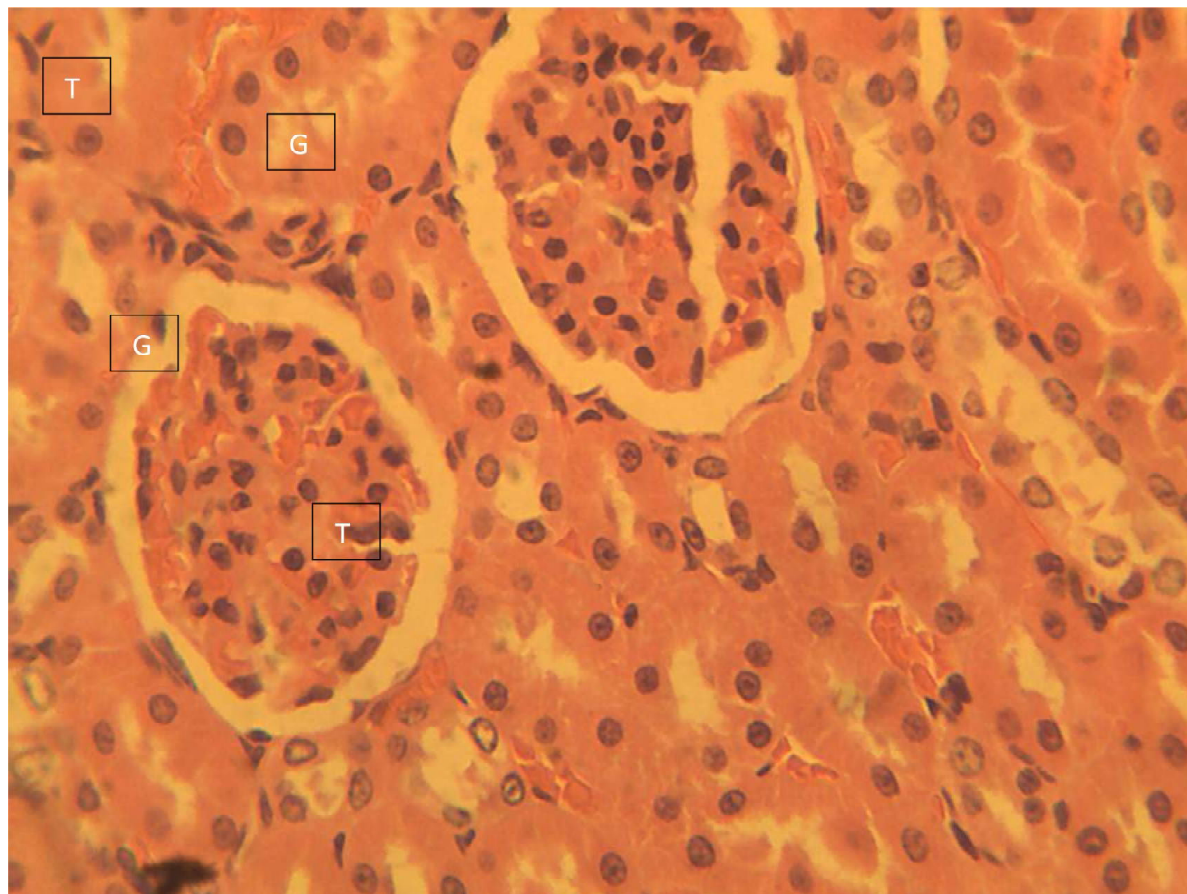


Plate 9: Male kidney of the group exposed to 200 mg/kg of methanol extract



**Plate 10: Male kidney of the group exposed to 800 mg/kg of methanol extract**

## 6.2. Female liver

Sections of the liver from the animals in this group showed the normal histo-architecture of the mammalian liver. Normal hepatic sinusoids consisting of normal hepatocytes were observed. The hepatocytes were arranged in interconnecting chords around the central vein (C), radiating towards the periphery of the sinusoids to the portal areas (P) which showed normal structures of the portal triad (hepatic artery, hepatic vein and bile duct). H&E  $\times$  100

Just as observed in the control group, sections of the liver from the animals in this group showed the normal histo-architecture of the mammalian liver. Normal hepatic sinusoids consisting of normal hepatocytes were observed. The hepatocytes were arranged in interconnecting chords (arrow) around the central vein (C), radiating towards the periphery of the sinusoids to the portal areas which showed normal structures of the portal triad (hepatic artery, hepatic vein and bile duct). H&E  $\times$  100

Sections of the liver collected from the animals in this group showed multifocal, mild to moderate inflammatory cellular infiltration of the liver (arrow). The inflammatory cells are dispersed within the tissue involving all the zones of the hepatic lobules. Central vein (C); Portal area (P). H&E  $\times$  100.

Sections of the liver collected from the animals in this group showed a mild vacuolar change in the hepatocytes of all the zones of the hepatic lobule. The hepatocytes show minute, clear, cytoplasmic vacuoles (white arrow). The nuclei appear normal. Central vein (V); Sinusoidal space (black arrow); Bile duct (B); Hepatic artery (A). H&E  $\times$  100

This section of the liver showed multifocal, moderate to severe inflammatory cellular infiltration of the liver (arrow). The hepatocytes in the hepatic cords are swollen, with a compressing effect on the sinusoidal spaces (arrow), occluding the space and contains multiple coalescent clear cytoplasmic vacuoles (white arrow). The inflammatory cells are dispersed within the tissue involving all the zones of the hepatic lobules. Hepatic artery(A); Bile duct (B). H&E  $\times$  100



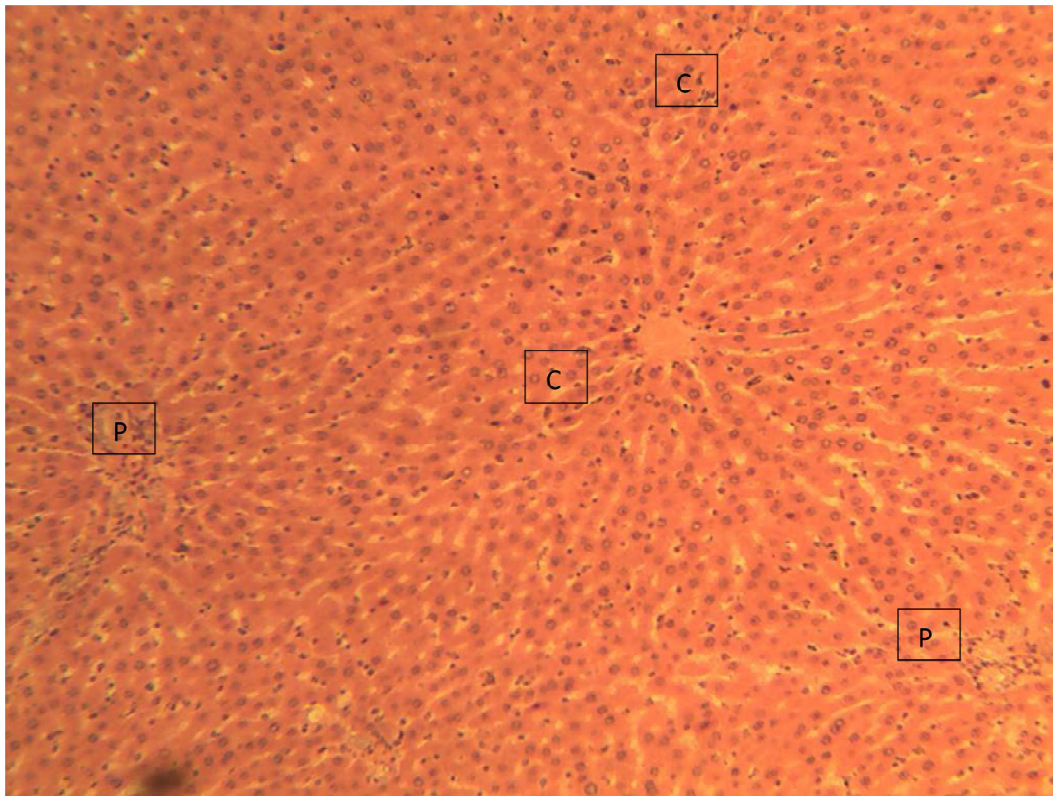


Plate 11: Control group of the female albino rats liver exposed to no extract

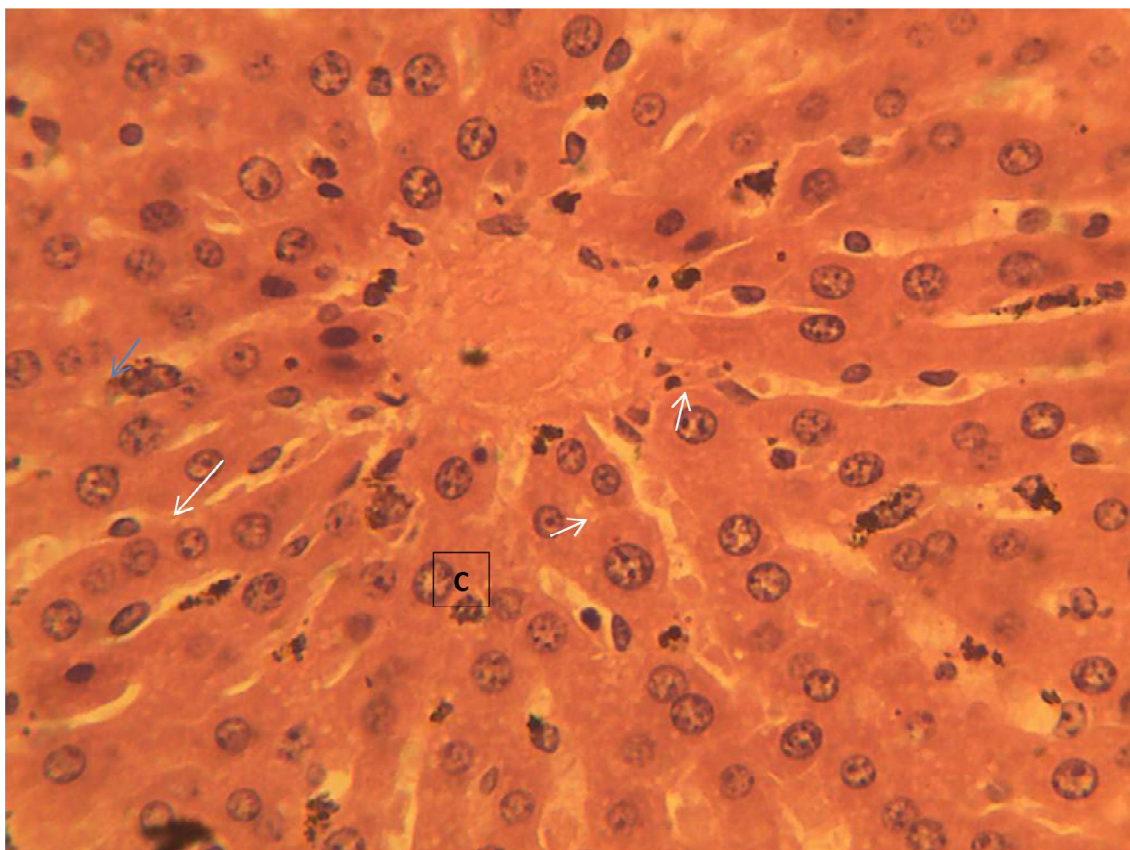


Plate 12: Female liver of the group exposed to 200 mg/kg of aqueous extract



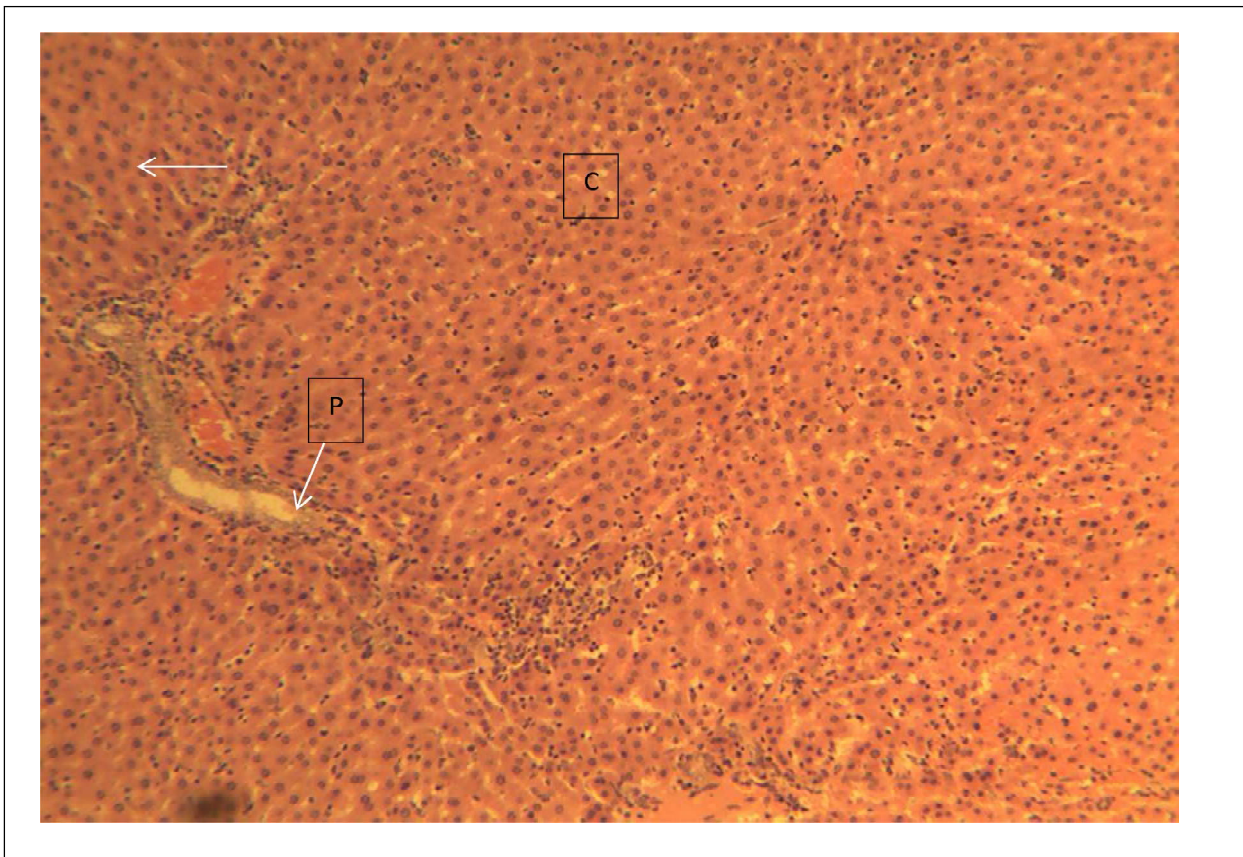


Plate 13: Female liver of the group exposed to 800 mg/kg of aqueous extract

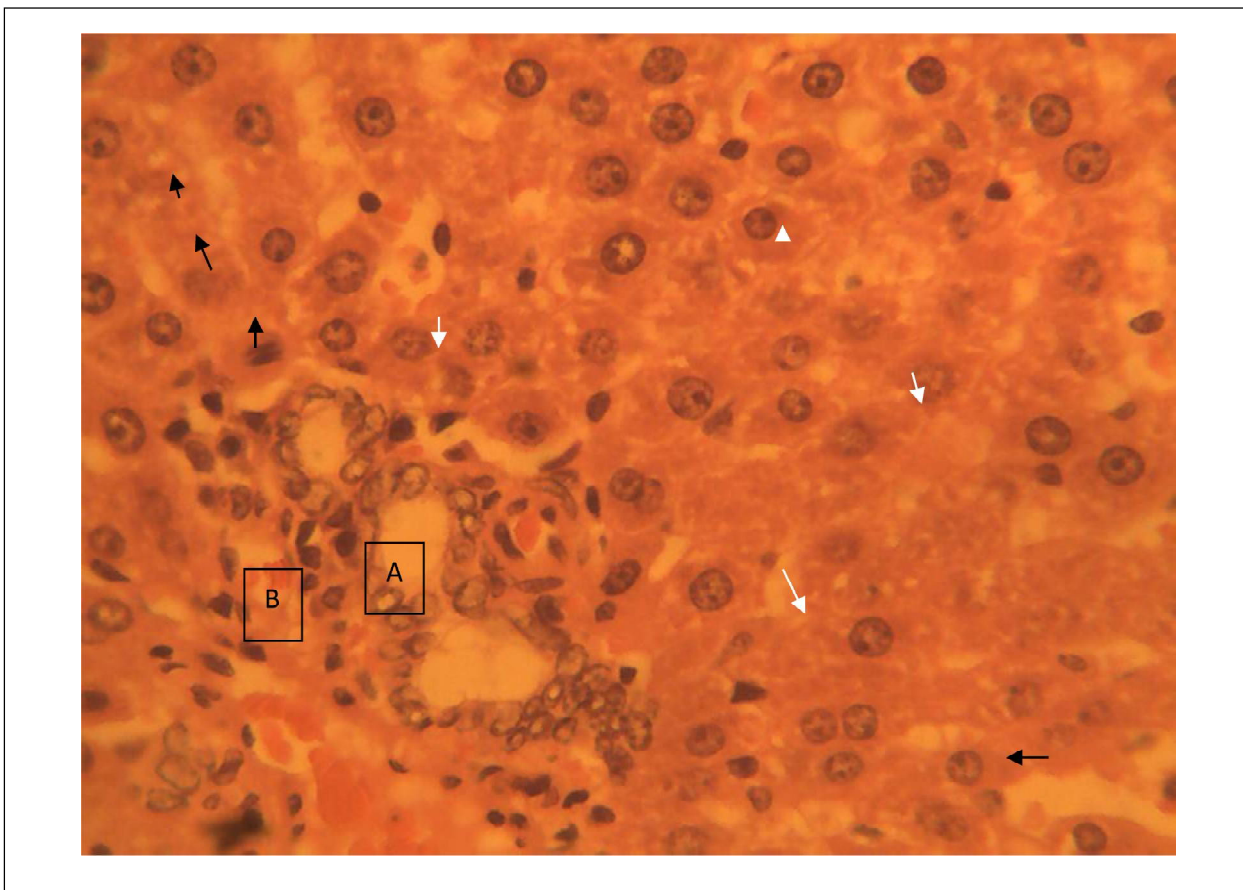
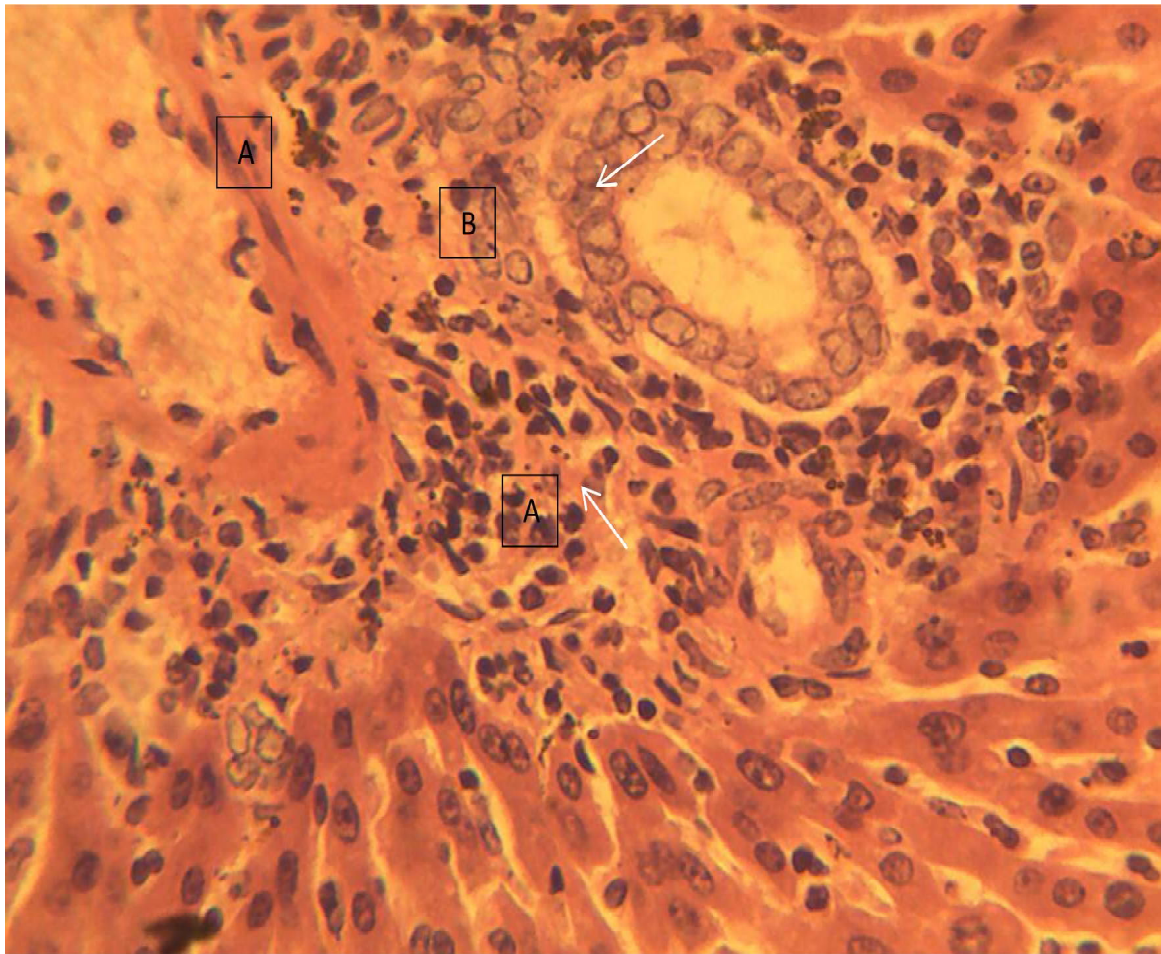


Plate 14: Female liver of the group exposed to 200 mg/kg of methanol extract





**Plate 15: Female liver of the group exposed to 800 mg/kg of methanol extract**

### **6.3. Female Kidney**

Sections of the kidney collected from the animals in this group showed the normal histo-architecture of the mammalian kidney. Normal components of the cortex and medulla (both outer and inner medulla) were observed. The sections showed normal glomeruli in Bowman's capsules embedded in a sea of normal renal tubules (proximal convoluting tubules, pars recta, distal convoluting tubules and collecting ducts). Glomeruli (G); Bowman's capsule (arrow); Renal tubules (T). H&E  $\times$  100

Sections of the kidney collected from the animals in this group showed the normal histo-architecture of the mammalian kidney. Normal hepatic sinusoids consisting of normal hepatocytes were observed. Normal Glomeruli (G) and renal tubules (RT) were observed. Blood vessel (arrow). H&E  $\times$  100.

Section of the kidney collected from the animals in this group showed very mild cellular swelling of the renal tubular epithelial lining cells. Tiny clear spaces can be observed in the cytoplasm of the affected cells. Glomeruli (G); Bowman's capsule (arrow); Renal tubules (RT). H&E  $\times$  100

Sections of the kidney collected from the animals in this group showed the normal histo-architecture of the mammalian kidney though slightly different from groups 2 and 3. The changes noticed were insignificant. Normal Glomeruli (G) and renal tubules (RT) were observed. Blood vessel (arrow). H&E  $\times$  100

Sections of the kidney collected from the animals in this group showed a widespread moderate to severe vacuolar degeneration of the epithelial lining cells of the renal tubules (T) in the cortex and outer medulla similar to that of group C. The affected tubules show epithelial cells that are swollen with numerous clear spaces in their cytoplasm. Glomerulus (G); Bowman's capsule (black arrow); blood vessel (BV). H&E  $\times$  100



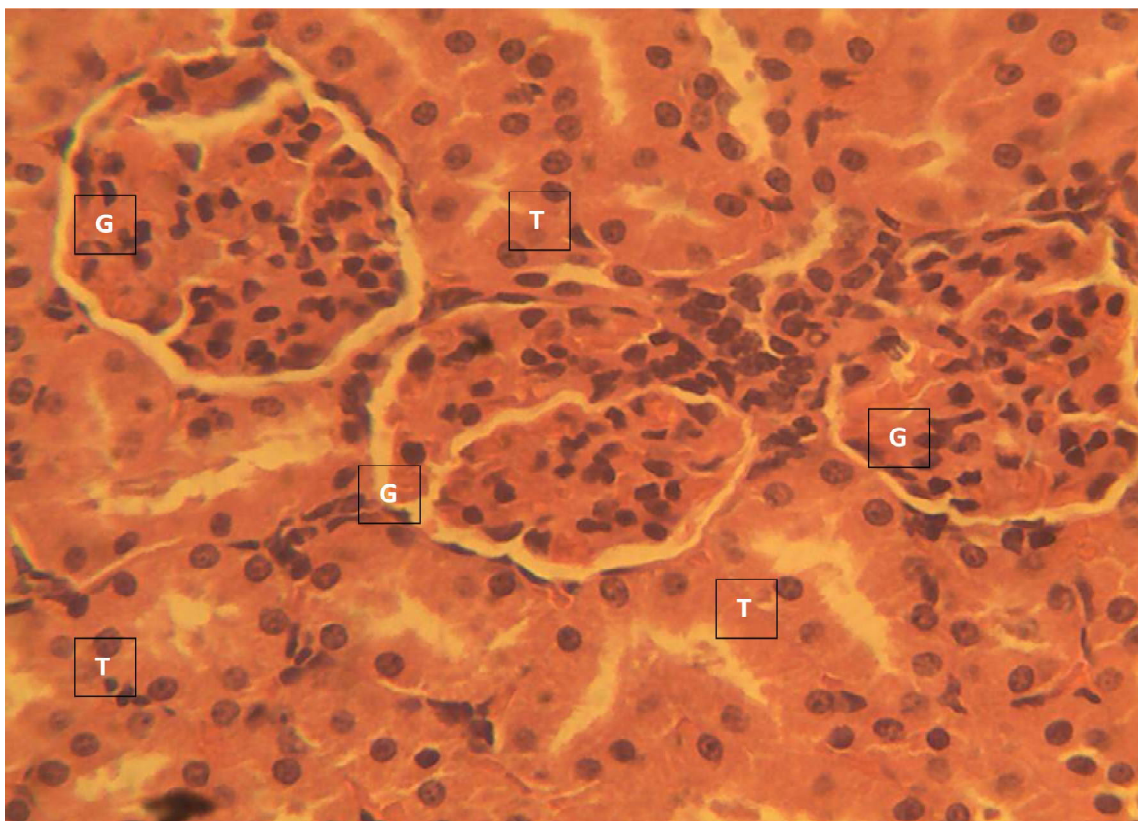


Plate 16: Control group of the female kidney exposed to no extract

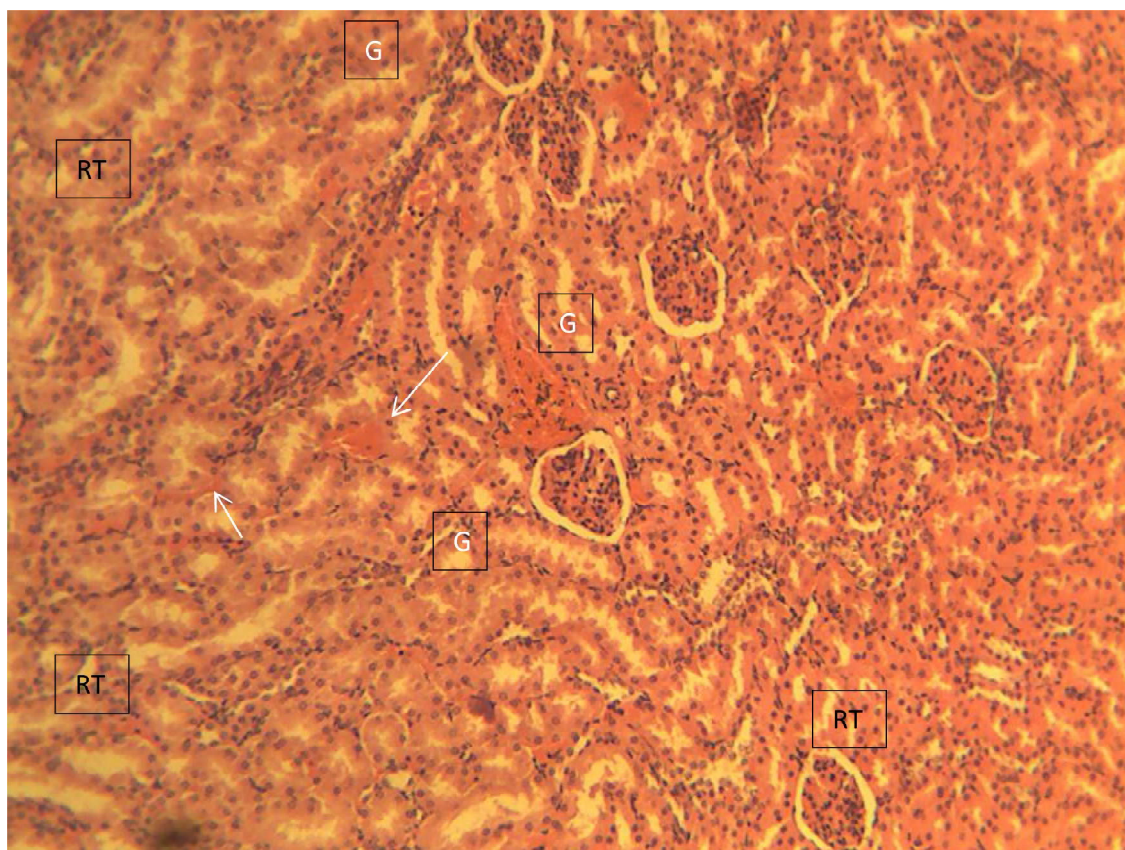


Plate 17: Female kidney of the group exposed to 200 mg/kg of aqueous extract



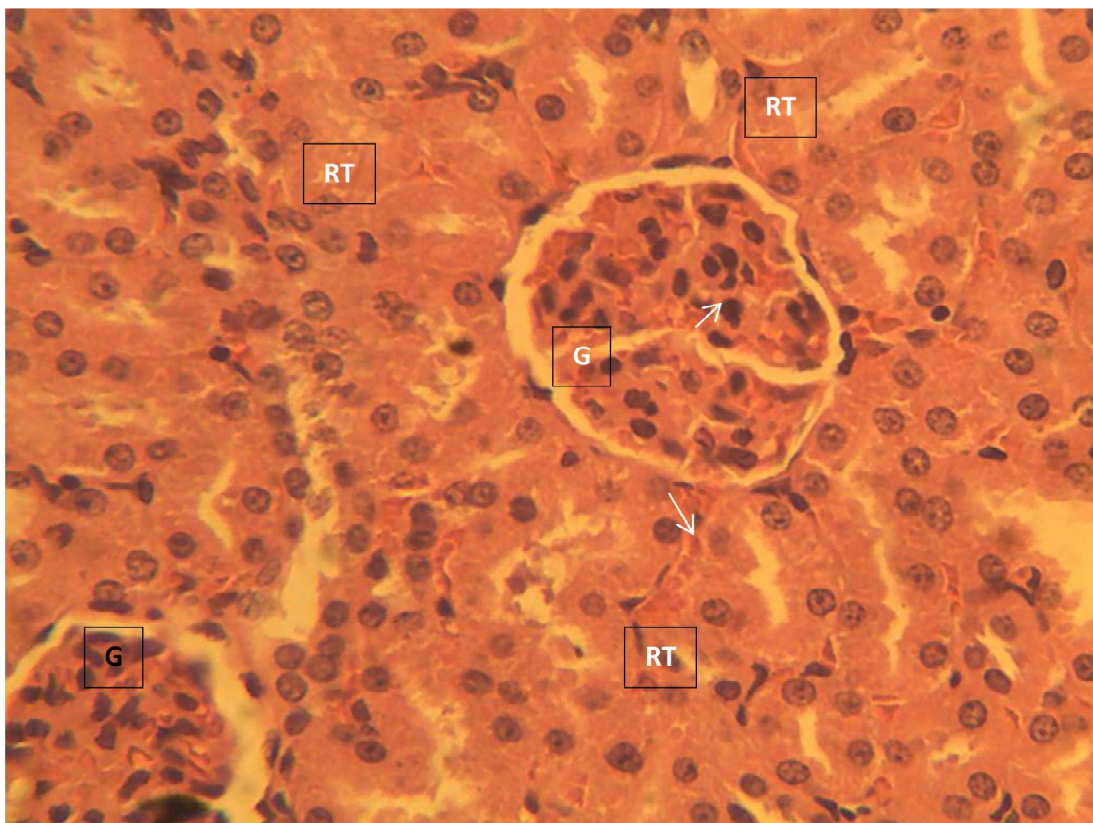


Plate 18: Female kidney of the group exposed to 800 mg/kg of aqueous extract

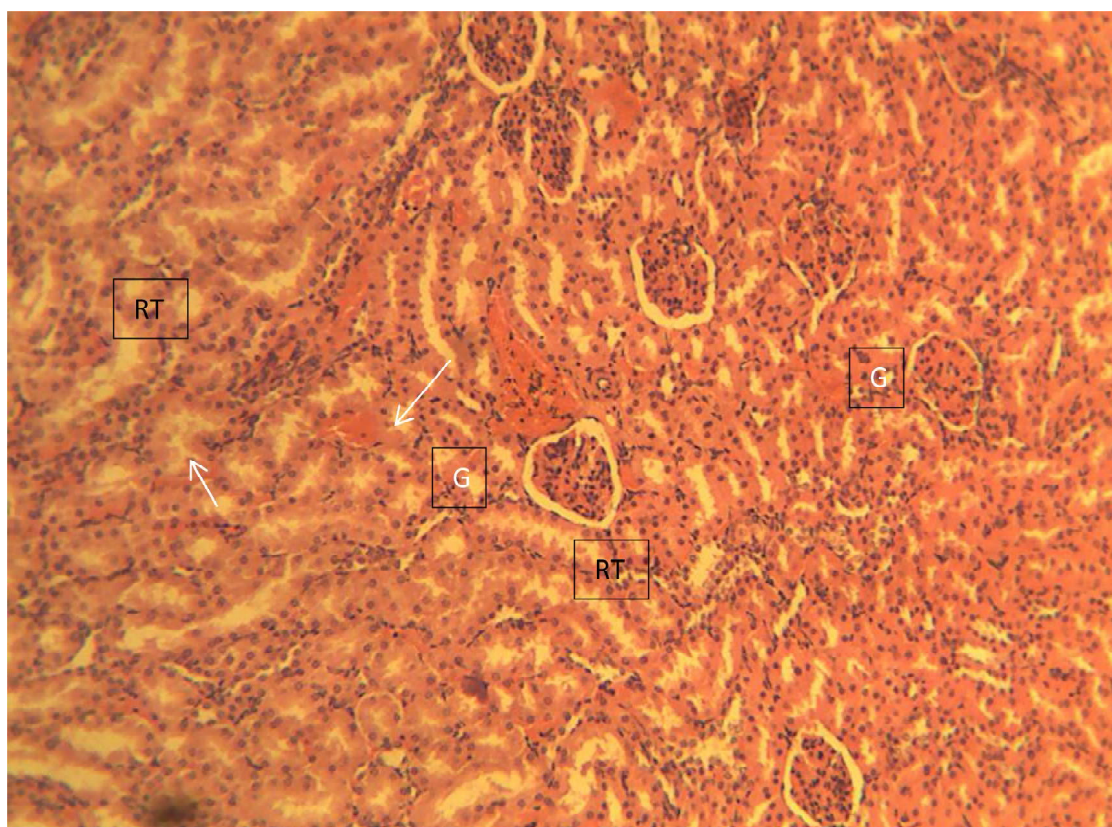
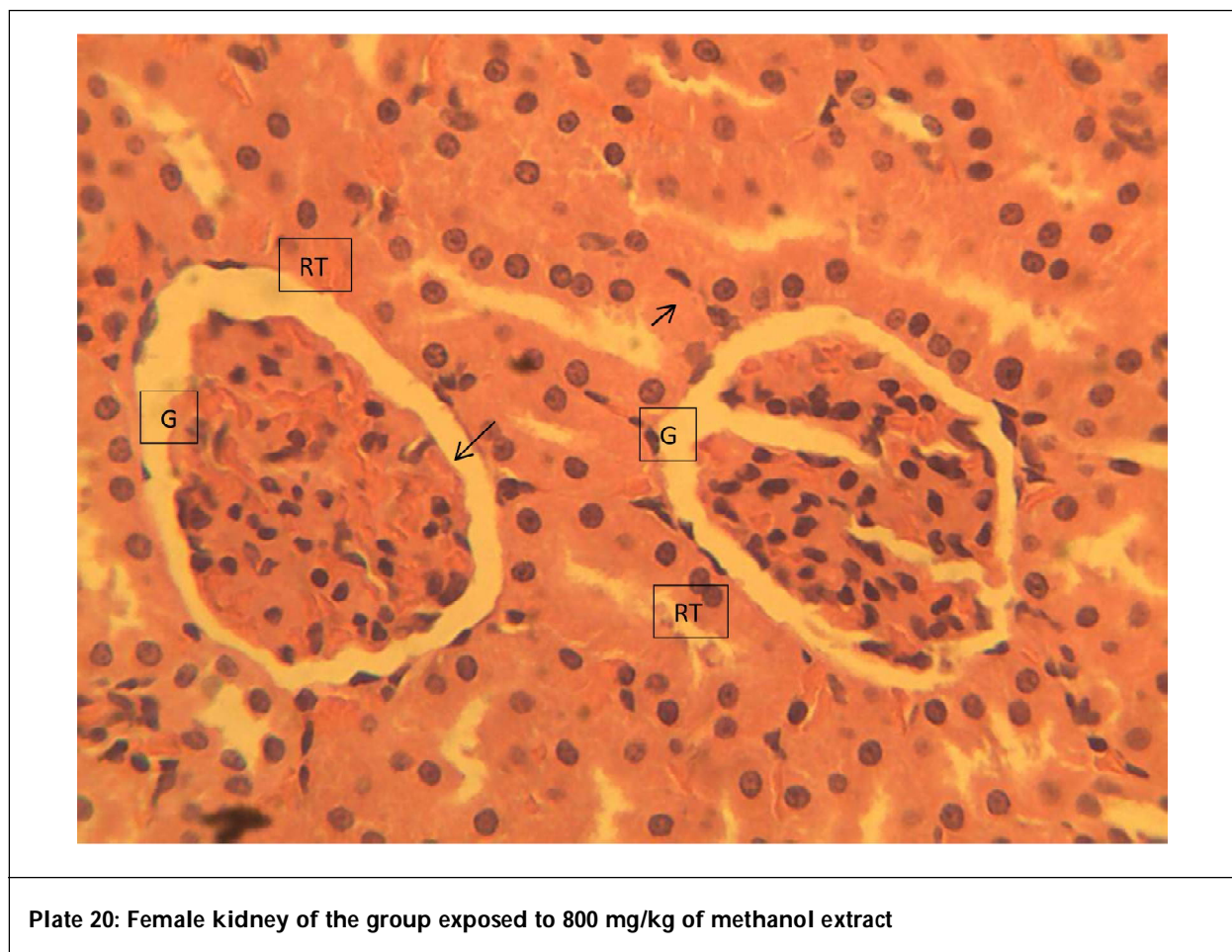


Plate 19: Female kidney of the group exposed to 200 mg/kg of methanol extract



## 7. Discussion

Liver function tests are groups of clinical assays designed to give information about the functional state and integrity of the liver. Sarada and Madhanyankutty, (1990) noted that elevation of a given enzyme activity in serum is thought to reflect its increased rate of entrance into serum from damaged liver cells and aminotransferases are a group of enzymes that are sensitive indicators of liver cell injury. The aminotransferases occupy a central position in the amino acid metabolism as they help in retaining amino groups (to form new amino acid) during the degradation of amino acids and are also involved in the biochemical regulation of intracellular amino acid pool. Depletion of these enzymes in the liver, leads to decrease in glutamate concentration and other important biomolecules. The liver function parameters, ALP, ALT and AST of the male and female albino rats presented in (Tables 1 and 2), showed significant increase in all the groups that were exposed to aqueous and methanol extracts of *A. montanus* leaves compared to control groups ( $p < 0.05$ ). The male and female albino rats displayed the same dose-dependent elevations in these enzyme assays. This shows that there may be presence of toxic substances and evidence of cumulative toxicity as reflected by degenerative changes in the liver histology of the animals examined as presented in (plates 1-9 and 19-28) for the male and female rats respectively. The groups administered methanol extract showed significant increase in enzyme level relative to aqueous extract. This could be attributed to the extraction of more bioactive components of the leaves by methanol compared to water. The significant ( $p < 0.05$ ) increase in Alp levels may be as a result of large bile duct obstruction, intrahepatic cholestasis or infiltration diseases of the liver (Evans et al., 2002). The increase in the various liver enzymes is in agreement with the results obtained by Djami et al. (2011) on the same plant. The liver of female rats did not show deviation in the groups exposed to 200 and 400 mg/kg aqueous extract relative to other groups that showed mild to severe degenerations of the hepatocytes compared to their control group.

Total protein and albumin are major proteins, synthesized in the liver and play important roles in detecting liver diseases. Total protein, which is among the liver parameters presented in (Tables 1 and 2) for male and female albino rats respectively, may be used to measure nutritional status as decrease is associated with liver or kidney disorder, although high protein level may lead to inflammation (Djami et al., 2011). The result from



this study, showed significant ( $p < 0.05$ ) decrease in the groups that were exposed to 400 mg/kg aqueous extract for only the male rats, 600, 800 mg/kg aqueous, 200, 400, 600 and 800 mg/kg methanol extracts of the plant leaves for both male and female albino rats when compared to their various control groups that were not exposed to the extracts. Although no significant ( $p < 0.05$ ) difference was noted in the 200 mg/kg aqueous extract for male and up to 400 mg/kg of aqueous extract for the female rats compared to control groups. This is in consonance with the report by Djami *et al.*, (2011) who observed no significant difference when aqueous extract of *A. montanus* leaves were used.

Albumin level presented in (Tables 1 and 2), showed no significant difference in the group that was exposed to 200 mg/kg of the aqueous extract for the male rats while other groups exposed to 400, 600, 800 mg/kg aqueous, 200, 400, 600 and 800 mg/kg of methanol extracts showed significant ( $p < 0.05$ ) decreases compared to the control group for male rats. Albumin did not show significant ( $p < 0.05$ ) difference for the female albino rats in the groups exposed to 200, 400 and 600 mg/kg aqueous extract while the groups exposed to 800 mg/kg aqueous, 200, 400, 600 and 800 mg/kg methanol extracts showed significant decrease compared to control groups. Mbaka *et al.* (2014) noted that increase in albumin and total protein is associated with hepato-protective properties. This plant leaf may lead to liver impairment since it decreased albumin with increase in dose as observed in this study. Total bilirubin also presented in (Tables 1 and 2), showed no significant ( $p < 0.05$ ) difference in the aqueous group exposed to 200 and 400 mg/kg for male and 600 mg/kg of aqueous extract for female albino rats compared to their various control groups. The group that received 800 mg/kg of aqueous extract and the groups that received 200, 400, 600 and 800 mg/kg methanol extract showed significant ( $p < 0.05$ ) increase in both male and female albino rats compared to their various control groups. This increase may be associated to hepatic jaundice which is an indicative of liver injury. Direct bilirubin presented in (Tables 1 and 2), showed no significant difference in the groups that were exposed to 200, 400, 600, 800 mg/kg of aqueous, 200, 400, 600 and 800 mg/kg methanol extract compared to their control groups. However the group that received 800 mg/kg of methanol extract for male rats showed a significant ( $p < 0.05$ ) decrease compared to control group. This suggests the plant may induce hepato-toxicity with increase in dose and methanol extraction may lead to more toxic effect than aqueous extraction.

Renal function assessments are used to observe the state of the kidney and its role in renal physiology. Creatinine assessed for the male rats as shown in (Tables 3 and 4), showed a significant ( $p < 0.05$ ) decrease in the groups administered 200 and 400 mg/kg of aqueous extract compared to control group. There was a significant ( $p < 0.05$ ) increase on the groups exposed to 600, 800 mg/kg of aqueous, 400, 600, and 800 mg/kg of methanol extracts compared to control groups. In the female rats findings showed significant ( $p < 0.05$ ) increase in the groups exposed to 200, 400, 600, 800 mg/kg of aqueous extract, 200, 400, 600 and 800 mg/kg of methanol extracts compared to control group. This is in contrast to Djami *et al.* (2011) who reported no significant difference in aqueous extract of this plant leaves for creatinine. The groups administered 400, 600 and 800 mg/kg methanol extract showed significant increase relative to groups administered aqueous extract for both male and female rats. This is confirmed in the histopathology architecture of the kidney of the animals in (plates 6 to 10) for male and (16 to 20) for female rats. This increase may be attributed to kidney disorder. Urea showed no significant ( $p < 0.05$ ) difference in the groups exposed to 200 and 400 mg/kg of aqueous extract for male rats compared to control group. A significant ( $p < 0.05$ ) decrease was observed in the groups exposed to the extracts for male rats compared to control group. The female rats exposed to the extracts showed significant ( $p < 0.05$ ) decreases compared to control group. Ogbuleka *et al.* (2016) posited similar findings on the same plant. This decrease may be associated with meliorating potentials hence the plant leaves may help in managing urea related diseases. The histo architecture of the groups exposed to 200, 400 and 600 mg/kg of aqueous extract showed similar architecture to the plate of the normal control group for the male rats. The groups (Plate 1 to 5) showed mild to multifocal degeneration of the hepatocytes compared to the plate of control group for the male rats. The male kidney histo architecture showed mild lesions to severe vacuolar degeneration of the epithelial lining cells of the renal tubules in the groups (Plate 17 to 20) compared to control group. The female kidney showed normal mammalian kidney architecture in the groups (Plate 16 to 17) showed moderate to widespread severe degeneration of the renal tubules compared to control group. These changes may be based on the properties of the plant leaves which may have affected the animals.

## 8. Conclusion

Findings from this study has shown that *A. montanus* leaves may exhibit renal and hepatic impairment with increased dosage; hence should be detoxified before usage.

## References

- Adeyemi, O.O., Okpo, S.O. and Young-Nwafor, C.C. (1999). The relaxant activity of the methanolic extract of *Acanthus montanus* on intestinal smooth muscles. *Journal of Ethnopharmacology*.68, 169-173.
- Adeyemi, O.O., Okpo, S.O. and Young-Nwafor, C.C. (2004). The analgesic effect of the methanolic extract of *Acanthus montanus*. *Journal of Ethnopharmacology*. 90, 45-48.
- Asongalem, E.A., Foyet, H.S., Ekobo, S., Dimo, T. and Kamtchouing, P. (2004). Anti-inflammatory, lack of central analgesia and antipyretic properties of *Acanthus montanus* (Ness) T.Anderson. *Journal of Ethnopharmacology*.95, 63-68.
- Baker, F.F. and Silventon, R.E. (1985). *Introductory to medical laboratory technology* (5th ed., p.604), London: Butterworth and Co.Publishers LTD.
- Bessey, O.A., Lowery, O.H. and Brock, M.J. (1946). A method for the rapid determination of alkaline phosphatase with five cubic millimeters of serum. *Journal of Biological Chemistry*.164, 321-329.
- Djami, T.A., Asongalem, E.A., Nana, P., Choumessi A., Kamtchouing P. and Asonganyi T. (2011). Subacute toxicity study of the aqueous extract from *Acanthus montanus*. *Electronic Journal of Biology*.7 (1), 11-15.
- Doumas, B.T., Watson, W.A. and Briggs, A.G. (1971). Albumin estimation. *International Journal of Clinical Chemistry and Diagnostic Laboratory Medicine*, 31, 87-96.
- Evans, C.D., Oien, K.A., Mac-Sween, R.N. and Mills, P.R. (2002). Blood pressure depression by the fruit juice of *Carica papaya* Linn in renal and Doca-induced hypertension in rats. *Phytochemical Resources*.14 (4), 235-239.
- Henry, R.S and Winkelman, R. (1974). *Clinical chemistry principles and techniques* (2nd ed., p.168). Washiton: Herper and Row Hagerstown.
- Jendrassik, L. and Grof, P. (1938). *Biochemistry*.297, 81-82.
- Mbaka, G.O., Obgonna, S.O. and Awoyenu, F.O (2014). Acute and sub-acute toxicity studies of ethanol seed extract of *Raphia hookeri* on swiss Albina rats. *British Journal of Pharmacology Research*.4, 1196-1208.
- NIH (1985). *National Research Council Guide for the care and use of laboratory animals*. Publication no. 85-123 (rev.) National Institute Health, Bethesda, M.D.
- Ogbuleka, N.A., Mbakwem, A.C. and Frank-Peterside, N. (2016). The biochemical and histopathological effects of four plants (*Acanthus montanus*, *Euphorbia hirta*, *Vernonia amygdalina* and *Ocimum gratissimum*) leaf extracts on the liver and kidney of Wister rats. *Cancer Biology*.6 (1), 60-67.
- Okoli, C.O., Akah, P.A., Onuoha, N.J., Okoye, T.C., Nwoye, A.C. and Nwosu, C.S. (2008). *Acanthus montanus*: An experimental evaluation of the antimicrobial, anti-inflammatory and immunological properties of a traditional remedy for furuncles. *BMC Complementary and Alternative Medicine*.8, 27.
- Owolabi, J., Omogbai, E.K. and Obasuyi, O. (2007). Anti-fungal and anti-bacterial activities of the ethanol and aqueous extracts of *Kigelia africana* (Bignoniaceae stem bark). *African Journal of Biotechnology*.6 (14), 882-885.
- Reitman, S. and Franklin, S. (1957). A colorimetric method for the determination of serum glutamic oxaloacetate and glutamic pyruvic transaminases. *American Journal of Clinical Pathology*.28, 56-58.
- Sakpa, C.L. and Uche-Nwachi, O.E. (2014). Histological effects of aqueous leaf extract of chaya (*Cnidoscolus aconitifolius*) on the testes of adult wistar rats. *Journal of Medicine and Biomedical Research*.12 (2), 120-128.
- Salah, A.I., Ali, H. and Imad, H.H. (2015). Spectral analysis and anti-bacterial activity of methanolic fruit extract of *Citrullus colocynthis* using gas chromatography-mass spectrometry. *African Journal of Biotechnology*.14 (46), 3131-3158.
- Sarada, S. and Madhanvankutty, K. (1990). *Secretion of small and large intestine in: Textbook of human physiology* (4<sup>th</sup> ed., p.582). New Delhi: Schand and Company Ltd.
- Taursky, H.H. (1956). Modified alkaline picrate method for the determination of creatinine in serum. *International Journal of Clinical Chemistry and Diagnostic Laboratory Medicine*.1, 200-202.
- Weatherburn, M.W. (1967). Phenol-hypochlorite reaction for determination of ammonia. *Analytical Chemistry*. 39 (8), 971-974.

**Cite this article as:** Iwueke, Adaku. V., Chukwu, Ezinne. C., Onuoha, Obinna. U. and Osuocha K.U. (2021). Toxicological studies on *Acanthus montanus* leaf extracts in male and female albino rats. *African Journal of Biological Sciences*. 3(1), 34-51. doi: 10.33472/AFJBS.3.1.2021.34-51.