

<https://doi.org/10.33472/AFJBS.6.Si3.2024.276-283>



African Journal of Biological Sciences

Journal homepage: <http://www.afjbs.com>



Research Paper

Open Access

## Analgesic Efficacy of the Combination of Transversus Thoracic Muscle Plane and Pectoral Nerve Blocks in Modified Radical Mastectomy

Ahmed Abdo Mohamed Abdallah\*, Somia Abd El Aziz Elsheikh,

Reda Hasan Tabashy, Sayed Mahmoud Abed, Mahmoud Ahmed Kamel

Anesthesiology, Surgical Intensive Care and Pain Medicine Department, National Cancer Institute, Cairo University, Cairo, Egypt

\*Corresponding Author, Email: [pproof2@yahoo.com](mailto:pproof2@yahoo.com)

Article History

Volume 6, Issue Si3, 2024

Received: 21 Mar 2024

Accepted: 08 May 2024

doi: 10.33472/AFJBS.6.Si3.2024.276-283

### Abstract

**Background:** Modified radical mastectomy (MRM) results in postoperative acute pain ranging from mild to severe. This work aimed to assess the analgesic efficacy of transversus thoracic muscle plane-pectoral nerve (TTP-PECS) blocks after MRM.

**Methods:** This pilot study was conducted on 10 females between the ages of 21 and 60 who were categorized as physical status II and III by the American Society of Anaesthesiologists (ASA) and underwent MRM under general anesthesia. TTP-PECS blocks were administered 30 minutes before the surgical incision using ultrasound guidance.

**Results:** 3 (30%) patients needed intraoperative fentanyl. The mean ( $\pm$ SD) value of time to first request of rescue analgesia was 3.1 ( $\pm$  0.88) h. The mean ( $\pm$ SD) value of the total amount of rescue morphine use was 30 ( $\pm$  4.71) mg. The median (IQR) of visual analog scale was 1(0 - 1) at PACU, 1(1 - 1) at 1 h, 2.5(1.25 - 5.25) at 2h, 3(3 - 6.75) at 4 h, 3.5(3 - 6.25) at 6 h, 4(4 - 4.75) at 12 h and 4(3.25 - 4.75) at 24 h. Vascular injury, pneumothorax, local anesthetics (LA) toxicity, and anaphylactic shock didn't occur in any patient. 2 (20%) patients suffered from postoperative nausea and vomiting (PONV). Ramsay sedation score was 2 in 7 (70%) patients, 3 in 2 (20%) patients, and 4 in 1 (10%) patient.

**Conclusions:** In patients who underwent MRM, combination of TTP-PECS provided intraoperative and postoperative analgesic control and reduced morphine use.

**Keywords:** Transversus Thoracic Muscle Plane, Pectoral Nerve, Modified Radical Mastectomy, Analgesia

**Introduction:**

Globally, breast cancer ranks first among all malignancies affecting women <sup>[1]</sup>. 20% to 68% of breast cancer patients endure prolonged distress following mastectomy, despite the fact that it is one of the most commonly performed surgical procedures <sup>[2]</sup>.

Modified radical mastectomy (MRM) involves the complete excision of the breast, including the areola, nipple, tissue, and the majority of axillary lymph nodes <sup>[3]</sup>. Pain is experienced by the majority of women in the days following the procedure. Prolonged hospitalization and escalated healthcare expenses are additional consequences of severe acute postoperative pain after breast surgery, in addition to impeding recovery and increasing the likelihood of chronic pain <sup>[4,5]</sup>. Consequently, improved pain management is urgently required <sup>[6]</sup>.

Regional anesthesia improved the efficacy of acute pain management, thereby reducing chronic pain <sup>[7]</sup>. Anesthesia for MRM has incorporated a wide variety of regional anesthesia techniques <sup>[8]</sup>. Interscalene brachial plexus blocks, intercostal nerve, and thoracic epidural are procedurally complex and associated with severe complications, which significantly limit their effectiveness <sup>[9]</sup>. Thoracic paravertebral block (TPVB) has been employed as an anesthetic due to its improved abirritation properties during MRM. Severe postoperative complications, including hypotension, intrathecal or epidural spread, and pleural puncture, impose limitations on the ability to employ this technique <sup>[10]</sup>.

The pectoral nerves (PECS) block exerts analgesic effects throughout the lateral mammary area, the medial cutaneous nerve that supplies sensation to the arm and forearm, the long thoracic and thoracodorsal nerves, as well as the intercostobrachial and lateral cutaneous branches of the intercostal nerves (Th2–6) <sup>[11]</sup>. Consequently, the effectiveness of the PECS block in the control of postoperative pain subsequent to breast cancer surgery has been observed. Its incapability to block the internal mammary area is a significant limitation of the PECS block <sup>[12]</sup>.

The capacity of the transversus thoracic muscle plane (TTP) block to block multiple anterior branches of the intercostal nerves (Th2–6), which regulate the internal mammary area, is considerable <sup>[13]</sup>. Hence, postoperative analgesia can be effectively managed with TTP-PECS combination during breast cancer surgery <sup>[14]</sup>.

This work aimed to assess the analgesic efficacy of the combination of TTP-PECS blocks after MRM.

**Patients and Methods:**

This pilot study was conducted on 10 females between the ages of 21 and 60 who were categorized as physical status II and III by the American Society of Anesthesiologists (ASA) and underwent MRM under general anesthesia. The study was conducted after approval from the Ethical Committee Cairo University, Egypt. Consent was obtained in writing from the patient or relatives.

Exclusion criteria were history of substance abuse, systemic infectious diseases, those with psychiatric or neurological disorders, breast reconstruction or secondary or nonradical surgery, body mass index (BMI) >35 kg/m<sup>2</sup>, coagulation disorders, and infections at the puncture sites. Preliminary laboratory investigations, including complete blood counts (CBC), coagulation studies, renal function, and liver function, were conducted in addition to obtaining medical and surgical histories and conducting clinical examinations. Every patient was given detailed instructions on the appropriate utilization of the visual analog scale (VAS) for pain assessment after the procedure. A scale of zero denoted no pain and ten represented the most excruciating pain conceivable.

All patients were instructed to fast overnight. Patients were reassessed in the preparation area. A 500 ml lactated ringer solution was infused 30 minutes before surgery, and patients were premedicated with 2 mg of midazolam. Throughout the procedure, they were closely monitored via ECG, blood pressure, and pulse oximetry. For each procedure, the conventional method of

general anesthesia (GA) was utilized. Propofol 1.5-2.5 mg/kg and fentanyl 1 ug/kg were administered intravenously to induce GA. Endotracheal tube insertion followed administration of 0.15 mg/kg IV cis-atracurium. With 2% sevoflurane and 50% oxygen, GA was maintained. Cis-atracurium 0.03 mg/Kg were administered in increments. Following this, cases were mechanically ventilated to maintain 35–45 mmHg end-tidal CO<sub>2</sub> levels.

A 10-12 MHZ linear array probe (HFL38) was utilized in conjunction with a Sonosite M-Turbo C04TRGD ultrasound device. TTP-PECS blocks were administered 30 minutes before the surgical incision.

#### **PECS I block:**

The patients were positioned in a supine position, with the ipsilateral arm externally rotated and abducted by 90 degrees. After sterilizing the infra-clavicular and axillary regions and identifying the structures via ultrasound, the instrument was positioned in the lateral third of the clavicle. The instrument was advanced distally towards the axilla until the pectoral major muscle was identified, subsequent to the localization of the subclavian artery, axillary artery, and axillary vein. The instrument was moved laterally and distally until it reached the space between the second and third ribs. Ribs were tallied, with the second rib appearing first. The primary anatomical landmarks utilized under ultrasound guidance to determine the site of injection are the pectoralis minor and major, as well as the pectoral branch of the thoracoacromial artery. In order to determine the appropriate fascial plane, hydrodissection is performed to enlarge the space between the pectoralis muscles. Then, 10 ml of local anesthetics (LA) was injected in 5 cc increments, ensuring that intravascular injection was avoided by aspiration after each 5 cc.

#### **PECS II block:**

With the patients positioned identically to the PECS I block. Distally and laterally, the probe was maneuvered until it reached the space between the third and fourth ribs. Hydrodissection is utilized to establish the proper fascial plane by creating an aperture between the serratus anterior and pectoralis minor muscles. Then, 20 ml of LA was injected in 5 cc increments, ensuring that intravascular injection was avoided by aspiration after each 5 cc.

#### **TTP block:**

On the sagittal plane, a high linear transducer of the ultrasound system was affixed to the sternum on the same side of the operation. The count was performed from T2 near the clavicle to T5. The linear probe was then positioned between the fourth and fifth costal cartilages, which connect at the sternum near the nipple, after being rotated by 90°. The internal intercostal muscle and the transversus thoracic muscle were subsequently recognized. A 20G echogenic needle was introduced in an in-plane manner, proceeding from the lateral to the medial direction, subsequent to infiltrating the skin with 2 ml of 1% lidocaine. Hydrodissection and/or downward displacement of the pleura were observed through the injection of 3–5 ml saline after the needle tip was positioned deep to the intercostal muscles and superficial to the transversus thoracic muscle, specifically between the fourth and fifth costal cartilages that connect at the sternum. This occurred subsequent to the confirmation of negative aspiration for blood or air. A 15 ml bolus dose of bupivacaine 0.25% was administered.

Extubation occurred subsequent to the administration of neostigmine (0.08 mg/kg) and atropine (0.02 mg/kg) to counterbalance the residual neuromuscular blockade after the cessation of anesthesia during the operation. Patients who recovered from anesthesia were transferred to the post-anesthesia care unit (PACU).

A regimen of analgesics for the postoperative period was prescribed in accordance with established criteria. Each patient was administered 1 g of paracetamol every 6 hours as a

standard analgesic. A 3 mg bolus of morphine was administered as rescue analgesia if the VAS was greater than 3, with a follow-up 30 minutes later if the pain persisted until the VAS was less than 4. VAS was evaluated at PACU, 1, 2, 4, 6, 12, and 24 hours postoperatively. During hospital visits, complications were documented, including postoperative nausea and vomiting (PONV) and others that were associated with the drug or techniques utilized (e.g., procedure-induced pneumothorax, LA toxicity, hematoma in the puncture sites, and respiratory depression).

### Statistical analysis

The statistical study was conducted using SPSS v26, a program created by IBM Inc. of Chicago, IL, USA. There were quantitative variables shown as means and standard deviations (SD). We represented qualitative variables using percentages (%) and frequencies.

### Results

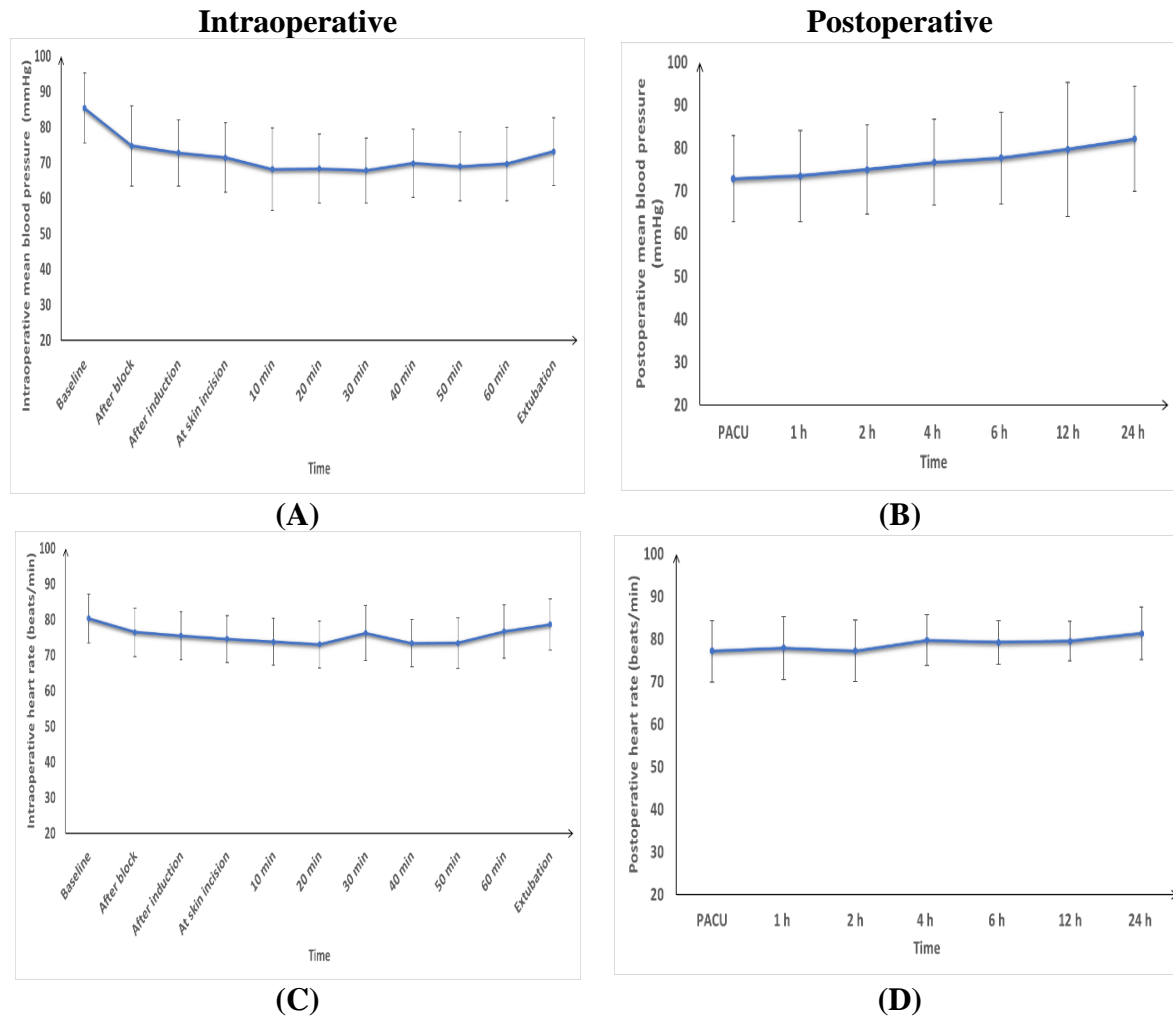
The mean ( $\pm$ SD) value of age was 47.1 ( $\pm$  8.89) years. The mean ( $\pm$ SD) value of weight was 83.4 ( $\pm$  4.45) kg. The mean ( $\pm$ SD) value of height was 166.9 ( $\pm$  6.38) cm. The mean ( $\pm$ SD) value of BMI was 30.05 ( $\pm$  2.66) kg/m<sup>2</sup>. ASA physical status was II in 8 (80%) patients and III in 2 (20%) patients. The mean ( $\pm$ SD) value of procedure time was 94.5 ( $\pm$  12.79) min. The mean ( $\pm$ SD) value of time to onset of the block was 5.9 ( $\pm$  1.52) min. **Table 1**

**Table 1: Demographic data, procedure time, and time to onset of block of the studied patients**

		(n=10)
<b>Age (years)</b>		47.1 $\pm$ 8.89
<b>Weight (kg)</b>		83.4 $\pm$ 4.45
<b>Height (cm)</b>		166.9 $\pm$ 6.38
<b>BMI (kg/m<sup>2</sup>)</b>		30.05 $\pm$ 2.66
<b>ASA physical status</b>	<b>II</b>	8 (80%)
	<b>III</b>	2 (20%)
<b>Procedure time (min)</b>		94.5 $\pm$ 12.79
<b>Time to onset of block (min)</b>		5.9 $\pm$ 1.52

Data presented as mean  $\pm$  SD or frequency (%). ASA: American Society of Anesthesiologists, BMI: body mass index.

The mean ( $\pm$ SD) value of intraoperative mean blood pressure measurements were 85.3 ( $\pm$  9.88) mmHg at baseline, 74.7 ( $\pm$  11.26) mmHg after block, 72.7 ( $\pm$  9.25) mmHg after induction, 71.4 ( $\pm$  9.85) mmHg at skin incision, 68.1 ( $\pm$  11.58) mmHg at 10 min, 68.3 ( $\pm$  9.72) mmHg at 20 min, 67.8 ( $\pm$  9.16) mmHg at 30 min, 69.8 ( $\pm$  9.66) mmHg at 40 min, 68.9 ( $\pm$  9.69) mmHg at 50 min, 69.6 ( $\pm$  10.37) mmHg at 60 min and 73.1 ( $\pm$  9.59) mmHg at extubation. The mean ( $\pm$ SD) value of intraoperative heart rate measurements were 80.2 ( $\pm$  6.89) beats/min at baseline, 76.4 ( $\pm$  6.83) beats/min after block, 75.4 ( $\pm$  6.77) beats/min after induction, 74.5 ( $\pm$  6.59) beats/min at skin incision, 73.7 ( $\pm$  6.55) beats/min at 10min, 73 ( $\pm$  6.57) at 20 min, 76.2 ( $\pm$  7.76) at 30min, 73.3 ( $\pm$  6.63) at 40 min, 73.4 ( $\pm$  7.11) at 50 min, 76.6 ( $\pm$  7.46) at 60 min and 78.6 ( $\pm$  7.2) at extubation between both groups. The mean ( $\pm$ SD) value of postoperative mean blood pressure measurements was 72.8 ( $\pm$  9.98) mmHg at PACU, 73.4 ( $\pm$  10.59) mmHg at 1 h, 74.9 ( $\pm$  10.4) mmHg at 2 h, 76.6 ( $\pm$  10.06) mmHg at 4 h, 77.6 ( $\pm$  10.64) mmHg at 6 h, 79.6 ( $\pm$  15.69) mmHg at 12 h and 82.1 ( $\pm$  12.19) mmHg at 24 h. The mean ( $\pm$ SD) value of postoperative heart rate measurements was 77.1 ( $\pm$  7.16) beats/min at PACU, 77.9 ( $\pm$  7.43) beats/min at 1 h, 77.2 ( $\pm$  7.24) beats/min at 2 h, 79.7 ( $\pm$  5.98) beats/min at 4 h, 79.2 ( $\pm$  5.09) beats/min at 6 h, 79.5 ( $\pm$  4.67) beats/min at 12 h and 81.3 ( $\pm$  6.17) beats/min at 24 h. **Figure 1**



**Figure 1: Intraoperative (A) mean blood pressure and (C) heart rate, postoperative (B) mean blood pressure and (D) heart rate of the studied patients**

The median (IQR) of VAS was 1(0 - 1) at PACU, 1(1 - 1) at 1 h, 2.5(1.25 - 5.25) at 2h, 3(3 - 6.75) at 4 h, 3.5(3 - 6.25) at 6 h, 4(4 - 4.75) at 12 h and 4(3.25 - 4.75) at 24 h. **Table 2**

**Table 2: VAS of the studied patients**

	(n=10)
<b>PACU</b>	1(0 - 1)
<b>1 h</b>	1(1 - 1)
<b>2 h</b>	2.5(1.25 - 5.25)
<b>4 h</b>	3(3 - 6.75)
<b>6 h</b>	3.5(3 - 6.25)
<b>12 h</b>	4(4 - 4.75)
<b>24 h</b>	4(3.25 - 4.75)

Data presented as median (IQR), \*: Significant when P value  $\leq 0.05$ , VAS: visual analog scale, PACU: Post anesthesia care unit.

3 (30%) patients needed intraoperative fentanyl. The mean ( $\pm$ SD) value of time to first request of rescue analgesia was 3.1 ( $\pm$  0.88) h. The mean ( $\pm$ SD) value of the total amount of rescue morphine use was 30 ( $\pm$  4.71) mg. **Table 3**

**Table 3: Number of patients who needed intraoperative fentanyl, time to first request of rescue analgesia, and total amount to rescue morphine use of the studied patients**

	(n=10)
<b>Number of patients who needed intraoperative fentanyl</b>	3 (30%)
<b>Time to first request of rescue analgesia (h)</b>	3.1 ± 0.88
<b>Total amount to rescue morphine use (mg)</b>	30 ± 4.71

Data presented as mean ± SD or frequency (%).

Vascular injury, pneumothorax, LA toxicity, and anaphylactic shock didn't occur in any patient. 2 (20%) patients suffered from PONV. Ramsay sedation score was 2 in 7 (70%) patients, 3 in 2 (20%) patients, and 4 in 1 (10%) patient. **Table 4**

**Table 4: Complications and Ramsay sedation score of the studied patients**

		(n=10)
<b>Vascular injury</b>		0 (0%)
<b>Pneumothorax</b>		0 (0%)
<b>Local anesthetics toxicity</b>		0 (0%)
<b>Anaphylactic shock</b>		0 (0%)
<b>PONV</b>		2 (20%)
<b>Ramsay sedation score</b>	<b>2</b>	7 (70%)
	<b>3</b>	2 (20%)
	<b>4</b>	1 (10%)

Data presented as frequency (%). PONV: Postoperative nausea and vomiting.

## Discussion

A novel approach to blocking the intercostal nerves, long thoracic nerves, and pectoral nerves spanning the third to sixth intercostals is ultrasound-guided interfascial plane blocks, of which type I (PECS I) and type II (PECS II) pectoral nerve blocks are examples [15]. An ultrasound-guided TTP might impede the internal mammary region's main supply lines, which include several anterior branches of the intercostal nerves (Th2-6) [13].

Patients undergoing MRM can benefit from enhanced postoperative analgesia with TTP-PECS, as demonstrated by the present case study. All ten female breast cancer patients who took part in this research study underwent standard MRM. The surgical site was entered through a transverse or longitudinal fusiform incision, during which lesions and other breast tissues were extracted. The lesion was subsequently extracted by utilizing the superficial pectoralis major fascia layer. It is necessary to cleanse the axillary lymph nodes following lesion removal [16].

In agreement with our study, H. Ueshima and H. Otake [11] conducted a prospective comparison of the analgesic quality after MRM utilizing general anesthesia, PECS blocks, and TTP blocks as opposed to general anesthesia and PECS blocks. The TTP and PECS groups exhibited patients with lower pain. Additionally, within the initial hours following surgery, the TTP and PECS groups exhibited a reduced consumption of postoperative morphine.

Arasu T. et al. [17] discovered that patients who underwent combined PECS I and TTP blocks at 0, 3, 6, and 12 hours had a significantly decreased VAS score at rest ( $P < 0.05$ ). Significantly lower VAS scores during deep breathing or coughing were observed in the combined PECS I and TTP blocks group at 0, 6, and 12 hours compared to the PECS I block alone group ( $P < 0.05$ ). This was evidenced by the fivefold increase in the use of first rescue analgesics in the PECS group compared to the combined PECS and TTP blocks group. First rescue analgesics were administered to thirteen patients in PECS I and TTP blocks, but only three patients in group PECS I block alone received the same treatment. The majority of the patients in group P began to require analgesics around the twelfth hour.

A case of achondroplasia was examined by Nakanishi et al. <sup>[18]</sup>, who utilized dexmedetomidine, TTP, and PECS II blocks as sedatives during a sentinel lymph node biopsy and partial mastectomy in the upper portion of the right breast that were conducted in the absence of general anesthesia. There were no reports of severe pain or the requirement for supplementary analgesics within the initial twenty-four hours following the procedure.

Blanco et al. <sup>[19]</sup> established that PECS blocks (types I and II) are peripheral techniques that combine blocks of the sensory and motor nerves; The lack of a sympathetic block reported in their research is consistent with the findings of the current inquiry. Additionally, the effectiveness of multimodal analgesia during breast cancer surgery was investigated by Bashandy et al. <sup>[20]</sup> through the utilization of PECS I and PECS II. PECS block is distinguished from epidural and thoracic paravertebral blocks by its lack of association with sympathetic block; consequently, it provides greater vital stability.

Concerning complications linked to PECS II-TTP blocks, Abo Elamaym, et al. <sup>[21]</sup> documented any such occurrences in order to ascertain their safety during MRM, including hemorrhage, pneumothorax, or LAST. Furthermore, the safety of the PECS block was corroborated by the research conducted by Senapathi et al. <sup>[22]</sup>, wherein they documented no adverse effects including hematoma, pneumothorax, or artery penetration, that were linked to the PECS II block.

### **Conclusions:**

In patients who underwent MRM, combination of TTP-PECS provided better intraoperative and postoperative analgesic control and reduced morphine use.

**Financial support and sponsorship:** Nil

**Conflict of Interest:** Nil

### **References:**

1. Arnold M, Morgan E, Rungay H, Mafra A, Singh D, Laversanne M, et al. Current and future burden of breast cancer: Global statistics for 2020 and 2040. *Breast*. 2022;66:15-23.
2. Salati SA, Alsulaim L, Alharbi MH, Alharbi NH, Alsenaid TM, Alaodah SA, et al. Postmastectomy pain syndrome: A narrative review. *Cureus*. 2023;15:384-92.
3. F Abouelsoued A, A Abd El-mabood E-s, T Yones M, A Waly M. Comparative study between the conventional modified radical mastectomy and modified radical mastectomy with quilting technique to axillary skin flap in reduction of postoperative seroma in surgical management of breast cancer. *Benha j appl sci*. 2024;9:117-23.
4. Deng W, Fu D, He L. Evaluation of pectoral nerve block in modified radical mastectomy: Comparison of three concentrations of ropivacaine. *Clin Interv Aging*. 2020;15:937-44.
5. van Rijbroek LS, Noordergraaf GJ, de Man-van Ginkel JM, van Boekel RL. The association of hemodynamic parameters and clinical demographic variables with acute postoperative pain in female oncological breast surgery patients: A retrospective cohort study. *Scand J Pain*. 2024;24:66-72.
6. Zhang M, Yang L, Hou L, Wang Z, Zhang J. Modified radical mastectomy for level III axillary lymph node clearance: a case report. *Gland Surg*. 2021;10:2880-4.
7. De Cassai A, Geraldini F. Chronic pain and regional anesthesia: A call to action! *J Clin Med*. 2023;12:651-7.
8. Singh NP, Makkar JK, Kuberan A, Guffey R, Uppal V. Efficacy of regional anesthesia techniques for postoperative analgesia in patients undergoing major oncologic breast surgeries: a systematic review and network meta-analysis of randomized controlled trials. *Can J Anaesth*. 2022;69:527-49.

9. Zhao J, Han F, Yang Y, Li H, Li Z. Pectoral nerve block in anesthesia for modified radical mastectomy: A meta-analysis based on randomized controlled trials. *Medicine (Baltimore)*. 2019;98:423-9.
10. Rao F, Wang Z, Chen X, Liu L, Qian B, Guo Y. Ultrasound-guided thoracic paravertebral block enhances the quality of recovery after modified radical mastectomy: A randomized controlled trial. *J Pain Res*. 2021;14:2563-70.
11. Ueshima H, Otake H. Addition of transversus thoracic muscle plane block to pectoral nerves block provides more effective perioperative pain relief than pectoral nerves block alone for breast cancer surgery. *Br J Anaesth*. 2017;118:439-43.
12. Thomas M, Philip FA, Mathew AP, Jagathnath Krishna KM. Intraoperative pectoral nerve block (PEC) for breast cancer surgery: A randomized controlled trial. *J Anaesthesiol Clin Pharmacol*. 2018;34:318-23.
13. Fujii S, Bairagi R, Roche M, Zhou JR. Transversus thoracis muscle plane block. *Biomed Res Int*. 2019;219:365-72.
14. Helmich EJ, Van Den Broek RJ, Bloemen JG. Combined transverse thoracis plane and pectoral nerve blocks for breast surgery under sedation. *Anaesth Rep*. 2021;9:297-307.
15. Bakeer A, Abdallah NM. Erector spinae plane block versus PECS block type II for breast surgery: A randomized controlled trial. *Anesth Pain Med*. 2022;12:917-24.
16. Xie X, Li H, Wang C, Li W, Xie D, Li M, et al. Effect of modified radical mastectomy combined with neo-adjuvant chemotherapy on postoperative recurrence rate, negative emotion, and life quality of patients with breast cancer. *Am J Transl Res*. 2022;14:460-7.
17. Arasu T, Ragavendran S, Nagaraja PS, Singh NG, Vikram MN, Basappanavar VS. Comparison of pectoral Nerve (PECS1) block with combined PECS1 and transversus thoracis muscle (TTM) block in patients undergoing cardiac implantable electronic device insertion - A pilot study. *Ann Card Anaesth*. 2020;23:165-9.
18. Nakanishi T, Yoshimura M, Toriumi T. Pectoral nerve II block, transversus thoracic muscle plane block, and dexmedetomidine for breast surgery in a patient with achondroplasia: a case report. *JA Clin Rep*. 2019;5:47-52.
19. Blanco R, Fajardo M, Parras Maldonado T. Ultrasound description of PECS II (modified PECS I): a novel approach to breast surgery. *Rev Esp Anesthesiol Reanim*. 2012;59:470-5.
20. Bashandy GM, Abbas DN. Pectoral nerves I and II blocks in multimodal analgesia for breast cancer surgery: a randomized clinical trial. *Reg Anesth Pain Med*. 2015;40:68-74.
21. ELAMAYM MAA, OSHITA K, TAGUCHI S, KATO T, HAMADA H, NAbdelmageed O, et al. The analgesic efficacy of pectoral nerve and transversus thoracic muscle plane block in radical mastectomy. *MEJ Anesth*. 2018;25:89-94.
22. Senapathi TGA, Widnyana IMG, Aribawa IGNM, Jaya AGPS, Junaedi IMD. Combined ultrasound-guided PECS II block and general anesthesia are effective for reducing pain from modified radical mastectomy. *J Pain Res*. 2019;48:1353-8.