



# African Journal of Biological Sciences



## Comparative evaluation of Nano-hydrogel containing oleic acid and quercetin versus to hyaluronic acid for the treatment of diabetic foot ulcers: A Focus on clinical efficacy

Seyed Abbas Shahrtash<sup>1</sup>, Thabit Moath Omar<sup>2</sup>, Morug Salih Mahdi<sup>3</sup>, Ali M. Ali Al-Nuaimi<sup>4</sup>, Rouaida Kadhim A\_al-hussein<sup>5</sup>, Mahmood Jasem Jawad<sup>6</sup>, Amirsasan Gorgzadeh<sup>7\*</sup>, Mohammad Hosseini Hooshiar<sup>8\*\*</sup>

1. Department of Pharmaceutical Engineering, University of Tehran, Tehran, Iran

2. Department of Medical Laboratory Technics, College of Health and Medical Technology, Alnoor University, Nineveh, Iraq

3. College of MLT Ahl Al Bayt University, Iraq

4. Gilgamesh Ahliya University, Baghdad, Iraq

5. Collage of Nursing, National University of Science and Technology, Dhi Qar, 64001, Iraq

6. Department of Pharmacy, Al-Zahravi University College, Karbala, Iraq

7. Faculty of Pharmacy, Ahvaz Jundi Shapur University of Medical Sciences, Ahvaz, Iran

8. Department of Periodontics, School of Dentistry, Tehran University of Medical Sciences, Tehran, Iran

\*Corresponding Author: : Amirsasan Gorgzadeh

Faculty of Pharmacy, Ahvaz Jundi Shapur University of Medical Sciences, Ahvaz, Iran

Email: [Amirsasan69@gmail.com](mailto:Amirsasan69@gmail.com)

\*\*Co-Corresponding Author : Mohammad Hosseini Hooshiar

Department of Periodontics, School of Dentistry, Tehran University of Medical Sciences, Tehran, Iran

Email: [Smh.hooshiar@gmail.com](mailto:Smh.hooshiar@gmail.com)

### Abstract

**Background and aim:** In this study, an attempt has been made to investigate the clinical efficacy of nano-hydrogel (0.2%) embedded with oleic acid and quercetin in comparison with the results of nano-hydrogel (0.2%) alone in the treatment of diabetic foot ulcers in diabetes mellitus patients.

**Method:** The current study was a randomized clinical trial study in 200 diabetic patients with diabetic foot ulcers referred to Amir-ol-momenin Hospital in Savad Kuh, Mazandaran, Iran during the years 2021 to 2022 were divided into two intervention groups (nano-hydrogel) by random sampling method and based on the inclusion criteria (0.2%) embedded with oleic acid and quercetin) and control group (hyaluronic acid (2%) alone) were divided (100 patients in each group). Statistical analysis was done with SPSS software version 23. Differences with p-value<0.05 were considered significant. Both groups received topical treatment daily for two months. Follow-up was done every week for six months from the beginning of the study.

**Result:** The mean pain in the intervention group (2.12±0.95) was significantly lower compared to the control group (4.72±1.34) (p<0.01). 64 patients in the intervention group and 31 patients in the control group experienced complete healing with a shorter average time (p>0.05).

**Conclusion:** The present study showed that the use of nano-hydrogel (0.2%) embedded with oleic acid and quercetin can significantly reduce the recovery period compared to nano-hydrogel (0.2%) alone; It also significantly reduced the amount of pain.

**Keywords:** Nano-hydrogel, Diabetes mellitus, Quercetin , Oleic acid, Diabetic foot ulcer

Article History

Volume 6, Issue 13, 2024

Received: 18 June 2024

Accepted: 02 July 2024

doi:10.48047/AFJBS.6.13.2024.2032-2040

## **Introduction**

Despite the medical and surgical advances in the last decade, problems related to the diabetic foot ulcer, which is one of the most important chronic complications of diabetes, still remain as a health problem and include the single biggest risk factor of non-traumatic foot amputations(1). The probability of a diabetic patient suffering from foot lesions (ulcers/gangrene) throughout his life is estimated to be 15-25% with an annual incidence of 1.4-1%, and more than 15% of these wounds will eventually lead to limb amputation(2). The risk of developing a diabetic foot ulcer for the first time increases in patients with a history of diabetes for more than 10 years, men, people with poor blood sugar control and suffering from cardiovascular, kidney and eye diseases(3).

Wound healing progresses in an organized manner and involves four processes; Homeostasis, inflammation, proliferation and remodelling(4). Although the stages of wound healing progress within a certain range, depending on the internal and external conditions of the patient, wounds may worsen or progress(5). Impaired healing of diabetic foot ulcers may be caused by the following: chronic inflammation at the wound site, changes in small vessels, thickening of the capillary basement membrane, favorable wound environment for infection, decreased blood flow, and resulting hypoxia. From that, the reduction of intracellular glucose and the increase of blood sugar in the diabetic wound site may inhibit the xenophagy action of macrophages, and as a result, necrotic and waste materials are not removed from the wound site, and thus new vessels, fibroblasts and food They are reduced in the wound.(6, 7). The documentation shows the great importance of prevention methods and intervention approaches to control and treat diabetic foot ulcers(8-12). So far, various treatment approaches have been reported, which can be referred to as active infection treatment, dressing reinforcement, blood sugar control, wound drainage, and surgical debridement(13). However, today, the use of nano-hydrogels has been able to show promising findings in wound treatment(14). Studies have shown that quercetin can help the wound healing process(15, 16). On the other hand, studies show that oleic acid can play a role in the wound healing process by modulating the immune response(17-19). Therefore, in this study, an attempt has been made to investigate the clinical efficacy of nano-hydrogel (0.2%) embedded with oleic acid and quercetin in comparison with the results of nano-hydrogel (0.2%) alone in the treatment of diabetic foot ulcers in diabetes mellitus patients.

## **Method**

The current study was a randomized clinical trial study in which 200 diabetic patients with diabetic foot ulcers referred to Amir-ol-momenin Hospital in Savad Kuh, Mazandaran, Iran during the years 2021 to 2022 were divided into two intervention groups (nano-hydrogel) by random sampling method and based on the inclusion criteria (0.2%) embedded with oleic acid and quercetin) and control group (hyaluronic acid (2%) alone) were divided (100 patients in each group).

All patients over 18 years of age who had diabetic foot ulcers were included in the study and any sensitivity to flavonoids or nutrients, having other diseases such as cancer, platelet disorders, chronic hepatitis, sepsis and other diseases with severe clinical conditions, mental disorders - Nerve, non-diabetic wound were excluded from the study.

Informed consent was obtained from all the patients participating in the study, the information was clearly explained to the patients in an understandable language, and in case of complete and heartfelt consent, an informed consent was obtained from them. If the patient himself did not understand or did not have sufficient literacy, it was fully explained to his legal representative and his child or first-degree relative, and consent was obtained in their presence and with their approval. The patients included in the study and their companions were fully assured that if any of the patients are not able to continue cooperating in the research, they can be withdrawn from the study at any time and that all treatment measures will be performed for them on time and according to the usual routine, and there will be no interruptions. It is not created in their treatment process. It should be mentioned that in the present study, all patients and doctors did not know the treatment group.

For the intervention group, supplemental treatment was done with the topical formulation of nano-hydrogel (0.2%) + oleic acid + quercetin, and in the control group, the topical formulation of nano-hydrogel (0.2%) was performed alone. In the present study, to reduce the bias, the treatment protocol was given to all patients by one person, and before discharge from the hospital, he was given the same unknown formulation to use at home. All patients were followed up every day to remind them by SMS. Both groups received topical treatment daily for two months. Follow-up was done every week for six months from the beginning of the study. Twelve patients (7 patients in the control group, 5 patients in the intervention group) died during one year of observation, 8 patients (3 patients in the control group, 5 patients in the intervention group) refused to continue the treatment. A total of 20 patients were excluded and 180 patients were examined (90 patients in each group).

Wound healing at the time of entering the study, after discharge and during follow-up was evaluated using direct wound tracking on a transparent plastic sheet followed by computerized polarimetry. Visual Analogue Scale (VAS) was used to evaluate pain. the VAS measures pain intensity. The VAS consists of a 10cm line, with two end points representing 0 ('no pain') and 10 ('pain as bad as it could possibly be'). Ask the patient to rate their current level of pain by placing a mark on the line(20).

Statistical analysis was done with SPSS software version 23. Differences with  $p$ -value $<0.05$  were considered significant. In order to check the normality of the data, the Kolmogorov-Smirnov test was used. Two study groups were examined in terms of demographic variables. Due to the normal distribution of the data, statistical tests of one-way analysis of variance, paired  $t$  and independent  $t$  were also used.

## **Result**

In the current study, the mean age of participants in the intervention and control groups was  $64.84\pm 9.82$  and  $63.18\pm 9.20$ , respectively; According to the independent  $t$ -test, two groups were similar and no significant difference was observed in terms of age ( $p=0.245$ ). 57.8% ( $n=52$ ) and 58.9% ( $n=53$ ) of participants in the intervention and control groups were male, respectively, according to Fisher's exact test, the two groups were similar ( $p=0.88$ ). 46.7% ( $n=42$ ) and 55.6% ( $n=50$ ) in intervention and control groups had comorbid hypertension ( $p=0.233$ ); also 46.7% ( $n=42$ ) and 42.2% ( $n=38$ ) in intervention and control groups had chronic obstructive pulmonary disease ( $p=0.549$ ).

The mean pain in the intervention group ( $2.12\pm 0.95$ ) was significantly lower compared to the control group ( $4.72\pm 1.34$ ) ( $p<0.01$ ) (Fig.1). After one month from the start of the treatment, a statistically significant difference was observed between the two groups in terms of complete healing ( $p<0.05$ ); Thus, 64 patients in the intervention group and 31 patients in the control group experienced complete healing with a shorter average time ( $p>0.05$ ) (Table 1). After two months of follow-up, all patients in the intervention group reported complete healing, while in the control group, after two months, 80% of patients reported complete healing( $p>0.05$ ).

Table 1. Efficacy outcome between Intervention and control group

Variable	Intervention group	Control group	p-value
Complete healing after one months	64 (71.1%)	31 (34.44)	0.007
Time of healing after one months (day)	15.64±3.02	23.41±2.54	0.000
Complete healing after two months	26 (100%)	41 (45.5%)	0.01
Time of healing after two months (day)	32.50±2.24	35.46±2.45	0.000
Complete healing after three months	0	18 (20.1%)	-
Time of healing after three months (day)	-	62.88±1.27	-
local infection	5 (5.6)	14 (15.6)	0.025

VAS: visual analogical scale

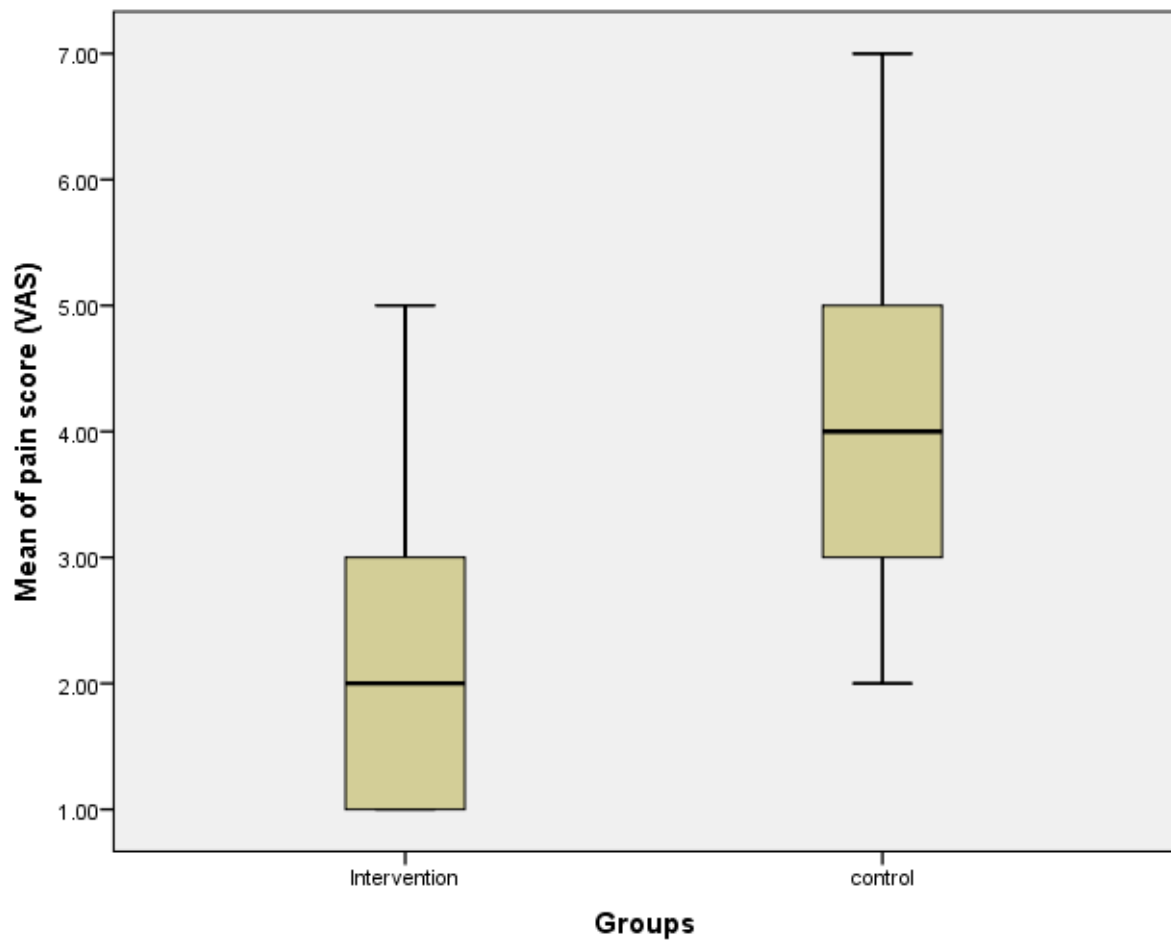


Figure 2. mean of pain score (VAS) in intervention and control group.

14 patients in the control group and 5 patients in the intervention group had a local infection, for which antimicrobial medication was started (Figure 2).

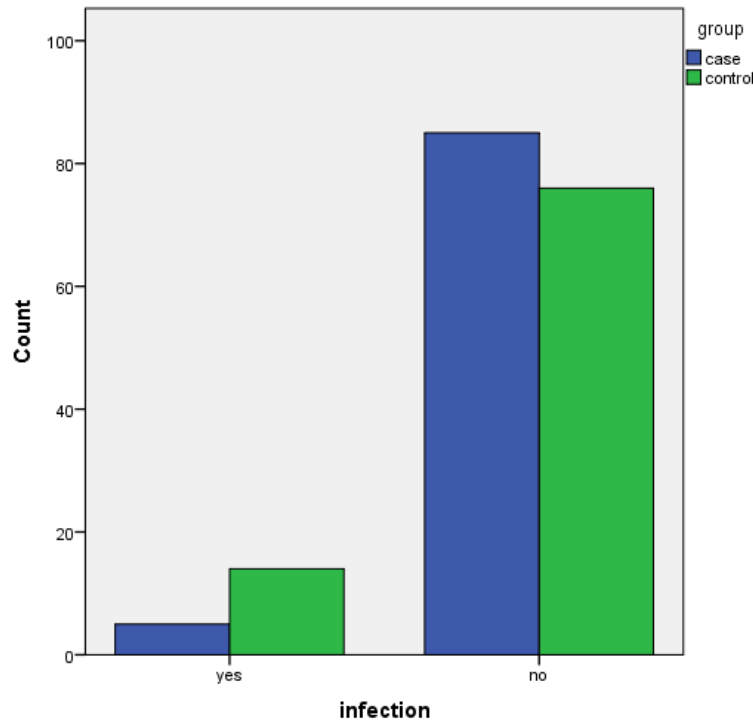


Figure 2. Incidence of local infection in two groups

## Discussion

According to the reports of the International Diabetes Federation, about 9 to 26 million diabetic patients suffer from diabetic foot ulcer every year(21). On the other hand, reports indicate that diabetic foot ulcer increases the death rate by 2.5 times(22). Therefore, the treatment of diabetic foot ulcer is very important. Hydrogel is produced from polymeric compounds of starch and is suitable for wounds with low secretion, and because it causes autolysis of necrotic tissues and slough, it is suitable as an auxiliary treatment in surgical debridement(23).

In the current study, the clinical results of nano-hydrogel (0.2%) embedded with oleic acid and quercetin in diabetic patients with diabetic foot ulcer were compared to nano-hydrogel (0.2%) alone; Oleic acid and quercetin were used in molar concentration. In the present study, the mean time of healing after one month in the group that treatment with nano-hydrogel embedded with quercetin and oleic acid ( $15.64 \pm 3.02$ ) was significantly lower compared to the control group ( $23.41 \pm 2.54$ ). Yong-jun et al., 2013 showed the wound closure time in oleic acid group and control group was ( $17.2 \pm 2.6$ ) d and ( $19.5 \pm 1.9$ ) d respectively ( $P < 0.05$ )(24). Gallelli et al., 2020 reported similar result that nano-hydrogel embedded with

quercetin and oleic acid can reduced the wound healing time(18). A recent study found that curcumin-loaded nanocomposite hydrogels can prolong the local treatment time of curcumin compared with ordinary curcumin hydrogels(25). Other study has found that gelatin microspheres containing curcumin nanoparticles can ensure the stable release of curcumin in the wound surface, significantly improve the antioxidant effect and migration-inducing ability of curcumin and promote skin wound healing of diabetic mice(26). As evidence has shown, keratinocytes contain a set of enzymes that are able to form esters; Oleic acid can modulate the immune response in wound healing and thus restore the acute inflammatory phase. Also, the reduction of pain in the intervention group was significantly higher than the control group. Hyaluronic acid hydrates and modulates the cellular microenvironment and can increase the entry of cells into the wound(27). Previous studies have confirmed that quercetin or oleic acid alone can promote wound healing(26, 28).

Also, the mean pain score was significantly lower in the group receiving the nano-hydrogel embedded with quercetin and oleic acid than control group. These findings show the effect of the nano-hydrogel embedded with quercetin and oleic acid on the feeling of pain reduction in patients. In line with these findings, the study showed that the pain in the group receiving the nano-hydrogel embedded with quercetin and oleic acid in the Italian population was less than the control group(18). Gokhale et al., 2019 showed quercetin loaded nano-emulsion based gel formulation is an effective topical treatment strategy for rheumatoid arthritis(29).

Due to their porous and hydrated molecular structure, hydrogels are one of the candidates that can mimic the skin's biological environment. They can be used as a permanent or temporary dressing for various wounds to regenerate and repair damaged epidermis, dermis or both. Hydrogels can be divided into two main groups, natural and synthetic, based on the materials used to make them. In addition, hydrogels can be reinforced using nanoparticles(27). Hydrogels help heal diabetic wounds by creating a moist environment for wound healing, promoting cell migration and tissue regeneration, and continuous release of therapeutic agents(30). They have a high-water retention ability that conventional bandages do not have, and they mimic the natural environment of the extracellular matrix and provide a suitable environment for cell proliferation. Hydrogels can be easily loaded with drugs or cytokines that specifically target the underlying problems of diabetic ulcers, such as blood sugar control(30). In addition, they can be designed to be stimuli-responsive and multifunctional, exhibiting antibacterial, pro-angiogenic and generally pro-therapeutic effects. In addition, hydrogels can be used as vehicles to carry therapeutic drugs and their unique structural properties do not cause secondary mechanical damage(31).

## Conclusion

Although various advances have been made in the field of leg ulcer treatment, most of these treatments have had relative effects and were complementary to each other, and more effective treatments are needed to treat this condition. The present study showed that the use of nano-hydrogel (0.2%) containing oleic acid and quercetin can significantly reduce the wound healing time and pain compared to nano-hydrogel (0.2%).

## References

1. Aljohary H, Murad MA, Alfkey R. Diabetic Foot Ulcer: A Historical Overview. 2024.
2. Zaki SM, El Karsh DS, Faden TM, Almghamsi LT, Fathaldin JO, Alhazmi OA, et al. Diabetic Foot Complications in Saudi Arabia: A Retrospective Study. *Cureus*. 2024;16(2).
3. Ouyang W, Jia Y, Jin L. Risk factors of diabetic foot ulcer in patients with type 2 diabetes: a retrospective cohort study. *American Journal of Translational Research*. 2021;13(8):9554.
4. Yang F, Bai X, Dai X, Li Y. The biological processes during wound healing. *Regenerative medicine*. 2021;16(04):373-90.
5. Vaidyanathan L. Growth factors in wound healing—a review. *Biomed Pharmacol J*. 2021;14:1469-81.
6. BAKTIR G. Wound repair and experimental wound models. *Experimed*. 2020;9(3):130-7.
7. Abas M, El Masry M, Elgharably H. Collagen in diabetic wound healing. *Wound Healing, Tissue Repair, and Regeneration in Diabetes: Elsevier*; 2020. p. 393-401.
8. Bus SA, Sacco IC, Monteiro- Soares M, Raspovic A, Paton J, Rasmussen A, et al. Guidelines on the prevention of foot ulcers in persons with diabetes (IWGDF 2023 update). *Diabetes/metabolism research and reviews*. 2024;40(3):e3651.
9. Schaper NC, van Netten JJ, Apelqvist J, Bus SA, Hinchliffe RJ, Lipsky BA, et al. Practical guidelines on the prevention and management of diabetic foot disease (IWGDF 2019 update). *Diabetes/metabolism research and reviews*. 2020;36:e3266.
10. Wang A, Lv G, Cheng X, Ma X, Wang W, Gui J, et al. Guidelines on multidisciplinary approaches for the prevention and management of diabetic foot disease (2020 edition). *Burns & trauma*. 2020;8:tkaa017.
11. van Netten JJ, Raspovic A, Lavery LA, Monteiro- Soares M, Paton J, Rasmussen A, et al. Prevention of foot ulcers in persons with diabetes at risk of ulceration: a systematic review and meta- analysis. *Diabetes/metabolism research and reviews*. 2024;40(3):e3652.
12. Miranda C, Da Ros R, Marfella R. Update on prevention of diabetic foot ulcer. *Archives of Medical Science-Atherosclerotic Diseases*. 2021;6(1):123-31.
13. Schaper N, Van Netten JJ, Apelqvist J, Lipsky B, Bakker K, Foot IWGotD. Prevention and management of foot problems in diabetes: a Summary Guidance for Daily Practice 2015, based on the IWGDF Guidance Documents. *Diabetes/metabolism research and reviews*. 2016;32:7-15.
14. Zhang S, Shah SA-u-M, Basharat K, Qamar SA, Raza A, Mohamed A, et al. Silk-based nano-hydrogels for futuristic biomedical applications. *Journal of drug delivery science and technology*. 2022;72:103385.
15. Doersch KM, Newell-Rogers MK. The impact of quercetin on wound healing relates to changes in  $\alpha V$  and  $\beta 1$  integrin expression. *Experimental Biology and Medicine*. 2017;242(14):1424-31.



16. Yin G, Wang Z, Wang Z, Wang X. Topical application of quercetin improves wound healing in pressure ulcer lesions. *Experimental dermatology*. 2018;27(7):779-86.
17. Giulitti F, Petrunaro S, Mandatori S, Tomaipitnca L, De Franchis V, D'Amore A, et al. Anti-tumor effect of oleic acid in hepatocellular carcinoma cell lines via autophagy reduction. *Frontiers in Cell and Developmental Biology*. 2021;9:629182.
18. Gallelli G, Cione E, Serra R, Leo A, Citraro R, Matricardi P, et al. Nano- hydrogel embedded with quercetin and oleic acid as a new formulation in the treatment of diabetic foot ulcer: A pilot study. *International wound journal*. 2020;17(2):485-90.
19. Rodrigues HG, Vinolo MAR, Magdalon J, Vitzel K, Nachbar RT, Pessoa AFM, et al. Oral administration of oleic or linoleic acid accelerates the inflammatory phase of wound healing. *Journal of Investigative Dermatology*. 2012;132(1):208-15.
20. Crichton N. Visual analogue scale (VAS). *J Clin Nurs*. 2001;10(5):706-6.
21. Armstrong DG, Tan T-W, Boulton AJ, Bus SA. Diabetic foot ulcers: a review. *Jama*. 2023;330(1):62-75.
22. Chammas N, Hill R, Edmonds M. Increased mortality in diabetic foot ulcer patients: the significance of ulcer type. *Journal of diabetes research*. 2016;2016.
23. He JJ, McCarthy C, Camci-Unal G. Development of hydrogel- based sprayable wound dressings for second- and third- degree burns. *Advanced nanobiomed research*. 2021;1(6):2100004.
24. Yong-jun Z, Yong F, Wei-rong Y. Effects of topical application of oleic acid on wound healing in diabetic mice. *JOURNAL OF SHANGHAI JIAOTONG UNIVERSITY (MEDICAL SCIENCE)*. 2013;33(5):619.
25. Kamar SS, Abdel-Kader DH, Rashed LA. Beneficial effect of Curcumin Nanoparticles-Hydrogel on excisional skin wound healing in type-I diabetic rat: Histological and immunohistochemical studies. *Annals of Anatomy-Anatomischer Anzeiger*. 2019;222:94-102.
26. Liu J, Chen Z, Wang J, Li R, Li T, Chang M, et al. Encapsulation of curcumin nanoparticles with MMP9-responsive and thermos-sensitive hydrogel improves diabetic wound healing. *ACS Applied Materials & Interfaces*. 2018;10(19):16315-26.
27. Cervelli V, De Angelis B, Lucarini L, Spallone D, Balzani A, Palla L, et al. Tissue regeneration in loss of substance on the lower limbs through use of platelet-rich plasma, stem cells from adipose tissue, and hyaluronic acid. *Advances in skin & wound care*. 2010;23(6):262-72.
28. Jangde R, Srivastava S, Singh MR, Singh D. In vitro and In vivo characterization of quercetin loaded multiphase hydrogel for wound healing application. *International journal of biological macromolecules*. 2018;115:1211-7.
29. Gokhale JP, Mahajan HS, Surana SJ. Quercetin loaded nanoemulsion-based gel for rheumatoid arthritis: In vivo and in vitro studies. *Biomedicine & Pharmacotherapy*. 2019;112:108622.
30. Gao D, Zhang Y, Bowers DT, Liu W, Ma M. Functional hydrogels for diabetic wound management. *APL bioengineering*. 2021;5(3).
31. Chen J, He J, Yang Y, Qiao L, Hu J, Zhang J, et al. Antibacterial adhesive self-healing hydrogels to promote diabetic wound healing. *Acta biomaterialia*. 2022;146:119-30.