



African Journal of Biological Sciences



MANAGEMENT OF SUB-GINGIVALLY FRACTURED TEETH -A MULTIDISCIPLINARY APPROACH

Dr. C M Anitha, MDS^{1*}, Dr. Prakash PSG MDS², Dr. K. Palaiyatharasi MDS³, Dr. Santosh Venkadassalopathy MDS⁴, Dr. Akshaya J MDS⁵, Dr. D. J. Victor MDS⁶,

1. Assistant Professor, SRM Dental College, Bharathi Salai, Ramapuram, Chennai, 2. Professor, SRM Dental College, Bharathi Salai, Ramapuram, Chennai, 3. Assistant Professor Government Nammakkal Medical College, Chennai, Tamil Nadu, India, 4. Associate Professor, SRM Dental College, Bharathi Salai, Ramapuram, Chennai, 5. Post Graduate student, SRM Dental College, Bharathi Salai, Ramapuram, Chennai, 6. Professor and Head, SRM Dental College, Bharathi Salai, Ramapuram, Chennai.

* Corresponding Author

INTRODUCTION:

Subgingival fracture is the fracture of tooth below the gingival attachment or the alveolar crest level. According to Ellis and Davis classification class 6, 7, 8, can be sorted as subgingival fractures and similarly according to **Andreasen's classification** these fractures involve class V (uncomplicated crown-root fracture) class VI (complicated crown-root fracture) and class VII (root fracture). Tooth fracture is regarded as the third most common cause of tooth loss, commonly occurring in the anterior teeth, in both young and adult patient with trauma being the commonest cause [1].

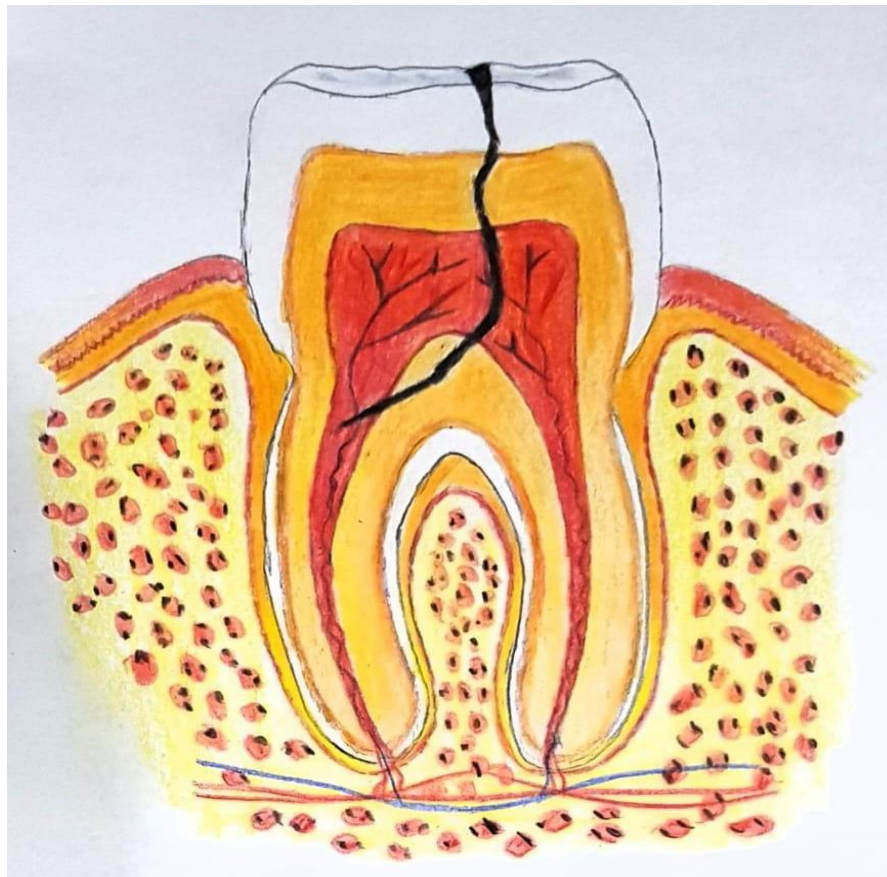


FIG 1: Figure shows the Class V(crown and root) subgingival root fracture.

Management of subgingival fracture is a significant challenge to the clinician as it creates some most demanding situations

It is indispensable to approach the management by interdisciplinary or a multidisciplinary strategy which involves orthodontic, periodontic, endodontic and prosthetic therapies in combinations, to out-turn more esthetic and enduring results.^[1]

CLASSIFICATION OF SGTF:

Teeth with subgingival fractures may be classified into :(G. S. Heithersay et.al.)^[2]

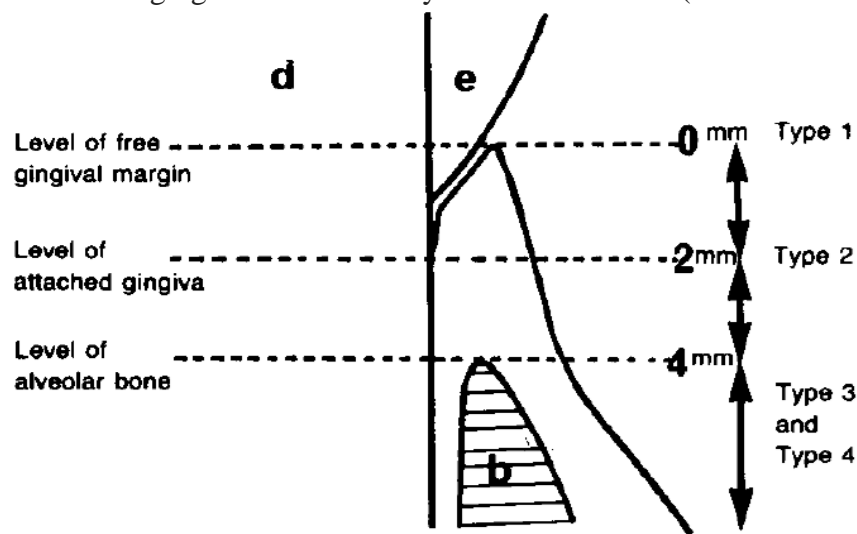


FIG 2: Figure shows the Type 1, Type 2 and Type 3 subgingival fractures Given by Heithersay et al.

Type 1: Teeth with subgingival fractures, where no portion of the fracture line extend below the level of the attached gingiva (1 to 2 mm).

Type 2: Teeth with subgingival fracture where a portion of the fracture line extends below the level of the attached gingiva, but does not extend below the level of the alveolar crest (2 to 4 mm).

Type 3: Teeth with subgingival fractures where a portion of the fracture line extends below the level of the alveolar crest (more than 4 mm)

Type 4: Teeth with root fractures where the fracture line is within the coronal one-third of the root and totally below the level of the alveolar crest.^[3]

ASSESSMENT OF SGTF:

Accurate assessment of Subgingival fracture is a key to successful management of the fracture. Further assessment of adjacent soft tissue lacerations should also be done for proper diagnosis and treatment plan. The factors to be considered are the pulpal/periodontal damage, injury to the adjacent teeth, injury to the supporting bone, position, direction and extent of fracture, stage of tooth development, degree of tooth eruption, the degree of tooth displacement, and the presence of remaining tooth structure.

The various tools for assessment includes

- Magnification loupes,
- Fibre optic illumination, and
- RVG.

INTENT OF MANAGEMENT:

- Subgingival fractures entail a scenario which compromises the biological width. Hence re-establishment of lost biological width is a prime necessity.
- Loss of tooth must be averted and restoration of form and function of the teeth must be assured, giving prime significance to gingival portion of attachment apparatus.
- Exposure of sound supragingival structure with ensurement in management of fractured tooth with moisture and bleeding controlled.

TREATMENT PHASES:

PHASE 1: Endodontic Root Canal Treatment and periodontal basal therapy.

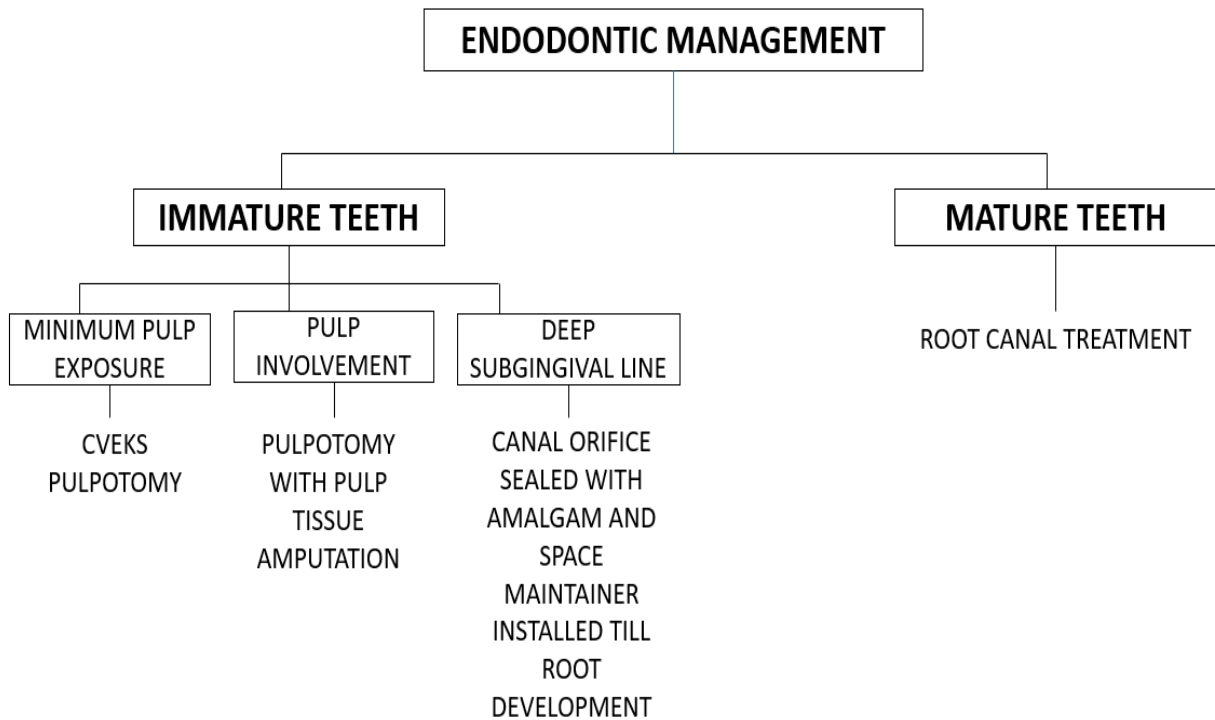
PHASE 2: Orthodontic extrusions.

PHASE 3: Periodontal crown lengthening surgeries.

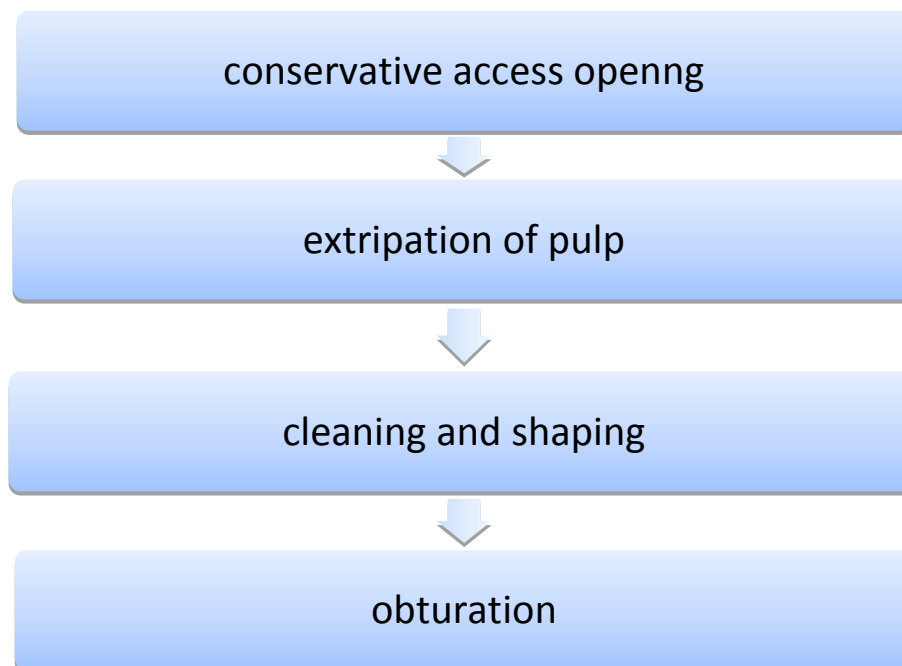
PHASE 4: Prosthodontic restorations and follow-up prosthetics^[4,5]

ENDODONTIC STRATEGIES EMPLOYED:

The primary treatment to be carried out before proceeding to any other stages of treatment.



The fractured tooth is endodontically managed with a



These procedures are done once the fracture-line is determined. Endodontic management carried out must be impeccable, so that it doesn't influence the future procedures. Failures in

this level of management may withhold higher level of culpability for failure of fracture management.

CLINICAL SITUATION	OPTIONS FOR RESTORATIVE TREATMENT
Defect accessible(possibly after using simple measures such as <u>electrotomy</u>)	OPTION 1: restorative treatment of the whole defect
Defect not accessible	<p>OPTION 1: Restorative treatment of the accessible regions(MOSTLY SUPRAGINGIVAL).</p> <p>OPTION 2: Denudation of the fracture site/surgical crown lengthening + restoration.</p> <p>OPTION 3: Orthodontic extrusion of the apical fragment(forced eruption)+ restoration.</p> <p>OPTION 4: Orthodontic extrusion of the apical fragment(forced eruption) + restoration.</p> <p>OPTION 5: Surgical extrusion (intra-alveolar transplantation) + restoration.</p>
Tooth cannot be restored	OPTION 6: Extraction

ROLE OF ORTHODONTIC MANAGEMENT:

Re-establishment of lost biological width and exposing the subgingival fracture line are two crucial objectives in tooth fracture management. Orthodontic extrusion, introduced by Heithersey in 1973, plays a notable part in this, by promoting coronal tooth movement which is effectuated by low intensity and continuous force with periodic management thereby seeding changes on bone and soft tissue.

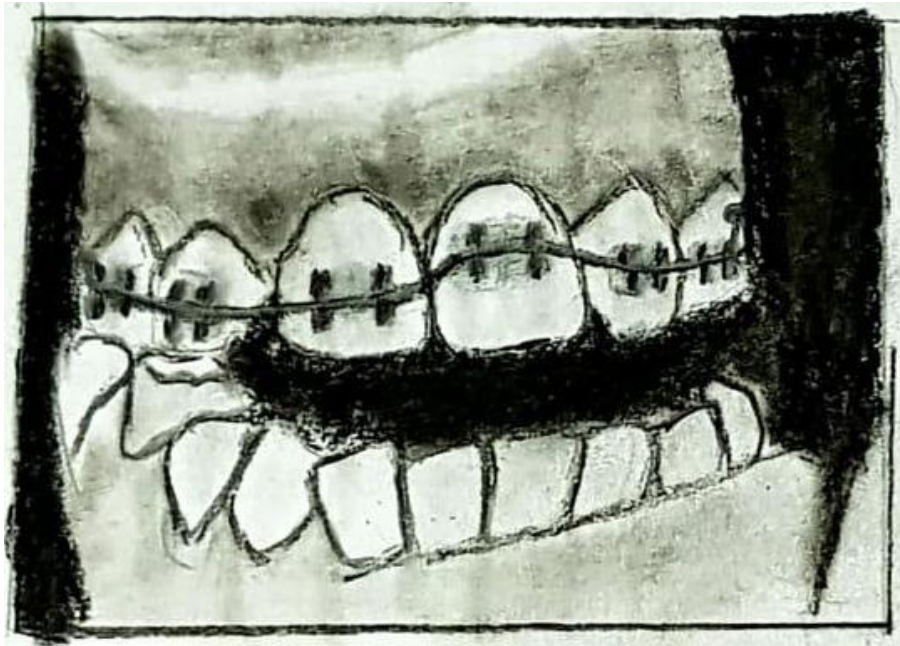


FIG: 3 This figure explains the Orthodontic extrusion for the management of subgingival tooth fracture.

A force of 0.2-0.3 N is required for extrusion of single-rooted tooth with 2-4 mm movement for central incisor and 4-6 mm for lateral incisor.^[6,7] . Biologic width re-alignment is required to obtain proper gingival and crestal bone contour. The 3-4 mm distance from the alveolar crest to the coronal extension of the remaining tooth structure has been recommended for optimal periodontal health.^[8]

Adjunctive orthodontic root extrusion and root separation show better treatment prognosis in endo-perio cases. The primacy of orthodontic management concerns to its conservative approach in presenting the natural tooth besides maintaining the periodontal architecture.

Low intensity and continuous force leads to reorganisation of PDL fibres, but the rapid activations and strong tractions exhibits robust effects on PDL leading to gingival inflammation, post treatment relapse and root resorption.

The conclusive denouement of the orthodontic treatment should intend in procuring the crown-root ratio of at least 1:1 ratio.(The prosthetic concept of crown to root ratio a review of literature)^[9]

MAGNETS FOR ORTHODONTIC EXTRUSION OF CROWN-ROOT FRACTURED TEETH:

Orthodontic magnets have elicited promising results for intrusion of posteriors ,extrusion of impacted teeth and various other treatment modalities.(The use of magnets in orthodontics review Narendra Sharma, 2 Sunita Shrivastav, 3 RH Kamble, 4 Preethi Sharma)Predicting the magnetic force level is of great ease. Magnets have shown maximum force potential at very short distance between them^[10]

The magnetic force increases by 4 to 0mm .They replaced the need for guided auxiliaries with no friction implication.Magnetic force combined with removable appliance have given

good results for extrusion of roots after crown-root fractures. Biologically sound for soft tissues as studies showed no evidence of soft tissue dehiscence, root mobility/response.^[10]

ADVANTAGES OF MAGNETIC SYSTEM:

- Control over the force of the magnets
- Force level can be calculated.
- Axial force direction was optimum for required movement.
- Adjustment in positions were easy to make .
- Easier oral hygiene
- Comfortable with good esthetics

DISADVANTAGES:

- Excavation of root dentin for placement of root magnets.
- Early Corrosion

PERIODONTAL APPROACH:

Corrective periodontal surgical procedure is executed to surge the crown length and to establish the lost biological width. Gingivectomy is the procedure of choice done to maintain the gingival contour and fibrotomy (percision) of stretched PDL fibres was performed to avoid relapse after extrusion. This allows the fibres to heal and re-organize in the new position of root.

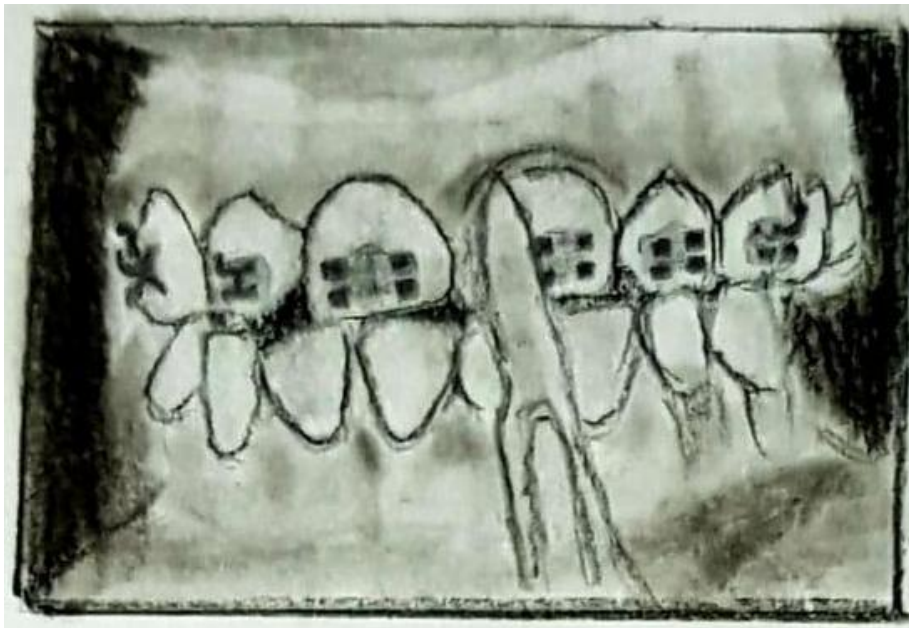


FIG 4: Gingivectomy done for management for subgingival root fractures.

Clinical crown of the tooth is that the distance from gingival margin to incisal edge or occlusal surface of the tooth.(stoma) A short clinical crown is the tooth with less than 2 mm of sound, opposing parallel walls remaining after occlusal and axial reduction.

“Clinical crown lengthening is defined as a surgical procedure that aims at exposing sound tooth structure for restorative purposes via apical repositioning of the gingival tissue with or without removal of alveolar bone”- (AAP Glossary of Terms 2001).^[11] This definition applies to those, grouped as “restorative” or “functional” crown lengthening while “esthetic” crown lengthening refers to indications, subjected to esthetic surgery within the anterior sextants.

But in some instances osteotomy is also performed to optimize esthetic results and biological width.

Based on the level of fracture, the treatment option varies depending on the gingival condition and soft tissue compromise

LEVEL OF FRACTURE LINE	GINGIVAL CONDITION	CROWN MARGIN	REPOSITIONING	OTHER
Level not extending below the level of attached gingiva	compromised	Slightly subgingival	Can be done using surgical or electrocautery methods	
Fracture line extending into attached gingiva but not below the level of crestal bone	Accept the gingival condition	Margin extending into the defect (OR) Fabricating crown on a post and core with a false shoulder which fills the defect	Lower the margins by gingivoplasty or periodontal flap	
Fracture line extends below the level of alveolar bone	Accept the gingival condition		Lower gingival margin by periodontal surgery	Orthodontic extrusion Surgical repositioning

Treatment planning of teeth with root fractures where the fracture line is totally below the level of the alveolar crest but within the coronal one-third of the root depends upon an accurate assessment of the position of the fracture line in relation to the gingival crest. If there is no communication between the fracture line and the gingival sulcus, and if the tooth can be successfully stabilized in the arch, then repair may occur.

This may be in the form of one of the following:

- (a) healing with calcified tissue;
- (b) interposition of fibrous connective tissue;
- (c) interposition of bone and fibrous connective tissue

2. If there is any communication between the fracture site and the gingival sulcus, initially or as a result of coronal instability, repair will not occur and the tooth should be treated by immediate endodontic therapy and orthodontic extrusion, providing there is sufficient length to support a post and crown. If this is not possible either the entire tooth or the coronal segment should be extracted. Retention of the apical portion in some cases could aid in maintaining bony contour required for a satisfactory bridge replacement.

USE OF DIODE LASERS FOR GINGIVECTOMY:

Use of conventional surgical instruments for Gingivectomy ends in excessive bleeding. Hence diode lasers are employed replacing the conventional ones for the improved moisture and bleeding control, in addition they ameliorated the healing process.

PRECISION also can exhibit the same benefits with lasers. - John R Christensen^[12]

PROSTHETIC REPLACEMENTS FOR RESTORATION:

Gingivectomy is trailed by cast post placements which in turn are followed by crown restorations. The final restoration can be done by using CAD/CAM fabricated one-piece milled zirconia post and core with a full coverage zirconia according to the studies given by Rahul Kumar and Suvarna Patil.

ALTERNATIVE MANAGEMENT STRATEGIES :

- Intra alveolar transplantation
- Fragment reattachment

INTRA-ALVEOLAR TRANSPLANTATION:

This involves slight luxation of teeth with minimal damage to surrounding tissues and moving it until the fracture is accessible followed by splinting .This is employed when fracture line cannot be even accessed by orthodontic movement^[13]

FRAGMENT REATTACHMENT:

This is favourable when the fracture fragment is intact and available. The pulp space is thus utilised for retaining the fragment by insertion of dentin bonding post. This conservative method is gaining wide acceptance over artificial replacement on long acting aesthetics and ease of procedure added up by being cost effective and minimal chair time.^[14]

Adhesive reattachment of the coronal fragment

CONCLUSION:

Planned utilization of multidisciplinary approach along with careful evaluation of case is highly significant to achieve the best possible outcome with satisfactory oral health. Recent advances in the field of dentistry helps us to identify and the treat the cases in

REFERENCES:

1. Chole D, Megeri N, Chitte V, Kore P. Management of sub-gingival fractured teeth by multi-disciplinary approach: endodontics–forced orthodontic extrusion and prosthetic rehabilitation: a case report. *Int J Contemp Med Res.* 2016;3:1198-200.
2. Heithersay GS. Combined endodontic-orthodontic treatment of transverse root fractures in the region of the alveolar crest. *Oral Surg Oral Med Oral Pathol* 1973; 36: 404-15.
3. Heithersay GS, Moule AJ. Anterior subgingival fractures: a review of treatment alternatives. *Australian dental journal.* 1982 Dec;27(6):368-76.
4. Nair KR, Das AN, Kuriakose MC, Krishnankutty N. Management of crown root fracture by interdisciplinary approach. *Case Reports in Dentistry.* 2013 Sep 26;2013.
5. Singh N, Chaturvedi TP, Wang CK. Management of subgingival fractured tooth. *Journal of the International Clinical Dental Research Organization.* 2019 Jul 1;11(2):101.
6. Orthodontic Extrusion of Subgingivally Fractured Incisor and Prosthetic Rehabilitation: A Case Report. Ragheeba Ansari¹, Swatantra Agarwal², Abroo Hussain¹, Dipti Nayak¹ *Chronicles of Dental Research, June 2019, Vol 8, Issue 1*
7. Andreasen JO, Andreasen FM *Textbook and Color Atlas of Traumatic Injuries to the Teeth.* 2007 4th Oxford Blackwell:325–8
8. Potashnick SR, Rosenberg ES. Forced eruption: Principles in periodontics and restorative dentistry. *J Prosthet Dent.* 1982;48:141–8
9. Grossmann Y, Sadan A. The prosthodontic concept of crown-to-root ratio: a review of the literature. *J Prosthet Dent.* 2005 Jun;93(6):559-62.
10. Bondemark L, Kurol J, Hallonsten AL, Andreasen JO. Attractive magnets for orthodontic extrusion of crown-root fractured teeth. *American journal of orthodontics and dentofacial orthopedics.* 1997 Aug 1;112(2):187-93.
11. Management of Subgingival Fractured Tooth Nidhi Singh, TP Chaturvedi¹, Chi Koy Wang² *Int Clin Dent Res Organ* 2019;11:101-5.
12. Christensen GJ, Gilmore HW, Guyer SE, Lefkowitz W, Malone WF, McDonald FL, Davis SS, Whitbeck P. Periodontal surgery as an aid to restoring fractured teeth. *The Journal of Prosthetic Dentistry.* 1982 Apr 1;47(4):366-72.

Dr. C M Anitha /Afr.J.Bio.Sc. 6(5)(2024).10393-10404

13.Kahnberg KE, Warfvinge J, Birgersson B. Intraalveolar transplantation. (I). The use of autologous bone transplants in the periapical region. Int J Oral Surg. 1982 Dec;11(6):372-9.

14.Chaugule V, Bhat C, Patil V, Mithiborwala SH. Reattachment of a vertical complicated subgingival crown root fracture in a 10-year old child: A case report. International Journal of clinical pediatric dentistry. 2009 Sep;2(3):53.