



CASE REPORT

Digital Esthetic rehabilitation using Porcelain Veneered Zirconia: A clinical case report

¹Dr. Pardeep Bansal, ²Dr. Preetika Bansal, ³Dr. Ritika, ⁴Dr. Keerti, ⁵Dr. Etaria

¹Professor & Head, ^{3,4,5}Post-Graduate, Department of Prosthodontics, Dasmesh Institute of Research & Dental Sciences, Faridkot, Punjab, India

²Professor, Department of Periodontics, Dasmesh Institute of Research & Dental Sciences, Faridkot, Punjab, India

Corresponding Author: Dr. Pardeep Bansal, Professor & Head, Department of Prosthodontics, Dasmesh Institute of Research & Dental Sciences, Faridkot, Punjab, India

Email: drpardeepbansal77@gmail.com

Article History

Volume 6, Issue Si2, 2024

Received: 26 Feb 2024

Accepted : 02 Apr 2024

doi: 10.33472/AFJBS.6.Si2.2024.324-330

ABSTRACT

Restoring previously treated teeth in the anterior region presents an esthetic challenge in fixed restorations and is eventually a failure if a patient is not completely satisfied. However, digital clinical workflow and advancements in tooth-colored esthetic crown materials have revolutionized the clinical workflow. Accurate decision-making, choice of ceramic system, shade selection, and appropriate laboratory communication are factors for long-term success. This paper aims to present a clinical case with existing porcelain fused to metal restorations (PFM) on anterior maxillary and mandibular teeth replaced by porcelain veneered zirconia restorations using digital means.

Keywords: Ceramic System; Shade Selection; Porcelain Fused to Metal; Porcelain Veneered Zirconia

INTRODUCTION

An optimal functional and esthetic prosthodontic rehabilitation requires meticulous treatment planning and appropriate material selection to ensure predictable and long-lasting clinical results. Prosthodontists face challenges when it comes to anterior esthetic rehabilitation, particularly when old, unesthetic restorations have already been placed and the tooth structure is compromised. However, digital clinical workflow and advancements in tooth-colored esthetic crown materials have revolutionized the clinical workflow.

The demand for esthetics in dentistry has resulted in a wide variety of ceramic, composite, and porcelain restorative materials available for dental restorations. There is no perfect material for every case, and the final selection of the material depends on factors unique to each patient. The presence of distinct phases in the ceramic composition, along with different manufacturing processes has provided dentists with an array of restorative materials to

choose from. Broadly, dental ceramics could be classified as glassy ceramics, resin matrix ceramics, and polycrystalline ceramics. (Alireza Moshaverinia, 2020).

Zirconium dioxide (zirconia) is a polycrystalline ceramic with high toughness, strength, and fatigue resistance. It has become a topic of great interest in the field of prosthodontics for both its mechanical properties, being similar to those of metal, and its color, similar to tooth color. Zirconia-based restorations are an excellent choice for both anterior and posterior tooth replacement as well as implant prostheses and are often covered with layers of veneering porcelain to conceal the opaque nature of the zirconia core that enhances its optical properties.

On the other hand, dentists are increasingly inclined to use digital intraoral scanning instead of making traditional impressions because of several drawbacks associated with these methods, such as patient discomfort, increased chances of errors in impression making, poor patient tolerance, need for impression retakes, etc. Digital intraoral scanning allows the direct transformation of the scanned information of the intraoral dentition to a digital dental model. This method reduces the steps of making impressions and models, avoids the influence of human operation and materials on accuracy, and avoids errors in making, transferring, and pouring plaster models.

This paper aims to present a clinical case with existing porcelain fused to metal restorations on anterior maxillary and mandibular teeth replaced by porcelain veneered zirconia restorations using digital means. It fulfills the functional and esthetic desires of the patients by following a comprehensive minimally invasive prosthetic treatment approach.

CASE REPORT

A 35-year-old male patient reported to the Department of Prosthodontics, Crown and Bridge, and Oral Implantology at Dasmesh Institute of Research and Dental Sciences, Faridkot, with the chief complaint of replacing existing fixed dental prostheses in the upper and lower front teeth region. The patient gave a history of unpleasing maxillary mandibular anterior teeth that had been restored ten years ago with porcelain fused to metal restorations.

Intra-oral examination showed fixed dental restorations from 14 to 24 and from 34 to 46 with generalized marginal gingival inflammation. The patient was also diagnosed as partially edentulous with respect to 17, 36, 37, and 47. Radiographic examination revealed an erupting 18, endodontically treated 46, and the rest of all teeth were vital. Multiunit fixed dental prostheses can be seen on orthopantomogram from 14 to 24 and 34 to 44, and separate two-unit fixed prostheses on 35 and 36 (Figure 1).

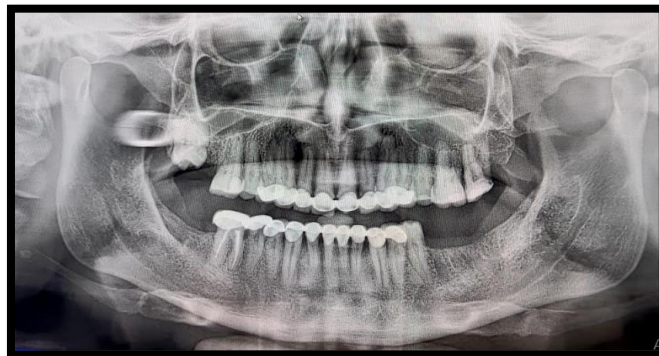

FIGURE 1- ORTHOPANTOMOGRAM REMOVAL OF PFM BRIDGE

The patient only wanted to replace the fixed dental prostheses from the maxillary and mandibular first premolar to the first premolar region and did not want any other treatment. Considering the patient's age and his awareness of the latest available restorative materials, zirconia was chosen to restore all the prepared teeth to fulfill the patient's esthetic and

functional demands. Thus, the final treatment plan for this patient included the removal of the previously placed porcelain fused to metal bridge from 14 to 24 and 34 to 44, refining the preparations, and fabrication of zirconia crowns for all the involved teeth.

Fixed dental prostheses were removed in both upper and lower arches according to the treatment plan (Figure 2) and, the patient was referred for complete oral prophylaxis.

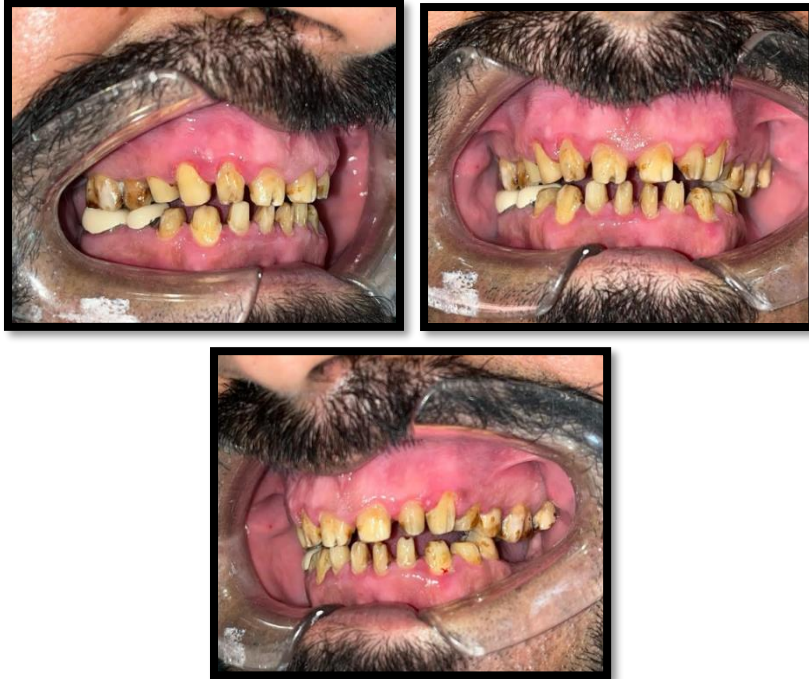

FIGURE 2- INTRAORAL VIEWS AFTER REMOVAL OF PFM BRIDGE

Subsequently, maxillary and mandibular arch scans were made using an intraoral scanning device (Medit i700), and the scanned data obtained was exported electronically to the digital lab using Exocad DentalCAD software (Figure 3).

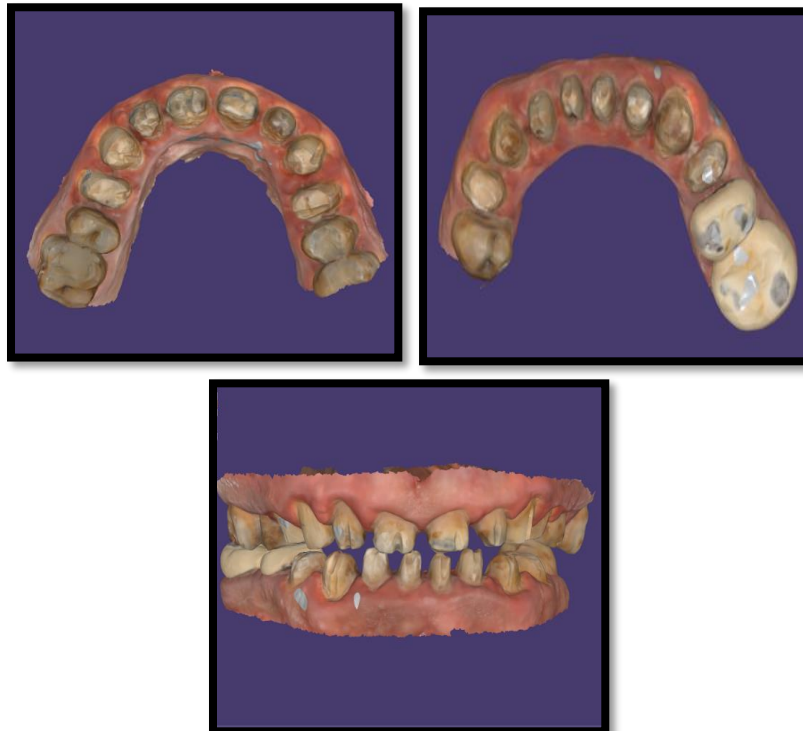

FIGURE 3- JAW SCANS

Exocad software defines gingival margins automatically which can be adjusted manually (Figure 4). It also provides tools to adjust the restoration design, including the occlusal and interproximal occlusal contact points.

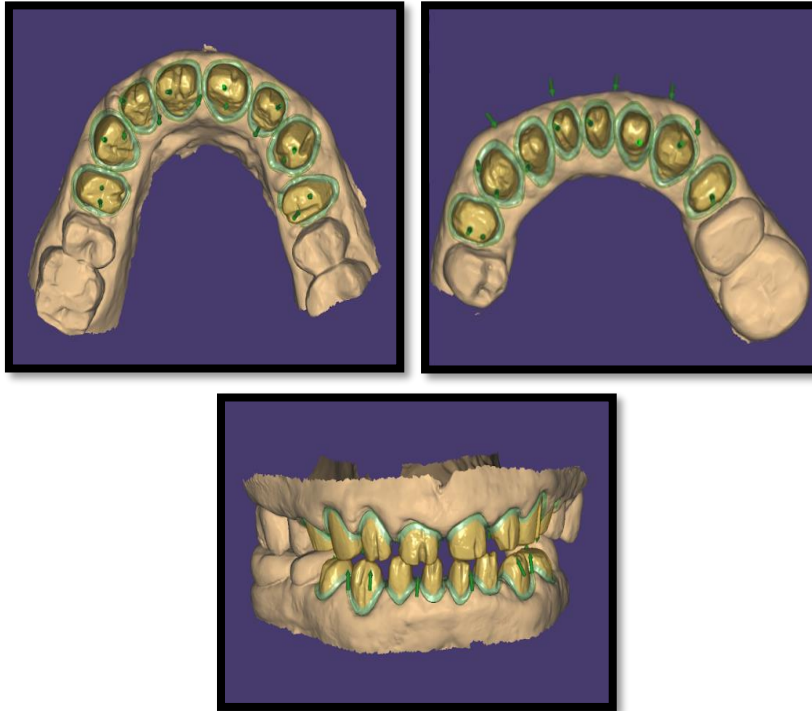


FIGURE 4- FINALIZING GINGIVAL MARGINS

The final data was fed with the milling machine using the same design software and sixteen zirconia copings of 2M2 shade were milled. Zirconia coping try-in was done in the patient's mouth and checked for marginal fit and any occlusal interference (Figure 5).

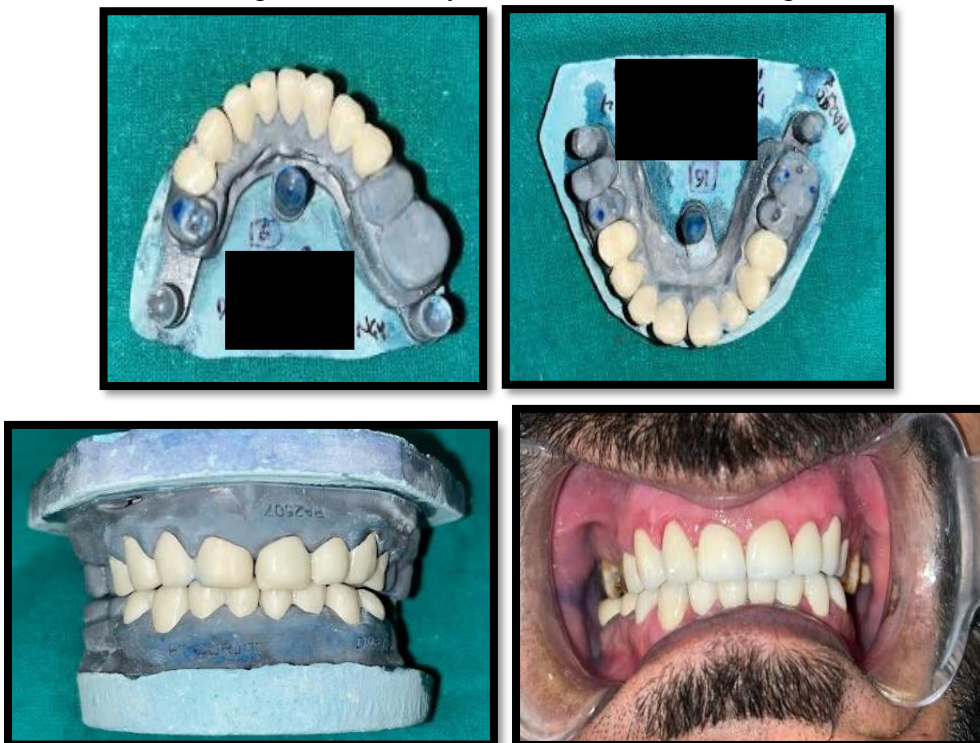


FIGURE 5- COPING TRIAL

Dr. A. PRAKASH/ Afr.J.Bio.Sc. 6(Si2) (2024) 324-330

After the coping trial was done, the porcelain layers were added to the zirconia coping. On the final visit, the occlusal evaluation was done in centric and eccentric positions and all sixteen zirconia crowns were cemented with resin-modified glass ionomer cement following proper bonding procedures. (Figure 6)

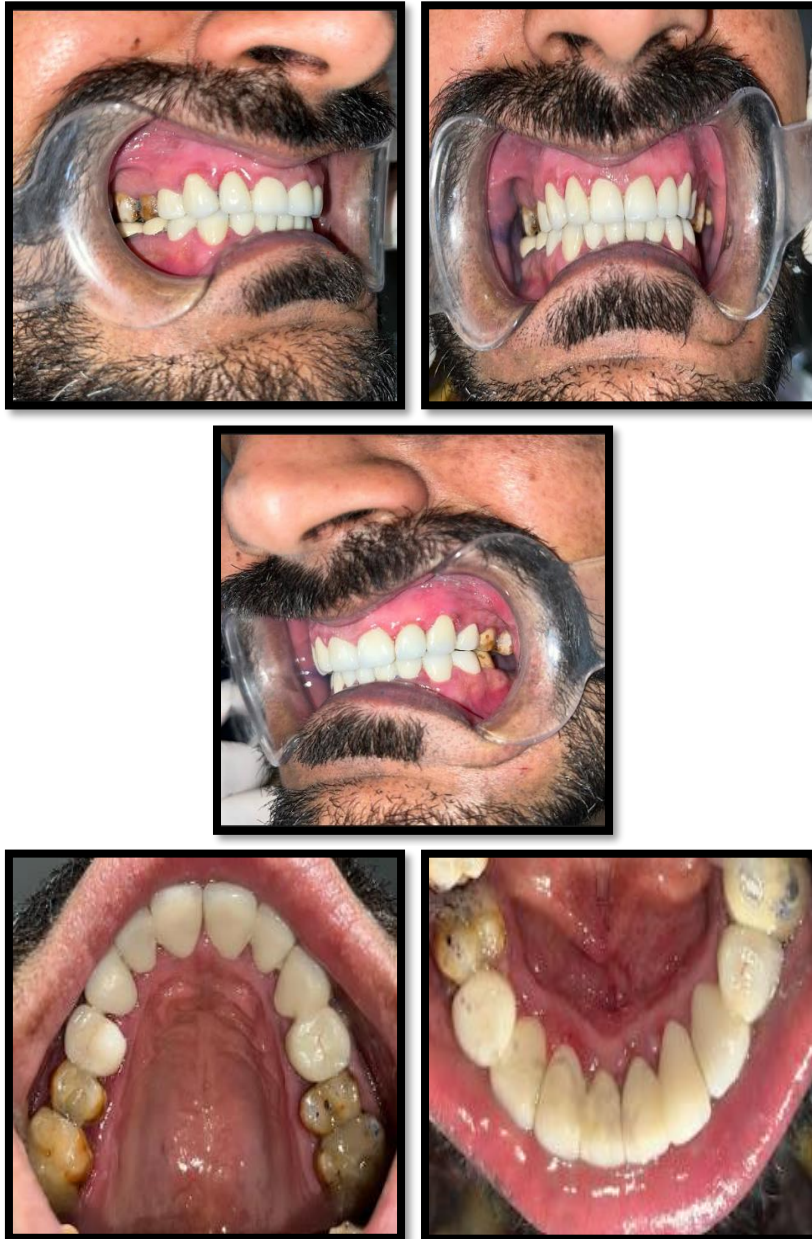

FIGURE 6- FINAL CEMENTATION

The patient was extremely happy and highly satisfied with the final esthetic natural-looking result as per the patient's demand. The patient was recalled for subsequent follow-up visits.(Figure 7)

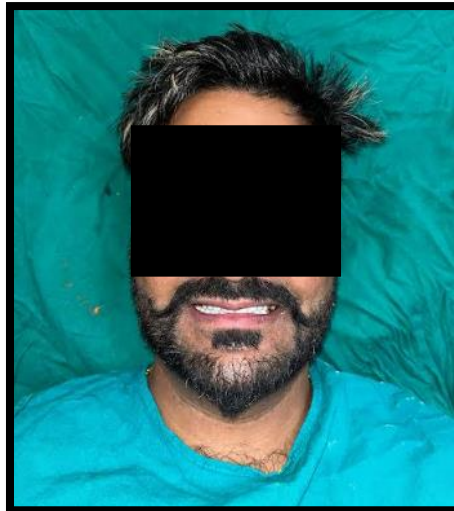

FIGURE 7- POST-OPERATIVE

DISCUSSION

The transitioning dental care requirements, the technological evolution, and the progress in dental materials in the past few years have promoted the increasing use of rapid and convenient digital clinical workflows over conventional materials & technology. Digital clinical workflows have an established record of clinical success and compatibility with human tissues and support high-performance restoration arrangements in today's practice.

Compared with traditional methods, digital intraoral scanning technology has the advantages of rapid speed, high precision, instant ability to repeat impressions, and patient comfort. But, with the numerous benefits of digital impressions, a few drawbacks such as the high investment cost of intraoral scanners, difficulty in detecting subgingival prepared margins of teeth, inherent learning curve, etc. should also be noted.

Various options have been tried over the years to provide full coverage restoration for anterior teeth, each with its own advantages and limitations related to technical, functional, or esthetic aspects. Porcelain fused to metal is one of the strongest materials and most resistant to fracture out of all the options for esthetic rehabilitation. However, it lacks the superior esthetics of all ceramic crowns and may cause gingival inflammation and wear on opposing teeth. All Ceramic crowns have excellent esthetic appearance but are not as durable as PFM crowns and, can weaken the tooth a little more than metal or resin crowns.

The reason for choosing porcelain-veneered zirconia-based restorations in this patient was the high fracture toughness of the ceramic framework, esthetic characteristics, biocompatibility, and durability. They also show increased abrasion resistance, thermal stability, color stability, appropriate translucency, and excellent tissue response due to minimal plaque accumulation.

Kelly et al. (1996) stated that core translucency is regarded as the main element influencing aesthetics and a crucial component in choosing restorative material. The zirconia core's low translucency makes it ideal for discolored teeth since it prevents light transmission through the abutment tooth and masks its intrinsic coloration like metallic frameworks. Thus, the high refractive index of zirconia is another reason for selecting it as the restorative material in this case, as the patient had dark abutment teeth in the aesthetic zone.

In such cases, the use of silica glass based all ceramic crowns is not recommended because they are translucent. It arises from the fact that with an equal thickness, the most translucent zirconia is only 73% translucent as conventional lithium disilicate [**Steven M. Morgano (2014)**]. Zirconia was considered an alternative solution because of its enhanced aesthetics and mechanical properties. The use of resin-modified glass ionomer cement for luting further results in improved strength of the restoration.

However, porcelain veneered zirconia has some common complications like cracking, chipping [Elie E. Daou (2014); Maren Teichmann et al (2018)], and fracture of the veneering porcelain material. Therefore, when planning esthetic rehabilitation, the clinician should aim to replicate natural teeth in shade and translucency and improve their altered mechanical properties.

CONCLUSION

Restoring previously treated teeth in the anterior region presents an esthetic challenge in fixed restorations and is eventually a failure if a patient is not completely satisfied. So, considering the patient's perception of esthetics becomes even more significant. Accurate decision-making, choice of ceramic system, shade selection, and appropriate laboratory communication are factors for long-term success. The treatment described in this case report is simple and effective and represents a promising alternative for anterior esthetic rehabilitation.

REFERENCES

1. Kelly, J.R., 1997. Ceramics in restorative and prosthetic dentistry. *Annual Review of Materials Science*, 27(1), pp.443-468.
2. Soares, C.J., Fonseca, R.B., Martins, L.R.M. and Giannini, M., 2002. Esthetic rehabilitation of anterior teeth affected by enamel hypoplasia: a case report. *Journal of esthetic and restorative dentistry*, 14(6), pp.340-348.
3. Raut, A., Rao, P.L. and Ravindranath, T., 2011. Zirconium for esthetic rehabilitation: an overview. *Indian Journal of Dental Research*, 22(1), pp.140-143.
4. Succaria, F. and Morgano, S.M., 2011. Prescribing a dental ceramic material: Zirconia vs lithium-disilicate. *The Saudi dental journal*, 23(4), p.165.
5. Haralur, S.B. and Al-Faifi, A.H., 2012. Use of CAD/CAM in esthetic restoration of badly decayed tooth. *Case Reports in Dentistry*, 2012.
6. Hatami, M., Sabouhi, M., Samanipoor, S. and Badrian, H., 2012. Prosthodontic rehabilitation of the patient with severely worn dentition: a case report. *Case reports in dentistry*, 2012.
7. Santos Jr, G.C., Boksman, L.L. and Santos, M.J., 2013. CAD/CAM technology and esthetic dentistry: a case report. *Compend Contin Educ Dent*, 34(10).
8. Daou, E.E., 2014. The zirconia ceramic: strengths and weaknesses. *The open dentistry journal*, 8, p.33.
9. Bansal, P., Chahal, G. and Gill, J., 2017. Zirconia Veneers In Fluorosis Patient: Case Report. *Journal Of Applied Dental and Medical Sciences*, 4, p.1.
10. Teichmann, M., Wienert, A.L., Rückbeil, M., Weber, V., Wolfart, S. and Edelhoff, D., 2018. Ten-year survival and chipping rates and clinical quality grading of zirconia-based fixed dental prostheses. *Clinical oral investigations*, 22, pp.2905-2915.
11. Zarone, F., Di Mauro, M.I., Ausiello, P., Ruggiero, G. and Sorrentino, R., 2019. Current status on lithium disilicate and zirconia: a narrative review. *BMC oral health*, 19, pp.1-14.
12. Kallala, R., Chaouch, M.H., Nasr, K. and Courset, T., 2021. Step-by-step esthetic rehabilitation with chairside system. *Case Reports in Dentistry*, 2021.