

<https://doi.org/10.33472/AFJBS.6.2.2024.1287-1306>



African Journal of Biological Sciences



Research Paper

Open Access

Impacts of *Echinacea purpurea* on the immune-reproductive changes associated with the aging process in male rats

Khadiga Hassanin Mohamed¹, Amira Moustafa^{1*}, Hussein Ahmed Heshmat¹

¹Department of Physiology, Faculty of Veterinary Medicine, Zagazig University, 44519 Zagazig, Egypt

Corresponding author: Amira Moustafa

Email: amiramostafa@zu.edu.eg, ORCID NUMBER: 0000-0001-9483-4142

Article History

Volume 6, Issue 2, April 2024

Received: 19 April 2024

Accepted: 15 June 2024

Published: 15 June 2024

doi: 10.33472/AFJBS.6.2.2024.1287-1306

Abstract: This study aimed to investigate the effect of aging on immune reproductive function, oxidative stress parameters, and the beneficial effects of *Echinacea purpurea* (EP) root extract in male Sprague-Dawley rats. Rats were randomly divided into three groups: control-young, control-old (administered only saline), and old-treated groups (orally administered EP once daily for one week, followed by two weeks without treatment) for 12 successive months. The results showed that the survival rate, sperm count, and motility were enhanced by EP treatment, while the percentage of sperm abnormalities declined. Treatment with EP improved serum levels of gonadotropin-releasing hormone, luteinizing hormone, follicle-stimulating hormone, and testosterone. Serum levels of antioxidant enzymes, interleukin-2, interleukin-10, and tumor necrosis factor-alpha were increased by EP treatment, whereas malondialdehyde, interleukin-1 β , and interleukin-6 levels were decreased. The mRNA expression levels of caspase-3 in the testes and spleen were increased in the control-old group, and EP treatment decreased them. Peroxisome proliferator-activated receptor gamma coactivator 1-alpha (PGC-1 α) and Sirtuin-1 (SIRT-1) mRNA expression levels were declined in the control-old and old-treated groups. The morphology of the reproductive and immune tissues was improved by EP treatment. In conclusion, the administration of EP root extract ameliorates the unfavorable effects of aging by its anti-inflammatory and antioxidative properties.

Keywords: Purple Coneflower; Aging; Spleen; Testes; Antioxidants

Introduction

Aging is accompanied by several morphological and physiological changes that occur in the majority of organs in all individuals. Most organs and systems have a number of gradual, predictable, and progressive changes as we age. Over time, every person experiences physiological changes at the molecular, structural, and functional levels [1]. With aging, there is an apparent loss of physiological reserves. When the reserves are exhausted, the elderly person becomes weak and unable to handle new difficulties without going over a precipice [2]. Numerous age-related illnesses, including cancer, immune system problems, musculoskeletal disorders, cardiovascular diseases, and neurological diseases, have been reported [3].

There are numerous theories regarding the aging process of organisms [4]. Most of those theories can be divided into two groups. The first group is "the genetic program theories", which propose that aging is the result of a purposeful program driven by genes. Second, the "epigenetic theories" propose that aging is not

genetically predetermined, but rather the product of stochastic or random events rather than actions directed by a program [5]. Therefore, hypotheses such as telomere shortening must be considered plausible explanations for processes of cell differentiation or replicative cellular senescence, but not as the fundamental cause of organism aging. The free-radical theory has attracted the most attention out of all the aging theories. Age-related illnesses, physiological aging, and shortened lifespans all seem to be mostly caused by oxidative stress [6]. It happens when the antioxidant system's defensive response to the generation of free radicals becomes insufficient [7]. Since reactive oxygen species (ROS) can either directly or indirectly activate transcription factors like nuclear factor-kappaB (NF- κ B) and activator protein-1, which can induce inflammation that is intimately related to oxidative stress [8]. Elevations of proinflammatory indicators and circulating cytokines are linked to aging. Elevations in interleukin-6 (IL-6), interleukin-1 (IL-1), tumor necrosis factor-alpha (TNF- α), and C-reactive protein have been linked to a higher risk of morbidity and mortality in older individuals [9].

In rats, testicular morphology and function change with aging [10]. Pathological testicular premature aging is also attributed to a variety of external and endogenous causes, including gene alterations and unfavorable environmental stresses [11]. Examining the connection between reduced male fertility and environmental variables has received more attention in recent years. Male fertility may be impaired by a variety of environmental and professional factors, as well as lifestyle choices. There is evidence that male reproductive function decreases with aging. Sperm genetic and epigenetic changes are accelerated by aging and may result in lower fertility and lower-quality semen [12]. However, the exact mechanism underlying age-related reproductive failure remains unclear.

Anti-aging medications that target the causes of aging have recently come under attention. Purple coneflower, or *Echinacea purpurea* (EP) (L.), Moench, a member of the Asteraceae family, is a perennial medicinal herb with significant immunostimulatory and anti-inflammatory abilities [13,14]. One of the highly significant physiological reductions that have been extensively studied in response to stress or disturbance, which influences negatively the health span of individuals, is immune system hypofunction [15]. Therefore, this study aims to investigate the effect of aging on different biochemical, oxidative stress parameters, and immunoreproductive functions in male rats and examine the effect of anti-aging phytomedicine (EP root extract, EP) on improving health in old age.

Materials and methods

Ethical Approval

This study was approved by the Institutional Animal Care and Use Committee Guidelines of the Faculty of Veterinary Medicine, Zagazig University (Approval No, ZU-IACUC/2/F/66/2020).

Animals

75 male Sprague-Dawley (SD) rats with an initial mean body weight (130 ± 10 g) were obtained from the laboratory animal unit (Zagazig University) and permitted to acclimatize for two weeks before the experiment. Rats were housed on a 12-h light/dark cycle at a constant temperature (22 ± 2 ° C) and relative humidity (50–60%) with free access to water *ad libitum*.

Experimental design

Rats were randomly divided into three groups (n= 25/group): control-young (2 months), control-old, and old-treated groups (14 months). The latter was treated by EP (100 mg/kg BW, EMA Pharmaceuticals Company, Cairo, Egypt) [16]. EP was administered orally by gastric gavage to young rats once daily for one week, followed by two consecutive weeks without treatment for 12 successive months. We suggested this protocol for EP administration as prolonged use may weaken the immune system, probably because of overstimulation. The control-old group was administered only saline. Changes in the body weights and survival % of the animals were monitored weekly.

Blood and tissue collection

All rats were quickly decapitated after an overnight fast with free access to water [17]. The control-young group (6 weeks) was sacrificed after the completion of the acclimatization period (2 weeks). However,

rats in the control-old and old-treated groups were sacrificed after finishing the housing period (12 m). Animal's trunk blood was collected in a serum-separating tube gel, allowed to clot, and centrifuged at 3000 g for 20 min for separation of serum that was stored at -20° C until further analysis. Testes, epididymis, seminal vesicle (SV), prostate, spleen, thymus, and adrenal glands were excised and weighted.

Testes, epididymis, spleen, thymus, and femur were fixed in a 10% neutral buffered formalin solution for histological evaluation. Part of one testis and part of the spleen were collected, snap-frozen in liquid nitrogen, and preserved at -80° C for further total ribonucleic acid (RNA) extraction.

Epididymal sperm analysis

One cauda epididymis was removed immediately in a sterilized Petri dish containing 2ml of normal saline at 37 ° C, cut, and the suspension was handled as semen. A single drop of the semen sample was put on a glass slide that had been prewarmed to 37 °C, covered with a cover slide, and examined under a light microscope (40x) to determine the motility of the sperm [18]. The percentage of abnormal sperm was determined by staining a glass slide with a smear of the semen sample using an eosin-nigrosine stain. The concentration of sperm cells was measured using an improved Neubauer hemocytometer counting chamber after the semen sample was diluted five times (v/v) using normal saline containing a few drops of 40% formalin to immobilize the spermatozoa [19].

Measurement of serum biomarkers

Rat enzyme-linked immunosorbent assay (ELISA) kits were utilized according to the manufacturer's instructions to assess the concentrations of different hormones. The catalog numbers for the utilized ELISA kits were as follows: gonadotropin-releasing hormone (GnRH; ER1003; Wuhan Fine Biotech Co., Ltd.), luteinizing hormone (LH; CSB-E12654r; Cusabio Biotech Co., Ltd.), follicle-stimulating hormone (FSH; CSB-E06869r; Cusabio Biotech Co., Ltd.), testosterone (EK7014; Boster Biological Technology, Pleasanton, CA). The concentrations of immunoglobulin G (IgG; CSB-E07981r; Cusabio Biotech Co., Ltd.), immunoglobulin M (IgM; CSB-E07978r; Cusabio Biotech Co., Ltd.), immunoglobulin E (IgE; CSB-E07984r; Cusabio Biotech Co., Ltd.), and immunoglobulin D (IgD; CSB-EQ027960RA; Cusabio Biotech Co., Ltd.) were estimated using rat ELISA kits according to the manufacturer's protocol. Interleukin-10 (IL-10; ER0033; Wuhan Fine Biotech Co., Ltd.), interleukin-2 (IL-2; R2000, Quantikine R&D Systems, Minneapolis, USA), interleukin-1 β (IL-1 β ; RLB00, Quantikine R&D Systems, Minneapolis, USA), interleukin-6 (IL-6; EK0412; Boster Biological Technology, Pleasanton, USA), TNF- α (TNF- α ; RAB0480; Sigma Aldrich, Louis, USA), NF- κ B (NF- κ B; CSB-E13148r; Cusabio Biotech Co., Ltd.) were measured using commercially available rat ELISA kits. The activities of the antioxidant enzymes superoxide dismutase (SOD; MBS036924; MyBioSource, San Diego, USA) and catalase (CAT; MBS726781; MyBioSource, San Diego, USA), and the concentration of the lipid peroxidation marker malondialdehyde (MDA; MBS268427; MyBioSource, San Diego, USA) were measured using commercially available rat ELISA kits according to the manufacturer's protocol. **RNA extraction and Real-Time Polymerase Chain Reaction**

Total RNA was extracted from testes and spleen tissue samples using Trizol (Invitrogen; Thermo Fisher Scientific, Waltham, MA, USA). The quality of RNA was evaluated by measuring the A260/A280 ratio using the NanoDrop VR ND-1000 Spectrophotometer (NanoDrop Technologies; Wilmington, DE, USA). For complementary deoxyribonucleic acid (cDNA) synthesis, a High-Capacity cDNA Reverse Transcription Kit cDNA Kit (Applied Biosystems™, USA) was utilized. Real-time polymerase chain reaction (RT-PCR) was performed using a CFX96 real-time PCR detection system (CFX96; Bio-Rad, Hercules, CA, USA) with the TOPreal™ qPCR 2X PreMIX (SYBR Green with low Rox; Enzynomics Inc., Daejeon, Korea) according to the manufacturer's instructions. The conditions of PCR cycling included a preliminary denaturation at 95 °C for 15 min, followed by 40 cycles of denaturation at 95 °C for 30 s, annealing at 60 °C for 60 s, and a final elongation at 72 °C for 60 s. The primers (Table 1, Sangon Biotech, Beijing, China) were prepared according to their manufacturer's instructions. The relative fold changes in gene expression were calculated using the 2^{- $\Delta\Delta$ CT} method [20].

Table 1: Primers sequences of targeted genes.

Gene	Forward Primer Sequence (5' to 3')	Reverse Primer Sequence (5' to 3')	Product size	Accession number
Gapdh	GCATCTTCTTGTGCAGTGCC	GGTAACCAGGCGTCCGATAC	91	NM_017008.4
SIRT1	AGCTGGGGTTTCTGTTTCT	TGCTGAGTTGCTGGATTTTG	224	NM_001372090.1
Caspase-3	GAGACAGACAGTGGAAGTACGATG	GGCGCAAAGTACTGGATGA	147	NM_012922.2
PGC1 α	TTCAGGAGCTGGATGGCTTG	GGGCAGCACACTCTATGTCA	70	NM_031347.1

Histological examination

Testes, epididymis, spleen, thymus, and bone marrow tissue samples were kept for 48 hours in a 10% neutral buffered formalin solution, then dehydrated in ethanol concentrations ranging from 70% to 100%, cleaned in xylene, and embedded in paraffin wax. An automated microtome was used to create paraffin sections with a thickness of 5 μ m. Hematoxylin and eosin stain were then applied [21]. Femur bones were decalcified with 10% formic acid.

Statistical analysis

The present data are expressed as the mean \pm standard error of the mean (SEM). The results were statistically analyzed using a one-way analysis of variance (ANOVA). The mean values of the control and various experimental groups were compared using the post-hoc Tukey's test. The differences in survival % were analyzed using the Gehan-Breslow-Wilcoxon test. SPSS Statistics computer software (version 11.0) was used to perform the statistical analyses. A value of $p < 0.05$ was considered statistically significant.

Results**Effect of aging on body weight, survival %, and organs weight.**

Across 12 m of the intervention period, significant declines in body weights of the control-old group were observed when compared with the old-treated group (Figure 1A, $p < 0.05$ and $p < 0.01$ by Student's *t*-test, respectively). Administration of EP improved the survival % in old-treated rats compared with the non-treated group (Figure 1B). Reproductive organs weights, namely, testes, epididymis, SV, and prostate were considerably lighter in the control-young rats compared to control-old and old-treated rats. Moreover, an increase in the weight of the testes and SV was noticed in the old-treated rats compared to control-old rats (Table 2). The weight of the spleen and adrenal gland shows significant increases in the old-treated groups when compared to the control-young group, but the thymus weight was significantly reduced in the control-old group when compared to the control-young group (Table 2).

Figure 1

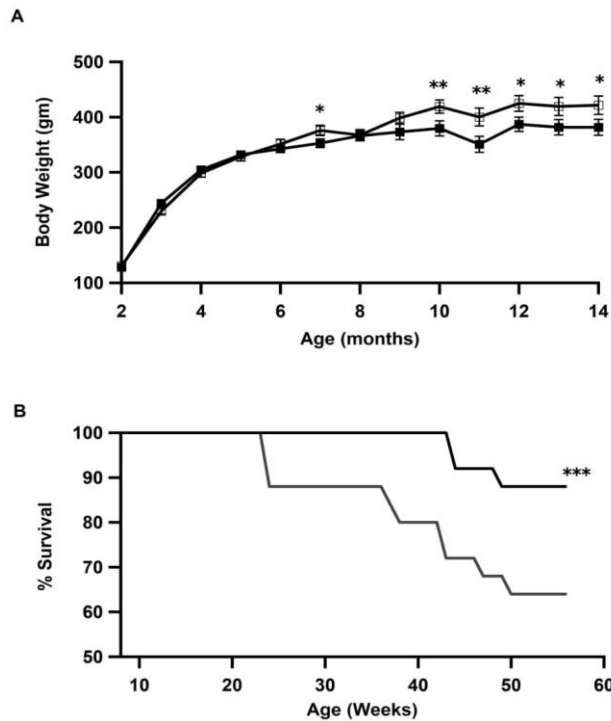


Figure 1: Changes in body weight and survival %. (A) Body weights (g) in the control-old (closed squares) and old-treated (open squares) rats. Data are means \pm SEM (n = 25 in each group). *p \leq 0.05 and **p \leq 0.01 by Student's *t*-test. (B) Survival % in the control-old (black line) and old-treated (gray line) rats. Survival was monitored weekly for up to 12 m. Data are means \pm SEM (n = 25 in each group). ***p \leq 0.001 by Gehan-Breslow-Wilcoxon test.

Table 2: Absolute organs weight: testes, epididymis, seminal vesicle, prostate, spleen, thymus and adrenal gland in young, control-old and old-treated rats. Values are means \pm SEM (n = 25 in each group).

Organ	Control-young	Control-old	Old-treated
Testes (g)	1.409 \pm 0.115 ^a	2.635 \pm 0.234 ^b	3.511 \pm 0.152 ^c
Epididymis (g)	0.392 \pm 0.011 ^a	1.33 \pm 0.041 ^b	1.329 \pm 0.018 ^b
Seminal vesicle(g)	0.186 \pm 0.023 ^a	1.214 \pm 0.091 ^b	1.749 \pm 0.125 ^c
Prostate (g)	0.192 \pm 0.01 ^a	0.642 \pm 0.032 ^b	0.693 \pm 0.056 ^{b,c}
Spleen (g)	1.034 \pm 0.091 ^a	1.35 \pm 0.116 ^{a,b}	1.44 \pm 0.107 ^b
Thymus (g)	0.29 \pm 0.027 ^a	0.177 \pm 0.007 ^b	0.196 \pm 0.047 ^{a,b}
Adrenal gland (g)	0.065 \pm 0.001 ^a	0.079 \pm 0.007 ^{a,b}	0.118 \pm 0.021 ^b

^{a,b,c}Means within a row carrying different superscript letters denote significant differences (P < 0.05).

Effect of aging on semen parameters and levels of reproductive hormones.

Sperm cell concentrations were significantly increased in the control-old and old-treated groups compared to the control-young group. Moreover, treatment with EP significantly elevated sperm cell concentration in old-treated rats when compared to control-old rats (Figure 2A, P < 0.001 by ANOVA). The percentage of sperm motility declined with aging and was improved by EP treatment (Figure 2B, P < 0.01 by ANOVA). The percentage of morphologically abnormal sperm was significantly increased in the control-old

group and decreased by EP treatment (Figure 2C, $p < 0.001$ by ANOVA). Serum levels of reproductive hormones are shown in (Figure 2D-G). The levels of GnRH, LH, FSH, and testosterone were elevated in the control-old group as compared with the control-young group. Levels of the reproductive hormones were further improved in the old rats by EP treatment (Figure 2D-G respectively, $P \leq 0.001$ by ANOVA).

Figure 2

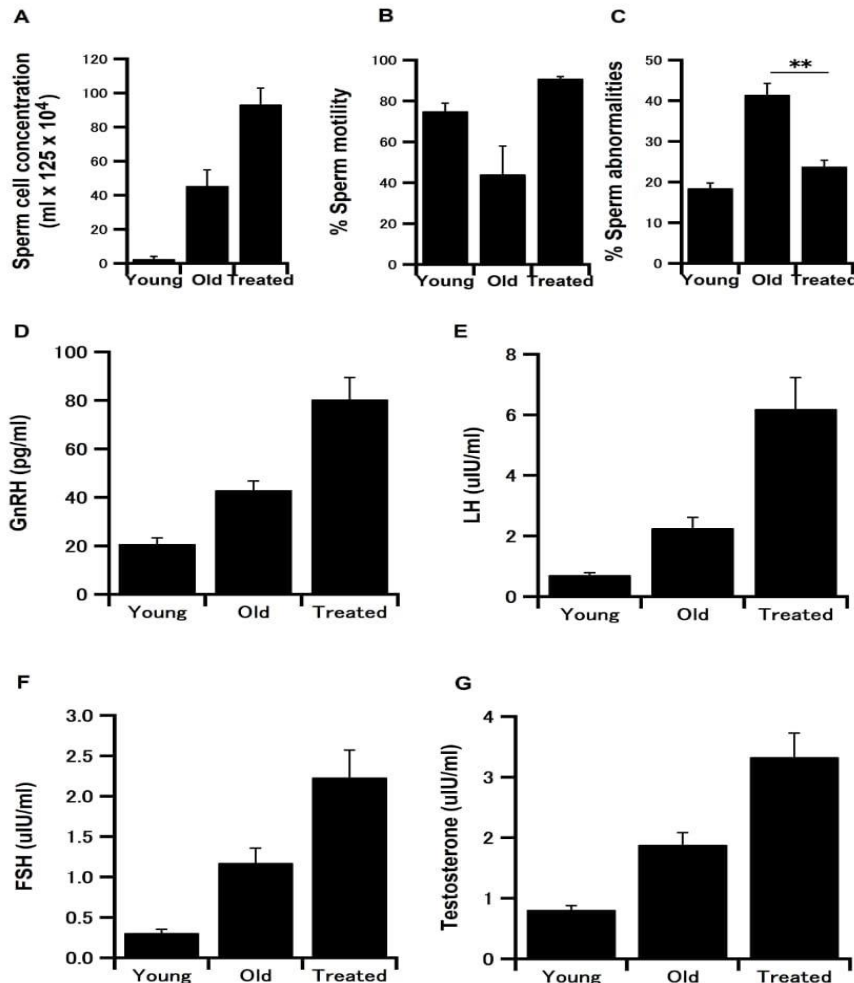


Figure2: Changes in sperm parameters and serum levels of reproductive hormones in male rats.

(A) Sperm cell concentration; (B) Percentage of sperm motility; (C) Sperm abnormalities (%) in the control-young, control-old, and old-treated groups. Serum levels of: (D) GnRH (pg/ml); (E) LH (uIU/ml); (F) FSH (uIU/ml); and (G) testosterone (ng/ml) in the control-young, control-old, and old-treated groups. Data are means \pm SEM ($n = 25$ in each group). $**p \leq 0.01$ and $***p \leq 0.001$ by ANOVA.

Effect of aging on the levels of immunoglobulins and cytokines

The levels of IgG were significantly elevated in the old-treated group when compared to the control-young and control-old groups respectively (Figure 3A, $P \leq 0.001$ by ANOVA). The levels of IgM were significantly increased in both control-old and old-treated groups as compared with the control-young group (Figure 3B, $P \leq 0.001$ by ANOVA). The levels of IgE showed no significant difference between the three groups (Figure 3C). The levels of IgD were significantly increased in the old-treated group when compared to the control-young and control-old groups (Figure 3D, $P \leq 0.001$ by ANOVA).

Figure 3

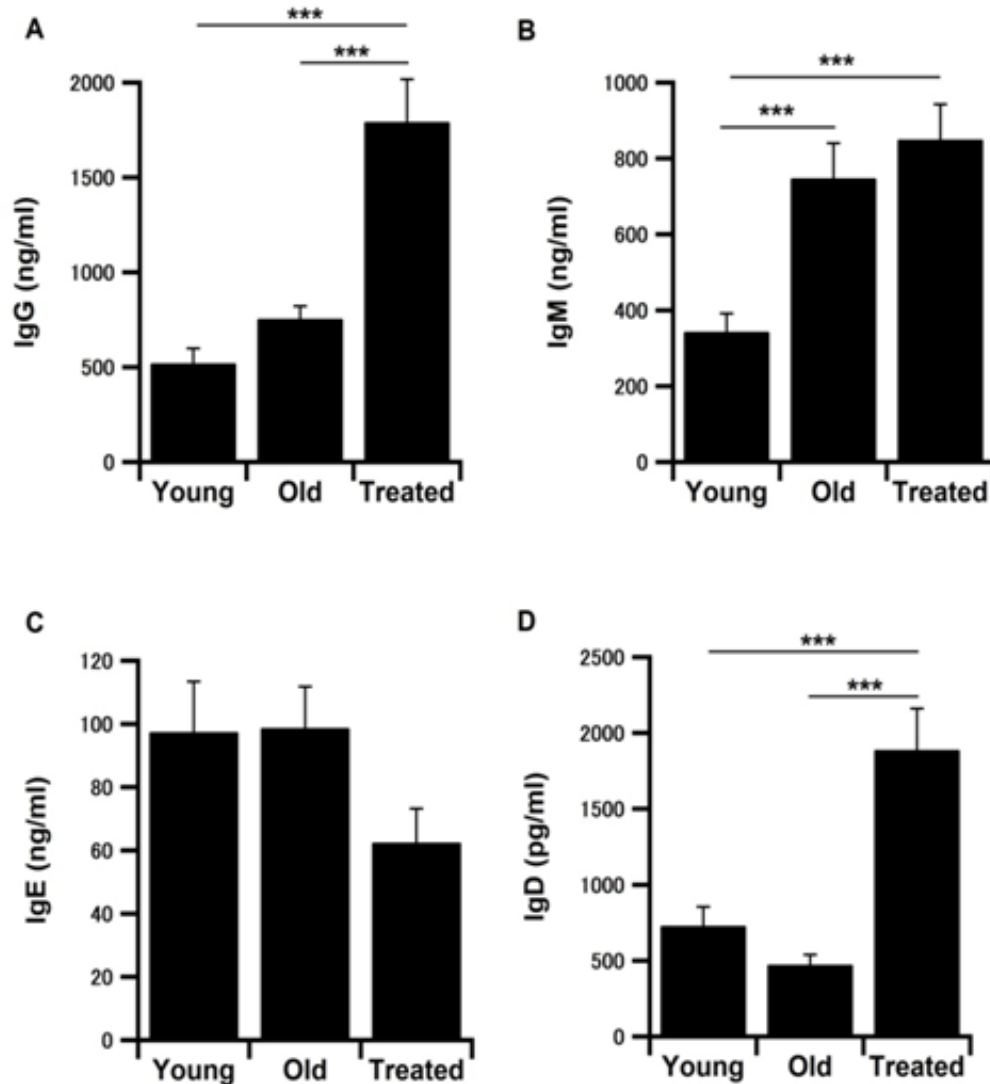


Figure 3: Changes in the levels of immunoglobulins. Level of: (A) IgG (ng/ml); (B) IgM (ng/ml); (C) IgE (ng/ml); and (D) IgD (pg/ml) in the control-young, control-old, and old-treated groups. Results are means \pm SEM (n = 25 in each group). ***p \leq 0.001 by ANOVA.

The levels of IL-10 and IL-2 were significantly increased in the control-old group compared with the control-young group. Treatment of old rats with EP further elevated the concentrations of IL-10 and IL-2 (Figure 4A and B, $P \leq 0.001$ by ANOVA). However, the levels of IL-1 β and IL-6 were significantly decreased in the control-old and old-treated groups when compared to the control-young group (Figure 4C and D, $P \leq 0.001$ by ANOVA). Treatment with EP induced a further decline in IL-1 β levels in old rats (Figure 5C, $P \leq 0.001$ by ANOVA), but, does not affect the levels of IL-6 (Figure 4D). Levels of TNF- α and NF- κ B revealed significant increases in the control-old and old-treated groups compared to the control-young group. EP treatment increases the levels of TNF- α and NF- κ B in old rats (Figure 4E and F, $P \leq 0.001$ by ANOVA).

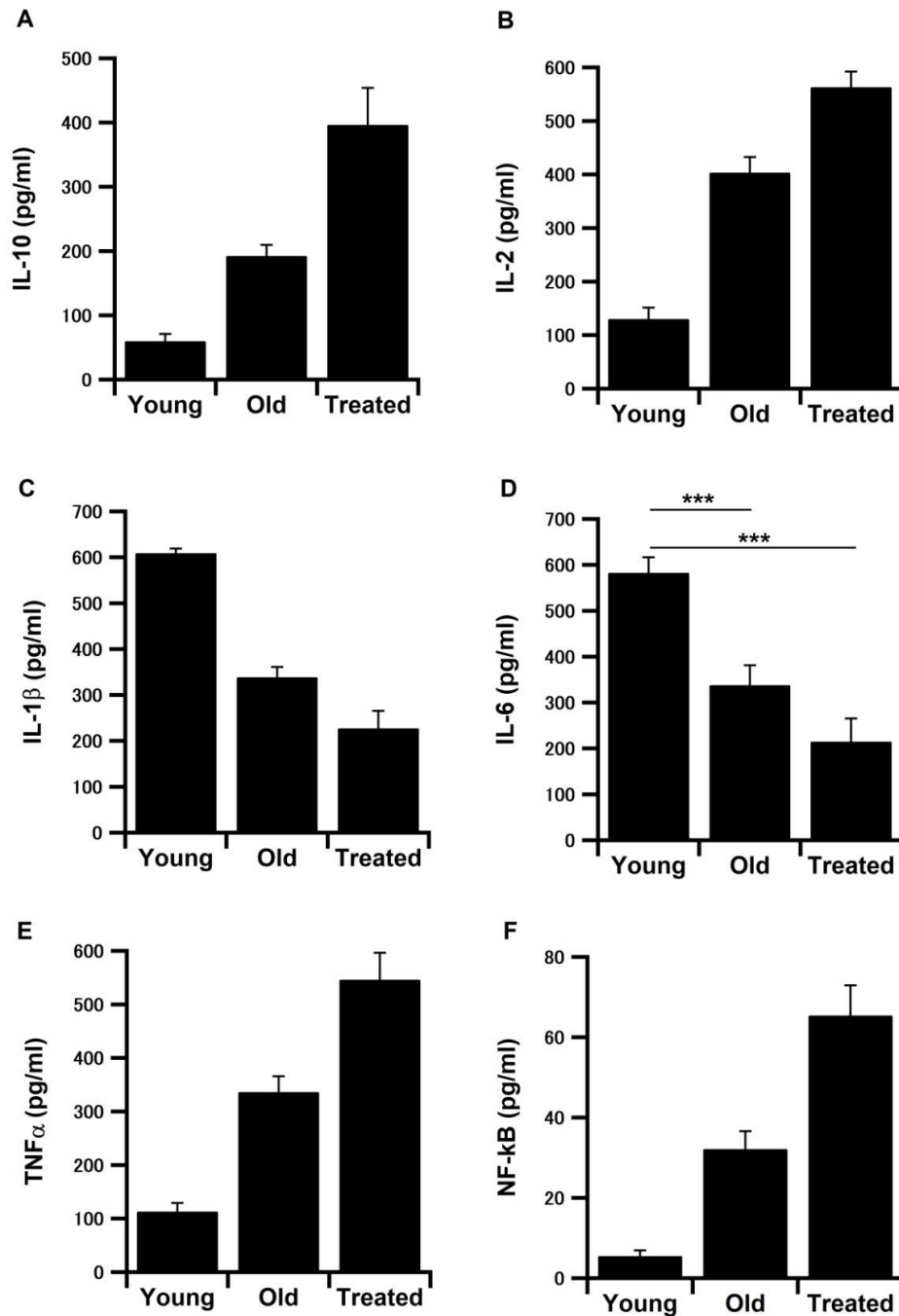


Figure 4: Serum levels of cytokines. (A) IL-10 (pg/ml); (B) IL-2 (pg/ml); (C) IL-1 β (pg/ml); (D) IL-6 (pg/ml); (E) TNF- α (pg/ml); and (F) NF- κ B (pg/ml) in the control-young, control-old, and old-treated groups. Results are means \pm SEM (n = 25 in each group). ***p \leq 0.001 by ANOVA.

Effect of aging on the levels of antioxidant enzymes and lipid peroxidation marker.

Serum levels of the antioxidant enzymes SOD and CAT were significantly increased in the control-old group and showed more increases with EP treatment (Figure 5A and B, P \leq 0.001 by ANOVA). While the concentrations of lipid peroxidation marker MDA declined in the control-old group and revealed more reduction by EP treatment (Figure 5C, P \leq 0.001 by ANOVA).

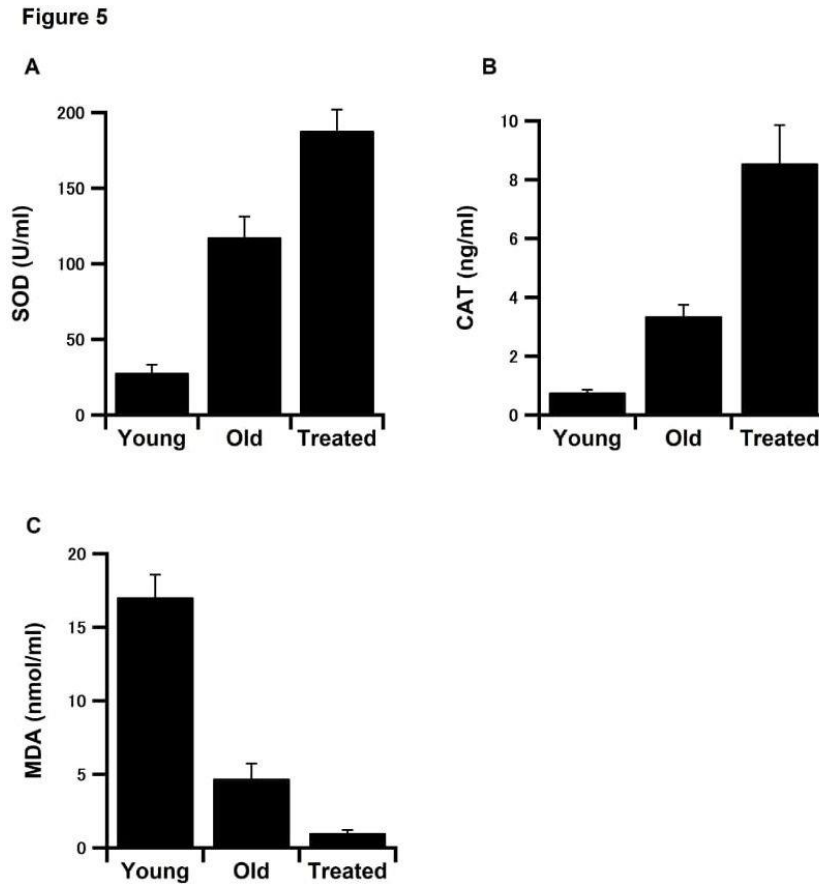


Figure 5: Serum levels of antioxidants and lipid peroxidation markers. (A) SOD levels (U/ml); (B) CAT concentration (ng/ml); and (C) MDA levels (nmol/ml) in the serum of control-young, control-old, and old-treated groups. Results are expressed as means \pm SEM ($n = 25$ in each group). *** $p \leq 0.001$ by ANOVA.

Effect of aging on gene expression in the testes and spleen

The messenger mRNA expression levels of caspase-3, the key molecule of apoptosis, were upregulated in the control-old rats compared to the control-young rats in both testes and spleen (Figure 6A and B, $P < 0.05$ and $P < 0.01$ by ANOVA, respectively), and treatment of old rats with EP down regulated the levels of caspase-3 mRNA expression in testes and spleen to the same level as in the control-young rats (Figure 6A and B, $P < 0.05$ and $P < 0.01$ by ANOVA, respectively). Peroxisome proliferator-activated receptor gamma coactivator 1-alpha (PGC-1 α) mRNA expression levels were significantly decreased in the control-old and old-treated groups when compared with the control-young group in the testes (Figure 6C, $P < 0.001$ by ANOVA) and spleen (Figure 6D, $P < 0.05$ and $P < 0.001$ by ANOVA, respectively). Although treatment of old rats with EP tended to suppress the mRNA expression levels of PGC-1 α in both the testes and spleen, the results remain insignificant. In the testes, the mRNA expression levels of sirtuin-1 (SIRT-1) markedly declined in the control-old group, though the results were insignificant. However, treatment with EP significantly downregulated the expression levels of SIRT-1 (Figure 6E, $P < 0.05$ by ANOVA). In the spleen, the expression levels of SIRT-1 significantly declined in the control-old and old-treated groups when compared to the control-young group (Figure 6F, $P < 0.001$ by ANOVA).

Figure 6

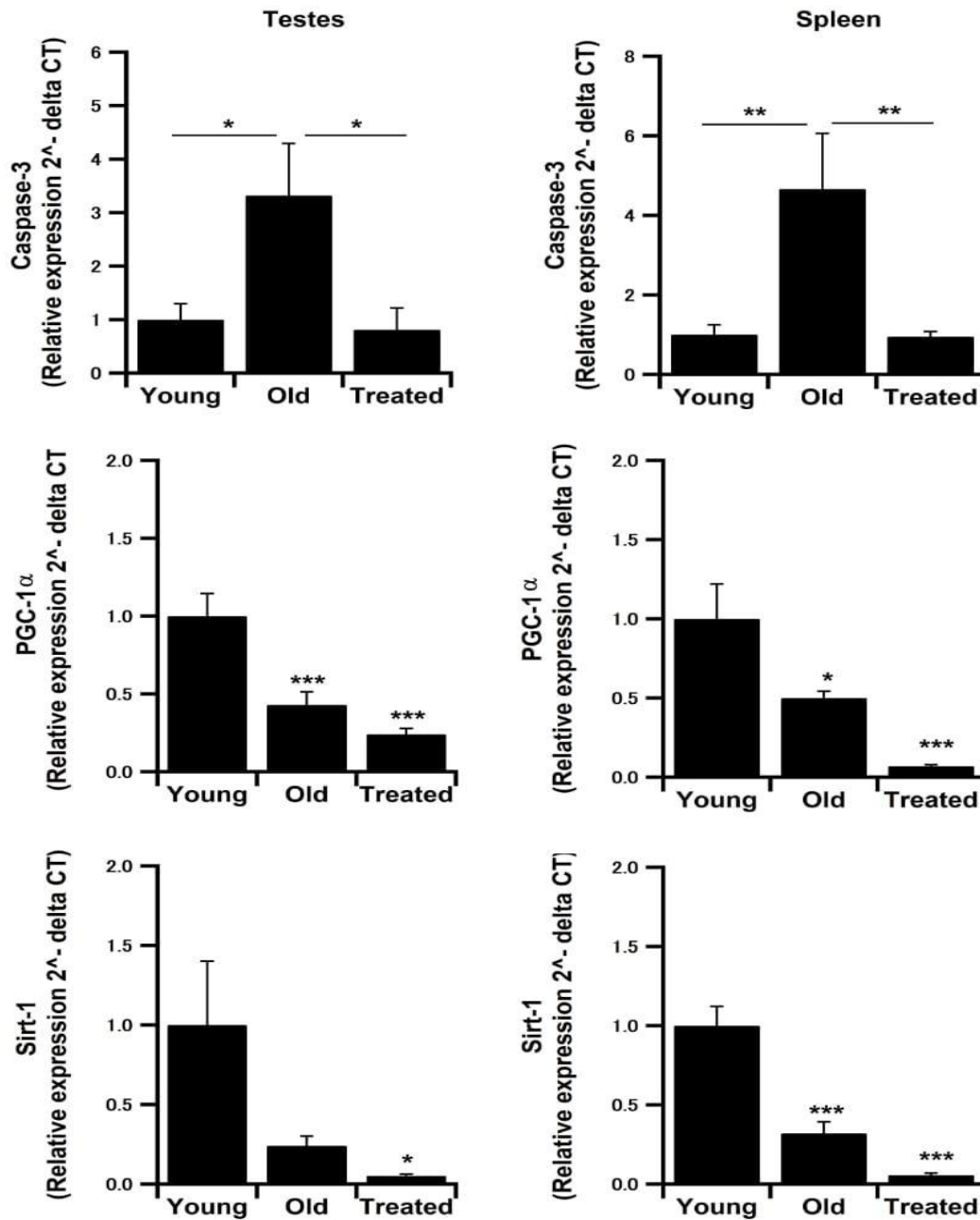


Figure 6: Gene expression levels by RT-PCR. (A, B) mRNA expression levels of caspase-3 in the testes and spleen, respectively. (C, D) Levels of PGC-1 α mRNA expression in the testes and spleen, respectively. (E, F) Sirt-1 mRNA expression levels in the testes and spleen, respectively. Results are presented as means \pm SEM (n = 25 in each group). *p \leq 0.05, **p \leq 0.01, and ***p \leq 0.001.

Effect of aging on the morphology of the reproductive tissues

Testes of the control-young group showed atrophy of seminiferous tubules, and the atrophied tubules were characterized by nearly empty lumina with the presence of epithelial necrotic debris (Figure 7A and B, upper panel). Testes of the control-old group revealed apoptosis in some germinal epithelial lining the tubules and thickening within the interstitial tissue (Figure 7C and D, upper panel). In the old-treated group,

testes exhibited non-histopathological alterations in seminiferous tubule components and interstitial tissue. Each tubule is composed of basal spermatogonia, layers of spermatocytes, spermatids, and mature sperms (Figure 7E and F, upper panel). The epididymis of the control-young group revealed normal architectures of epididymal tubules, which are lined by columnar epithelium and filled with populations of sperm in their lumina (Figure 7, lower panels A and B). The control-old group epididymis showed normal ciliated epithelial lining tubules with a smaller number of stored spermatozoa (Figure 7, lower panels C and D). Old-treated group epididymal tubules were mostly convoluted, impacted with mature sperms, lined by columnar ciliated epithelium, and surrounded by mild interstitial edema with inflammatory cells (Figure 7, lower panels E and F).

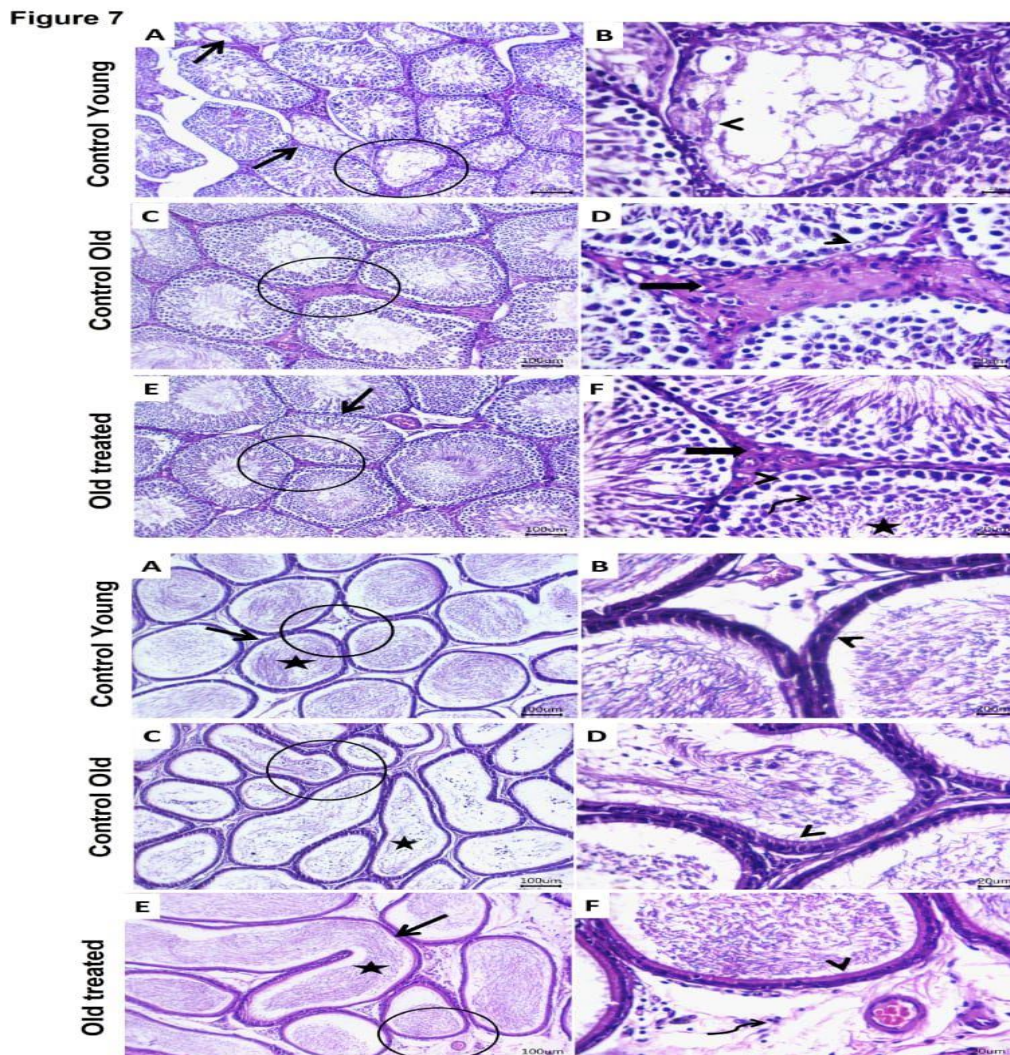


Figure 7: Photomicrograph of H&E stained sections from testes (upper panels). (A, B) Testes of the control-young group showed atrophied seminiferous tubules (**arrow**), and epithelial necrotic debris within their lumina (**arrowhead**). (C, D) Testes of the control-old group revealed apoptosis in some germinal epithelial lining tubules (**arrowhead**) and thickening within interstitial tissue (**arrow**). (E, F) Testes of the old-treated group showed non-histopathological alterations in the seminiferous tubules (**arrow**), interstitial tissue (**thick arrow**), basal spermatogonia (**arrowhead**), layers of spermatocytes (**curved arrow**), and sperms (**star**). Scale bar 20 and 100 μm respectively.

Photomicrograph of H&E stained sections from epididymis (lower panels). (A, B) Epididymal sections of the control-young group showed normal architectures of the epididymal tubules (**arrow**) lined by columnar epithelium (**arrowhead**) and filled with populations of sperms in their lumina (**star**). (C, D) Sections of the epididymis of the control-old group revealed normal ciliated epithelial lining tubules (**arrowhead**) with less number of stored spermatozoa (**star**). (E, F) Epididymis of the old-treated group showed convoluted epididymal tubules (**arrow**), impacted with mature sperms (**star**), lined by columnar ciliated epithelium (**arrowhead**), and surrounded by mild interstitial edema with inflammatory cells (**curved arrow**). Scale bar 20 and 100 μm respectively.

The spleen of the control-young group showed a normal germinal center, mantle zone, marginal zone, and central arteriole of white pulp. The structures of red pulp, which include sinusoids, a network of reticular fibers with lymphocytes, macrophages, and a few megakaryocytes, were maintained as well (Figure 8 A and B, upper panel). In the control-old group, the spleen showed dilated splenic sinusoids impacted with different types of inflammatory cells, mainly lymphoid elements. Furthermore, many apoptotic bodies were seen within the germinal centers of white pulp (Figure 8 C and D, upper panel). The spleen of the old-treated group exhibited normal cytostructures of white pulp lymphoid nodules (central arteriole, germinal center, mantle zone, and marginal zone) and preserved red pulp, which had sinusoids, macrophages, lymphocytes, and many megakaryocytes (Figure 8 E and F, upper panel).

In the control-young group, thymic lobules were divided by septa and formed from a peripherally more densely packed cortex and pale stained medulla with reticular cells and a low number of lymphocytes (Figure 8 A and B, upper panel). The thymus of the control-old group showed cortical and medullary lymphoid lobules. However, there were fewer cortical reticular epithelium and lymphoid elements than in the old-treated group (Figure 8 C and D, upper panel). The thymus of the old-treated group revealed preserved histomorphology of dark-stained cortex and a less densely packed medulla with epithelial cells (Figure 8 E and F, upper panel).

The bone marrow of the control-young group showed normal myelocytic, lymphocytic, erythrocytic, and megakaryocytic hematopoietic series between bony spicules of spongy bone (Figure 8 A and B, lower panel). The bone marrow of the control-old group revealed normal cytoarchitecture of whole blood cell precursors and megakaryocytes. The latter had an irregular nucleus and abundant cytoplasm. In addition, abundant fat vacuoles were also observed (Figure 8 C and D, lower panel). The bone marrow of the old-treated group exhibited active bone marrow with an increased number of all blood-forming cells. A large number of mature lymphocytes and megakaryocytes and a lesser number of adipocytes were observed as well (Figure 8 E and F, lower panel).

Figure 8

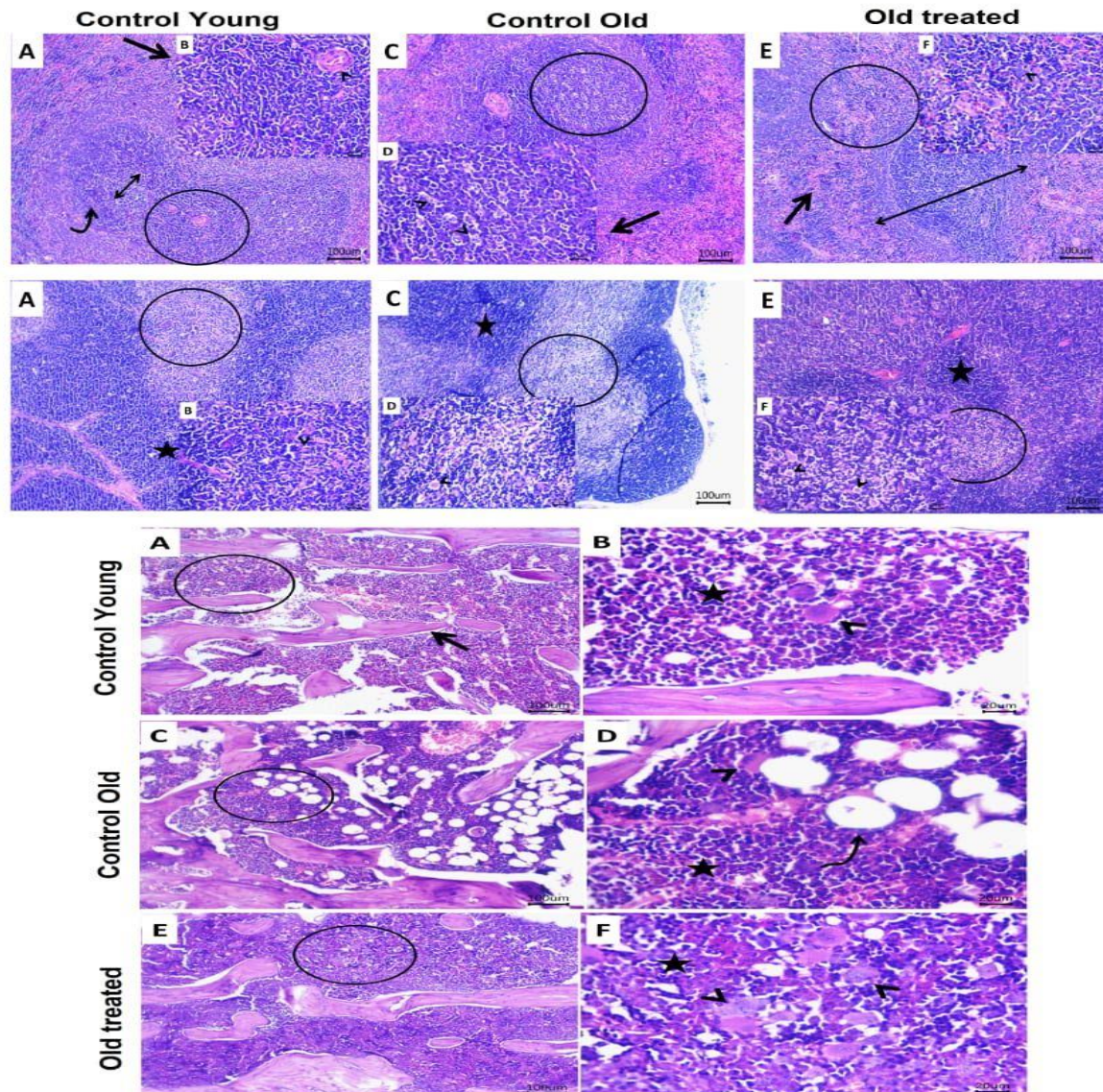


Figure8: Photomicrograph of H&E stained sections from spleen (upper panels). (A, B) Sections of the spleen of the control-young group showed normal germinal center (**double-headed arrow**), mantle zone (**curved arrow**), marginal zone (**star**), and central arteriole (**arrowhead**) of white pulp and maintained structures of the red pulp (**arrow**). (C, D) The spleen section of the control-old group showed dilated splenic sinusoids within the red pulp (**arrow**) and many apoptotic bodies within the germinal centers of the white pulp (**arrowheads**). (E, F) Sections of the spleen of the old-treated group revealed normal cytostructure of white pulp lymphoid nodule (**double-headed arrow**) and preserved red pulp (**arrow**) with many megakaryocytes (**arrowhead**). Scale bar 20, 100 μ m respectively.

Photomicrograph of H&E stained sections from Thymus (upper panels). (A, B) Sections from the thymus of the control-young group showed thymic lobules divided by septa and formed from peripherally more densely packed cortex (**star**) and pale stained medulla (**circle**) with reticular cells (**arrowhead**) and low number of lymphocytes (**arrow**). (C, D) Thymus sections of the control-old group showed cortical (**star**) and medullary (**circle**) lymphoid lobules with less cortical reticular epithelium (**arrowhead**) and lymphoid elements. (E, F) Section from the thymus of the old-treated group showed preserved histomorphology of dark

stained cortex (**star**), and less densely packed medulla (**circle**) with epithelial reticular cells (**arrowheads**). Scale bar 20 and 100 μm respectively.

Photomicrograph of H&E stained sections from bone marrow (lower panels). (A, B) The bone marrow section of the control-young group showed normal hematopoietic cells (**star**) and megakaryocytes (**arrowhead**) between bony spicules of spongy bone (**arrow**). (C, D) Sections of bone marrow from the control-old group revealed normal cytoarchitecture of whole blood cell precursors (**star**) and megakaryocytes (**arrowhead**) and abundant fat vacuoles (**curved arrow**). (E, F) Sections of bone marrow from the old-treated group showed active bone marrow with an increased number of all blood-forming cells especially mature lymphocytes (**star**) and megakaryocytes (**arrowheads**). Scale bar 20 and 100 μm respectively.

Discussion

Aging is a physiological process mediated by several biological and genetic pathways that mediate all age-related diseases and are directly related to lifespan [22]. EP extract is employed in this investigation as a possible phytomedicine with anti-aging properties. Previously, it has been reported that EP increases the survival rate in mice [23], which is in agreement with our study.

As people age, several sexual functions deteriorate. Age-related declines in male reproductive function have been reported, including impaired spermatogenesis, a decline in Sertoli cell biological function, and disruption of the blood testes barrier-induced immunological barrier [24]. In the present study, control-old rats demonstrated suppression of sperm motility with an increase in the number of morphologically abnormal sperm though the sperm cell concentration was increased. One potentially significant aging-related mechanism that has been suggested is the inflammatory responses, which have been linked to decreased sperm quality, including motility, morphology, and count. Furthermore, in Leydig cells, the inflammatory cytokines TNF- α , IL-1 β , and IL-6 caused dose-dependent decreases in steroidogenesis [25]. The percentage of motile spermatozoa decreases, and the percentage of spermatozoa with cytoplasmic droplets increases in the cauda epididymis [26]. It has been stated that 99% of the young males' sperm have normal morphology [27]. This proportion persisted in the seminal fluid of both middle-aged (12 m) and elderly (24 m) males as well. Furthermore, the old SD rat's sperm production was close to that of younger animals [28]. The anti-inflammatory, antioxidant, and radical-scavenging properties of EP have been reported [29,30] Strong antioxidants are required to stop oxidative damage in the testicle. The protective effects of EP on sperm characteristics in rats have been reported [31]. Cyproterone acetate in EP is thought to reduce oxidative stress in the testes [32]. It has been shown that EP treatment increased sperm motility and decreased sperm abnormalities [33], which support our findings. Additionally, the higher testosterone level, testes, and prostate weight in the EP treated group than the control-old group may explain the higher sperm concentration and motility, respectively, in the EP treated rats when compared to the control-old rats.

Male reproductive function is impacted by aging on a number of levels, including sperm production and quality as well as the structure and histology of the male reproductive system. As the organism ages, the spermatogenesis microenvironment made up of the Sertoli and Leydig cells shows notable anomalies such as decreasing numbers, morphological changes, organelle aging, aberrant hormone secretion, and deficits in the blood-testicular barrier [24]. GnRH is released by the hypothalamus, and it causes the pituitary gland to release FSH and LH, which are both essential for the functioning of the male reproductive system [34]. GnRH decreases with age, leading to decreased LH production [35]. Furthermore, the gonadotropin response to exogenous GnRH is compromised by age [36]. Inadequate LH secretion was the primary cause of low testosterone levels [37]. Reduced testosterone production in response to LH is a characteristic of elderly Leydig cells [38,39]. Oxidative stress can interrupt the Leydig cells' steroidogenic capability in rats [40]. Testosterone levels were found to drop after 24 m and at 30 m in Brown Norway rats [26] and even at 15 m old male Wistar rats [41]. The signs of aging start to appear in rats after 6–7 m [42]. Although SD rats at the age of 12 m have been considered to be old [43]. However, in the present study, the concentrations of GnRH, LH, FSH, and testosterone were elevated in the control-old rats, which are equivalent to middle-aged humans [44].

Immunoglobulins (Igs) are glycoproteins that are produced by B cells. They mediate humoral immunity by neutralizing viruses and destroying foreign objects [45]. Under normal circumstances, T helper-2 (Th-2) cells use anti-inflammatory cytokines (IL-10, IL-6, and IL-4) to promote humoral immunity and increase the generation of antibodies. These cytokines drive B cells to develop into IgG, IgM, and IgE antibodies [46]. As a result, decreased Th-2 cell function can lower IgG and IgM [47]. Administering EP to albino rats prevented lead-induced decreases in IgG and IgM levels [48]. In the present study, EP treatment improved the plasma concentration of IgG, IgM, and IgD. The hematopoietic system is stimulated by the contents of EP, such as cichoric acid and echinacin, which may be responsible for this improvement [49].

Systemic chronic inflammation is the hallmark of aging, and it results in immunosenescence, cellular senescence, organ failure, and diseases associated with aging [50]. Immune, hormonal, and adipose changes associated with aging generate a chronic inflammatory state [51]. It is thought that cytokine dysregulation is a major factor in the immune system's remodeling at aging. Aging raises basal expression of inflammatory cytokines [52]. Aging is negatively impacted by levels of proinflammatory cytokines, primarily TNF- α and IL-6 [51]. EP root contained a fairly great amount of cichoric acid [53]. Cichoric acid exhibits antioxidant, antiviral, and anti-inflammatory properties. Furthermore, cichoric acid may reduce matrix metalloproteinase-3 activity and inflammation brought on by lipopolysaccharides in both mice and cell cultures. This suggests that cichoric acid may have beneficial impacts on aging [54]. In lead-injected rats, the administration of EP extract enhances the decreased levels of IL-10 [27,55] which is in agreement with our results (Figure 4A). IL2 plays a pivotal role in immune responses; it is an important immunoregulator. It is necessary for the proliferation of activated T cells, the differentiation of Th cells, into Th1 and Th2 cells and the improvement of NK cell activity [56]. Therefore, it is not surprising that the decline in IL-2 production assists in age-related immune hypofunction. A decrease in the ability of lymphocyte populations from elderly animals to produce IL-2 is the cause of the decline in IL-2 production with advancing age [57], which is contrary to our results as the blood levels of IL-2 were elevated in the control-old and old-treated groups than young ones (Figure 4B). It has been reported that EP treatment decreases the levels of IL-2 and TNF- α in rats and mice's blood [58]. The pro-inflammatory cytokine IL-1 β expression increased in the brain and the spleen of aged Fischer rats [59], which is contrary to our findings where the level of IL-1 β declined with the progress of age (Figure 4C), which may be attributed to rat species. IL-6 is a potent proinflammatory cytokine that enhances T and B lymphocyte proliferation, neutrophil invasion, and prostaglandin formation [60]. Interleukin-6, sometimes known as the "gerontologist's cytokine," has long been recognized to play a significant role in aging and diseases associated with age [61]. IL-6 signaling may represent a key pathway involved in aging and diseases [62]. It has both pro- and anti-inflammatory activities [52]. While elevated systemic levels of IL-6 can cause pro-inflammatory, pro-oxidant, and pro-fibrotic reactions, low and/or controlled IL-6 release is linked to anti-inflammatory, antioxidant, and pro-myogenic effects [62]. In the present study, the levels of IL-6 were inhibited by aging and further suppressed by EP treatment. It has been observed that administration of EP lowers the amounts of IL-6 in the rats [48]. TNF- α It is a pro-inflammatory mediator that, when released systemically, can be extremely detrimental yet beneficial when acting locally in the tissues [52]. An age-dependent rise in TNF- α expression in the spleen and brain of aged rats has been reported [59], which supports our study that shows elevated blood levels of TNF- α in the control-old group and the levels were improved by EP treatment (Figure 4E), which is contrary to [33,63] who reported that TNF- α levels were decreased in the EP treated rats. Both quantitative and qualitative changes in the immune system occur as cytokine dysregulation with aging [51]. The main regulator of the innate and adaptive immune systems is NF-kB [64], which is always activated, leading to the chronic activation of immune cells associated with aging [65]. NF-kB activation is linked to both apoptosis and the prevention of cell death. It has been reported that EP extracts raise NF-kB's nuclear content [66]. In the present study, the blood concentration of NF-kB was increased in aged rats, and the levels were enhanced by EP treatment (Figure 4F). While Mao et al, reported that the level of NF-kB decreased in EP-treated rats [33].

Oxidative stress is one of the many processes that have been proposed to contribute significantly to the aging process. The hallmarks of aging are facilitated by oxidative damage, which is also a necessary component

of pathogenic pathways that are thought to be responsible for several age-related disorders [67]. When antioxidant defense mechanisms and ROS generation are out of balance, aging eventually leads to low-quality proteins, lipids, and DNA [68]. It has been found that aged Brown Norway rat spermatozoa produce more ROS and have lower levels of the enzymes glutathione peroxidase and SOD [69]. Additionally, ROS causes abnormalities in sperm by interfering with the germinal epithelium during the development of normal spermatozoa [70]. Oxidative stress and inflammation are intrinsically linked because ROS can activate transcription factors that might cause inflammation, like NF- κ B and AP-1 [71]. One potentially significant aging-related mechanism that has been suggested is the inflammatory response. Inflammatory response and decreased sperm quality including, sperm count, motility, and morphology, have been related [25]. Concerning testes, lipid peroxidation is the term describing the reaction that occurs between ROS and lipids, and MDA is regarded as the biomarker for lipid peroxidation. Following treatment with EP extract, the MDA level was reduced in testicular tissue and sperm [48,63]. Mao et al, reported that MDA production was dramatically decrease by increasing EP dose in obese rats[33], which supports our results (Figure5C). According to a prior study in mice, EP boosted peripheral blood antioxidant activity [72]. Significantly longer life spans were observed in transgenic mice with elevated levels of CAT [73]. Treatment with medium and high doses of EP extract increased the SOD activity and decreased the levels of oxidative stress indicators [33]. In the present study, the activity of the antioxidant enzymes was increased by aging and amplified by EP treatment.

Caspases are essential apoptosis mediators. Among them, caspase-3 is a death protease that is regularly activated and that specifically cleaves a lot of important cellular proteins. The pro-apoptotic caspase-3 protein's gene expression is upregulated by NF κ B [74]. There have been reports of elevated caspase-3, caspase-6, and caspase-7 enzymatic activity in the lung and spleen of aged rats [75]. There is a strong correlation between altered caspase-3 activity and aging [76]. These data support our findings that the testes and spleen of the control-old group expressed the highest level of caspase-3; however, administration of EP downregulated caspase-3 mRNA expression levels. In vitro and in vivo, a polysaccharide from EP reduces oxidative stress while upregulating caspase-3 in the kidney [77].

PGC-1 α is more than just a simple transcriptional coactivator; it regulates the biochemical environment of mitochondrial dynamics, which in turn regulates physiological processes such as inflammation, autophagy, primary metabolism, tissue remodeling, and redox balance [78]. PGC-1 α is required for the induction of ROS-detoxifying enzymes under oxidative stress conditions. This highlights how PGC-1 α controls the state of oxidative stress [79]. In the aging liver, PGC-1 α is necessary to sustain the capacity for autophagy and mitophagy [80]. Age-associated decreases in PGC-1 α itself are a vital contributing factor in the reduced mitochondrial function related to aging [81]. In our study, age induced a reduction in PGC-1 α mRNA expression levels, and EP treatment induced a further reduction in the mRNA expression levels of PGC-1 α .

Sirtuins are Nicotinamide Adenine Dinucleotide-dependent Class III histone deacetylase enzymes present in lower to higher organisms and play an important role in the regulation of various vital cellular functions during metabolism and aging. It also plays a neuroprotective role by modulating several biological pathways such as apoptosis, DNA repair, protein aggregation, and inflammatory processes associated with aging and neurodegenerative diseases [82]. SIRT1 transforms inactive PGC-1 α into active form, and active PGC-1 α increases Nrf1 and Nrf2 expression, which operate on the nuclear genes encoding the oxidative phosphorylation system's components [83]. In rats, PGC-1 α and SIRT1 expression in testicular tissue decrease with aging [10]. In mice, SIRT1 expression decreases with age. On the other hand, mice, yeast, and *Caenorhabditis elegans* can all live longer when SIRT1 expression is elevated [84]. The antioxidant and anti-inflammatory properties of SIRT1 are widely recognized [85]. Through the Foxo pathway, several longevity factors, such as SIRT1, can promote the expression of antioxidants and combat oxidative stress [86]. Additionally, it controls inflammation by modifying several pro-inflammatory mediators; specifically, it suppresses NF- κ B signaling, a significant trigger of inflammatory reactions [87]. SIRT1 inhibition amplifies NF- κ B signaling, which in turn causes inflammatory responses and further modifies many of its downstream mediators [88]. On the other hand, stress and age-related illnesses both increase SIRT1. In the present study,

an age-induced reduction in SIRT-1 mRNA expression levels has been shown. A significant decline in SIRT1 was observed in older endothelial cells [89]. The decreased activity of SIRT1 in the aging rat brain has been reported [90]. Moreover, decreased SIRT1 activity but no expression in the skeletal muscle of aged rats has been demonstrated [91]. In addition, Gong et al. [92] reported that SIRT1 expression is decreased with age at the transcriptional and translational levels in the brain, liver, skeletal muscle, and white adipose tissue in senescence-accelerated mouse prone and a control counterpart strain, senescence-accelerated mouse resistant. Echinacosides extracted from EP roots, have been shown to upregulate the SIRT1 level [93], contrary to our study in which the SIRT1 level was decreased by EP treatment. The reason for such discrepancy remains to be elucidated.

Conclusion

In conclusion, EP may be a potential anti-aging strategy through its positive influence on the survival rate and the physiology of the immune and reproductive systems in male rats.

Conflict of interest

The authors declare no conflicts of interest, financial or otherwise.

References:

1. Dharmarajan, T. (2021). Physiology of aging. *Geriatric gastroenterol*, 101-153.
2. Taffet, G.E. (2024). Physiology of aging Geriatric Medicine: A Person Centered Evidence Based Approach (pp. 1555-1565): *Springer*
3. Li, Z., Zhang, Z., Ren, Y., Wang, Y., Fang, J., Yue, H. and Guan, F. (2021). Aging and age-related diseases: from mechanisms to therapeutic strategies. *Biogerontol*, 22(2), 165-187.
4. Viña, J., Borrás, C. and Miquel, J. (2007). Theories of ageing. *IUBMB life*, 59(4-5), 249-254.
5. Hayflick, L. (2007). Biological aging is no longer an unsolved problem. *Annals the new York Academy Sci*, 1100(1), 1-13.
6. Karol, D. (2009). *Party posit. change Amer. politics: Coalition management*: Cambridge University Press.
7. Khajehnasiri, F., Mortazavi, S.B., Allameh, A., Akhondzadeh, S. and Hashemi, H. (2013). Total antioxidant capacity and malondialdehyde in depressive rotational shift workers. *J. environm. pub. health*, 2013.
8. Vitale, G., Salvioli, S. and Franceschi, C. (2013). Oxidative stress and the ageing endocrine system. *Nat. Rev. Endocrinol*, 9(4), 228-240
9. Michaud, M., Balardy, L., Moulis, G., Gaudin, C., Peyrot, C., Vellas, B. and Nourhashemi, F. (2013). Proinflammatory cytokines, aging, and age-related diseases. *J. Amer. Med. Direct. Assoc*, 14(12), 877-882.
10. Silva, J.V., Santiago, J., Matos, B., Henriques, M.C., Patrício, D., Martins, A.D. and Oliveira, P. (2022). Effects of age and lifelong moderate-intensity exercise training on rats' testicular function. *Int. j. molec. sci*, 23(19), 11619.
11. Dong, S., Chen, C., Zhang, J., Gao, Y., Zeng, X. and Zhang, X. (2022). Testicular aging, male fertility and beyond. *Front. endocrinol*, 13, 1012119.
12. Li, Y.J., Han, Z., Ge, L., Zhou, C.J., Zhao, Y.F., Wang, D.H. and Liang, C.G. (2016). C-phycoyanin protects against low fertility by inhibiting reactive oxygen species in aging mice. *Oncotarget*, 7(14), 17393.
13. Saema, S., Shaheen, N. and Pandey, V. (2023). Immunostimulatory Properties of Echinacea purpurea and Conservation Strategy *PlantsImmun. Conser. Strateg* (pp. 153-168): Springer.
14. Dosoky, N.S., Kirpotina, L.N., Schepetkin, I A., Khlebnikov, A.I., Lisonbee, B.L., Black, J.L. and Satyal, P. (2023). Volatile composition, antimicrobial activity, and in vitro innate immunomodulatory activity of Echinacea purpurea (L.) Moench essential oils. *Molec*, 28(21), 7330.
15. Weiskopf, D., Weinberger, B. and Grubeck-Loebenstien, B. (2009). The aging of the immune system. *Transp. int*, 22(11), 1041-1050.
16. Khattab, H.A., Abounasef, S.K. and Bakheet, H.L. (2019b). The biological and hematological effects of Echinacea purpurea L. Roots extract in the immunocompromised rats with cyclosporine. *J. Microsc. Ultrastruc*, 7(2), 65.
17. Vahl, T. P., Ulrich-Lai, Y. M., Ostrander, M. M., Dolgas, C. M., Elfers, E. E., Seeley, R. J. and Herman, J. P. (2005). Comparative analysis of ACTH and corticosterone sampling methods in rats. *Amer. J. Physiol-Endocrinol Metab*, 289(5), E823-E828.
18. Slott, V.L., Suarez, J.D. and Perreault, S.D. (1991). Rat sperm motility analysis: methodologic considerations. *Reproduc. Toxicol*, 5(5), 449-458.

19. Robb, G., Amann, R. and Killian, G. (1978). Daily sperm production and epididymal sperm reserves of pubertal and adult rats. *Reproduc*, 54(1), 103-107.
20. Livak, K.J. and Schmittgen, T.D. (2001). Analysis of relative gene expression data using real-time quantitative PCR and the 2- $\Delta\Delta$ CT method. *methods*, 25(4), 402-408.
21. Suvarna, K.S., Layton, C. and Bancroft, J.D. (2018). Bancroft's theory and practice of histological techniques E-Book: *Elsevier health sciences*.
22. Li, Z., Zhang, Z., Ren, Y., Wang, Y., Fang, J., Yue, H. and Guan, F. (2021). Aging and age-related diseases: from mechanisms to therapeutic strategies. *Biogerontol*, 22, 165-187.
23. Brousseau, M. and Miller, S.C. (2005). Enhancement of natural killer cells and increased survival of aging mice fed daily Echinacea root extract from youth. *Biogerontol*, 6(3), 157-163.
24. Santiago, J., Silva, J.V., Alves, M.G., Oliveira, P.F. and Fardilha, M. (2019). Testicular aging: an overview of ultrastructural, cellular, and molecular alterations. *J. Gerontol: Series A*, 74(6), 860-871.
25. Leisegang, K. and Henkel, R. (2018). The in vitro modulation of steroidogenesis by inflammatory cytokines and insulin in TM3 Leydig cells. *Reproductive Biology and Endocrinology*, 16(1), 1-11.
26. SYNTIN, P. and ROBAIRE, B. (2001). Sperm structural and motility changes during aging in the Brown Norway rat. *J. Androl*, 22(2), 235-244.
27. Pichardo, A. I., Tlachi-López, J. L., Jiménez-Trejo, F., Fuentes-Farías, A. L., Báez-Saldaña, A., Molina-Cerón, M. L. and Lucio, R. A. (2011). Increased serotonin concentration and tryptophan hydroxylase activity in reproductive organs of copulator males: a case of adaptive plasticity. *Advanc. Biosci. Biotech*, 2(02), 75-84.
28. JOHNSON, L., & NEAVES, W. B. (1983). Enhanced daily sperm production in the remaining testis of aged rats following hemicastration. *J. Androl*, 4(2), 162-166.
29. El-Demerdash, F.M., Karhib, M.M., Ghanem, N.F., Abdel-Daim, M.M. and El-Sayed, R.A. (2024). Echinacea purpurea root extract mitigates hepatotoxicity, genotoxicity, and ultrastructural changes induced by hexavalent chromium via oxidative stress suppression. *Environ. Sci. Poll. Res*, 1-13.
30. Burlou-Nagy, C., Bănică, F., Jurca, T., Vicaș, L.G., Marian, E., Muresan, M.E. and Pallag, A. (2022). Echinacea purpurea (L.) Moench: Biological and pharmacological properties. A review. *Plants*, 11(9), 1244.
31. Motamedi, S., Asghari, A., Jahandideh, A., Abedi, G. and Mortazavi, P. (2018). Effects of Echinacea purpurea extract on sperm characteristics and hematology following testicular ischemia-reperfusion injury in rat. *Crescent J. Med. Biol. Sci*, 5, 119-122.
32. Arafa, N.M. (2010). Efficacy of Echinacea on the action of cyproterone acetate in male rats. *Pakistan J Biol Sci*, 13(20), 966.
33. Mao, C.F., Sudirman, S., Lee, C.C., Tsou, D. and Kong, Z.L. (2021). Echinacea purpurea ethanol extract improves male reproductive dysfunction with streptozotocin-nicotinamide-induced diabetic rats. *Front. veter. sci*, 8, 651286
34. Odetayo, A. F., Akhigbe, R. E., Bassey, G. E., Hamed, M. A. and Olayaki, L. A. (2024). Impact of stress on male fertility: role of gonadotropin inhibitory hormone. *Front. endocrinol*, 14, 1329564.
35. Brawer, M.K. (2004). Testosterone replacement in men with andropause: an overview. *Rev. urol*, 6(Suppl 6), S9.
36. Veldhuis, J.D., Keenan, D.M., Liu, P.Y., Iranmanesh, A., Takahashi, P.Y. and Nehra, A. X. (2009). The aging male hypothalamic-pituitary-gonadal axis: Pulsatility and feedback. *Molec. cell. endocrinol*, 299(1), 14-22.
37. Sawlani, S., Saini, R., Vuppuluri, R., Rojas, L., Patel, M. and Patel, P. (2016). Endocrine changes with aging. *Endocrinol. Metab. Int J*, 3(6), 133-143.
38. Wang, Y., Chen, F., Ye, L., Zirkin, B. and Chen, H. (2017). Steroidogenesis in Leydig cells: effects of aging and environmental factors. *Reproduc*, 154(4), R111-R122.
39. Ketchem, J.M., Bowman, E.J. and Isales, C.M. (2023). Male sex hormones, aging, and inflammation. *Biogerontol*, 24(1), 1-25.
40. Monageng, E., Offor, U., Takalani, N. B., Mohlala, K. and Opuwari, C. S. (2023). A review on the impact of oxidative stress and medicinal plants on Leydig cells. *Antioxid*, 12(8), 1559.
41. Bakhtyukov, A., Derkach, K., Dar'in, D., Sharova, T. and Shpakov, A. (2019). Decrease in the Basal and Luteinizing Hormone Receptor Agonist-Stimulated Testosterone Production in Aging Male Rats. *Advanc. Gerontol*, 9, 179-185.
42. Sudakov, S.K., Alekseeva, E.V., Nazarova, G.A. and Bashkatova, V.G. (2021). Age-related individual behavioural characteristics of adult wistar rats. *Animals*, 11(8), 2282.
43. Meyer Jr, R.A., Desai, B.R., Heiner, D.E., Fiechtl, J., Porter, S. and Meyer, M.H. (2006). Young, adult, and old rats have similar changes in mRNA expression of many skeletal genes after fracture despite delayed healing with age. *J. orthop. res*, 24(10), 1933-1944.
44. Collier, T. J. and Coleman, P. D. (1991). Divergence of biological and chronological aging: evidence from rodent studies. *Neurobiol. aging*, 12(6), 685-693.
45. Greenspan, N.S. and Cavacini, L.A. (2019). Immunoglobulin function. *Clin. Immunol*, (pp. 223-233. e221): Elsevier.
46. Zhu, J. (2015). T helper 2 (Th2) cell differentiation, type 2 innate lymphoid cell (ILC2) development and regulation of interleukin-4 (IL-4) and IL-13 production. *Cytokine*, 75(1), 14-24.

47. Hassanen, E.I., Khalaf, A.A., Tohamy, A.F., Mohammed, E.R. and Farroh, K.Y. (2019). Toxicopathological and immunological studies on different concentrations of chitosan-coated silver nanoparticles in rats. *Int. J. nanomed*, 4723-4739.
48. Mahmoud, A.H., Abbas, M.M. and Abdelmonem, H.A. (2022). The Antioxidant Effects of Cerium Oxide Nanoparticles and Echinacea Purpurea against Lead-induced Immunosuppression in Male Albino Rats. *Egyp. J. Hospital Med*, 89(2), 6106-6114.
49. Goel, V., Chang, C., Slama, J.V., Barton, R., Bauer, R., Gahler, R. and Basu, T. K. (2002). Alkylamides of Echinacea purpurea stimulate alveolar macrophage function in normal rats. *Internat. immunopharmacol*, 2(2-3), 381-387.
50. Li, X., Li, C., Zhang, W., Wang, Y., Qian, P. and Huang, H. (2023). Inflammation and aging: signaling pathways and intervention therapies. *Signal Transduc. Target. Therapy*, 8(1), 239.
51. Khattab, H.A., Abounasef, S.K. and Bakheet, H.L. (2019a). The biological and hematological effects of Echinacea purpurea L. Roots extract in the immunocompromised rats with cyclosporine. *J. Microsc. Ultrastruc*, 7(2), 65.
52. Rea, I.M., Gibson, D.S., McGilligan, V., McNerlan, S.E., Alexander, H.D. and Ross, O. A. (2018). Age and age-related diseases: role of inflammation triggers and cytokines. *Front. immunol*, 9, 334076.
53. Hu, C. and Kitts, D. D. (2000). Studies on the antioxidant activity of Echinacea root extract. *J. agricult. food chemis*, 48(5), 1466-1472.
54. Yang, G., Li, K., Liu, C., Peng, P., Bai, M., Sun and Wu, H. (2018). A comparison of the immunostimulatory effects of polysaccharides from tetraploid and diploid Echinacea purpurea. *BioMed. res. int*, 2018.
55. Zhai, Z., Liu, Y., Wu, L., Senchina, D.S., Wurtele, E.S., Murphy, P.A. and Cunnick, J.E. (2007). Enhancement of innate and adaptive immune functions by multiple Echinacea species. *J. med food*, 10(3), 423-434.
56. Mosmann, T.R. and Sad, S. (1996). The expanding universe of T-cell subsets: Th1, Th2 and more. *Immunol Today*, 17(3):138-46.
57. Wu, W., Pahlavani, M., Cheung, H.T. and Richardson, A. (1986). The effect of aging on the expression of interleukin 2 messenger ribonucleic acid. *Cell. immunol*, 100(1), 224-231.
58. Yu, D., Yuan, Y., Jiang, L., Tai, Y., Yang, X., Hu, F. and Xie, Z. (2013). Anti-inflammatory effects of essential oil in Echinacea purpurea L. *Pak. J. Pharm. Sci*, 26(2), 403-408.
59. Gelinis, D.S. and McLaurin, J. (2005). PPAR- α expression inversely correlates with inflammatory cytokines IL-1 β and TNF- α in aging rats. *Neurochem. Res*, 30, 1369-1375.
60. Lee, J.C., Laydon, J.T., McDonnell, P. C., Gallagher, T. F., Kumar, S., Green, D. and Land Vatter, S. W. (1994). A protein kinase involved in the regulation of inflammatory cytokine biosynthesis. *Nature*, 372(6508), 739-746.
61. Ershler, W.B. and Keller, E.T. (2000). Age-associated increased interleukin-6 gene expression, late-life diseases, and frailty. *Ann. rev. med*, 51(1), 245-270.
62. Forcina, L., Franceschi, C. and Musarò, A. (2022). The hormetic and hermetic role of IL-6. *Ageing res. rev*, 80, 101697.
63. Kong, Z.-L., Johnson, A., Ting, T.-L., Cheng, P.-J. and Mao, C.-F. (2021). Protective effects of Echinacea purpurea ethanol extract on male reproductive dysfunction in obese rats. *App. Sci*, 11(5), 2392.
64. Salminen, A., Kauppinen, A., Suuronen, T. and Kaarniranta, K. (2008). SIRT1 longevity factor suppresses NF- κ B-driven immune responses: regulation of aging via NF- κ B acetylation? *Bioessays*, 30(10), 939-942.
65. Lavrovsky, Y., Chatterjee, B., Clark, R. and Roy, A. (2000). Role of redox-regulated transcription factors in inflammation, aging and age-related diseases. *Exp. gerontol*, 35(5), 521-532.
66. Sharma, M., Arnason, J. and Hudson, J. (2006). Echinacea extracts modulate the production of multiple transcription factors in uninfected cells and rhinovirus-infected cells. *Phytotherapy Research: Int. J. Devoted Pharmacol. Toxicol. Evaluat. Natur. Prod. Derivat*, 20(12), 1074-1079.
67. Luo, J., Mills, K., le Cessie, S., Noordam, R. and van Heemst, D. (2020). Ageing, age-related diseases and oxidative stress: What to do next? *Ageing res rev*, 57, 100982.
68. Sies, H., Berndt, C. and Jones, D.P. (2017). Oxidative stress. *Annual review of biochemistry*, 86, 715-748.
69. Weir, C.P. and Robaire, B. (2007). Spermatozoa have decreased antioxidant capacity and increased reactive oxygen species production during aging in the Brown Norway rat. *Journal of Andrology*, 28(2), 229-240.
70. Chianese, R. and Pierantoni, R. (2021). Mitochondrial reactive oxygen species (ROS) production alters sperm quality. *Antioxid*, 10(1), 92.
71. Vaidya, F. U., Chhipa, A. S., Sagar, N. and Pathak, C. (2020). Oxidative stress and inflammation can fuel cancer. *Role oxid. stress pathophysiol. diseas*, 229-258.
72. Mishima, S., Saito, K., Maruyama, H., Inoue, M., Yamashita, T., Ishida, T. and Gu, Y. (2004). Antioxidant and immuno-enhancing effects of Echinacea purpurea. *Biol Pharm. Bulletin*, 27(7), 1004-1009.
73. Karol, M.H. (2009). How environmental agents influence the aging process. *Biomolec. & Therap*, 17(2), 113-124.
74. Mehmeti, I., Lenzen, S. and Lortz, S. (2011). Modulation of Bcl-2-related protein expression in pancreatic beta cells by pro-inflammatory cytokines and its dependence on the antioxidative defense status. *Molec. cell. endocrinol*, 332(1-2), 88-96.
75. Zhang, J., Patel, J. M. and Block, E. R. (2002). Enhanced apoptosis in prolonged cultures of senescent porcine pulmonary artery endothelial cells. *Mech. ageing develop*, 123(6), 613-625.

76. Ohnishi, T., Yamada, K., Iwasaki, K., Tsujimoto, T., Higashi, H., Kimura, T. and Sudo, H. (2019). Caspase-3 knockout inhibits intervertebral disc degeneration related to injury but accelerates degeneration related to aging. *Scient. repor.* 9(1), 19324.
77. Hou, R., Xu, T., Li, Q., Yang, F., Wang, C., Huang, T., & Hao, Z. (2020). Polysaccharide from *Echinacea purpurea* reduce the oxidant stress in vitro and in vivo. *Internat. J. biolog. macromolec.* 149, 41-50.
78. de Sousa Neto, I.V., Pinto, A.P., Muñoz, V.R., de Cássia Marqueti, R., Pauli, J.R., Ropelle, E.R. and da Silva, A.S.R. (2023). Pleiotropic and multi-systemic actions of physical exercise on PGC-1 α signaling during the aging process. *Ageing res. rev.* 101935.
79. Kong, X., Wang, R., Xue, Y., Liu, X., Zhang, H., Chen, Y. and Chang, Y. (2010). Sirtuin 3, a new target of PGC-1 α , plays an important role in the suppression of ROS and mitochondrial biogenesis. *PLoS one*, 5(7), e11707.
80. Christensen, N. M., Ringholm, S., Buch, B. T., Gudiksen, A., Halling, J. F. and Pilegaard, H. (2023). Muscle Pgc-1 α modulates hepatic mitophagy regulation during aging. *Exp. gerontol.* 172, 112046.
81. Gonzalez, A. A., Kumar, R., Mulligan, J.D., Davis, A.J. and Saupé, K.W. (2004). Effects of aging on cardiac and skeletal muscle AMPK activity: basal activity, allosteric activation, and response to in vivo hypoxemia in mice. *Amer. J. Physiol-Reg, Integrat Compar. Physiol.* 287(5), R1270-R1275.
82. Bhatt, V. and Tiwari, A.K. (2023). Sirtuins, a key regulator of ageing and age-related neurodegenerative diseases. *Int. J. Neurosci.* 133(10), 1167-1192.
83. Wang, Y., Li, J., Gu, J., He, W., Ma, B. and Fan, H. (2022). Hyperoside, a natural flavonoid compound, attenuates Triptolide-induced testicular damage by activating the Keap1-Nrf2 and SIRT1-PGC1 α signalling pathway. *J. Pharm. Pharmacol.* 74(7), 985-995.
84. Chen, C., Zhou, M., Ge, Y. and Wang, X. (2020). SIRT1 and aging related signaling pathways. *Mech. ageing devel.* 187, 111215.
85. Singh, V. and Ubaid, S. (2020). Role of silent information regulator 1 (SIRT1) in regulating oxidative stress and inflammation. *Inflamm.* 43, 1589-1598.
86. Wang, Y. Q., Cao, Q., Wang, F., Huang, L. Y., Sang, T. T., Liu, F. and Chen, S. Y. (2015). SIRT1 protects against oxidative stress-induced endothelial progenitor cells apoptosis by inhibiting FOXO3a via FOXO3a ubiquitination and degradation. *J.cell. physiol*230(9), 2098-2107.
87. Gano, L.B., Donato, A.J., Pasha, H.M., Hearon Jr, C.M., Sindler, A.L. and Seals, D.R. (2014).The SIRT1 activator SRT1720 reverses vascular endothelial dysfunction, excessive superoxide production, and inflammation with aging in mice. *Amer. J. Physiol. Heart Circ. Physiol.* 307(12), H1754-H1763.
88. Kauppinen, A., Suuronen, T., Ojala, J., Kaarniranta, K. and Salminen, A. (2013). Antagonistic crosstalk between NF- κ B and SIRT1 in the regulation of inflammation and metabolic disorders. *Cell. signal.* 25(10), 1939-1948.
89. Conti, V., Corbi, G., Simeon, V., Russomanno, G., Manzo, V., Ferrara, N. and Filippelli, A. (2015). Aging-related changes in oxidative stress response of human endothelial cells. *Ageing clin. exp. res.* 27, 547-553.
90. Braidy, N., Guillemin, G.J., Mansour, H., Chan-Ling, T., Poljak, A. and Grant, R. (2011). Age related changes in NAD⁺ metabolism oxidative stress and Sirt1 activity in wistar rats. *PLoS one*, 6(4), e19194.
91. Koltai, E., Szabo, Z., Atalay, M., Boldogh, I., Naito, H., Goto, S. and Radak, Z. (2010). Exercise alters SIRT1, SIRT6, NAD and NAMPT levels in skeletal muscle of aged rats. *Mech. ageing develop.* 131(1), 21-28.
92. Gong, H., Pang, J., Han, Y., Dai, Y., Dai, D., Cai, J. and Zhang, T.M. (2014). Age-dependent tissue expression patterns of Sirt1 in senescence-accelerated mice. *Molec. med. rep.* 10(6), 3296-3302.
93. Hu, G.S., Hur, Y.J., Jia, J. M., Lee, J.H., Chung, Y.S., Yi, Y.B. and Kim, D.H. (2011). Effects of 2-aminoindan-2-phosphonic acid treatment on the accumulation of salidroside and four phenylethanoid glycosides in suspension cell culture of *Cistanche deserticola*. *Plant cell rep.* 30, 665-674.