

<https://doi.org/10.33472/AFJBS.6.5.2024.3562-3582>



African Journal of Biological Sciences

Journal homepage: <http://www.afjbs.com>



Research Paper

Open Access

## Protective effect of morin against arsenic neurotoxicity on the brain of Wistar rats.

Praveen Nadipolla 1, Bhaskar Nagilla 2, Pratap Reddy Karnati 3\*

1. Department of Zoology, University College of Science, Osmania University, Hyderabad, Telangana 500 007, India.8639748867
2. Department of Zoology, University College of Science, Osmania University, Hyderabad, Telangana 500 007, India.9581388447
3. Department of Zoology, University College of Science, Osmania University, Hyderabad, Telangana 500 007, India.

\*Correspondence: Department of Zoology, University College of Science, Osmania University, Hyderabad, Telangana 500 007, India.9573935381

Article History

Received: 17 Feb 2024

Accepted: 15 Mar 2024

Published: 15 May 2024

### Abstract

Modern medicine has involved the search for novel medications made from plant extracts. One such substance with several uses in human welfare is Morin. A metal contaminant that affects people everywhere is arsenic. The effectiveness of Morin was examined here in relation to the neurotoxicity of arsenic in rats. On days 7, 14, 21, and 28 of the trial, rat's cognitive abilities were assessed using the Morris Water Maze, the Depression Test, and the Novel Object Recognition Test. In addition to estimating the levels of Acetyl Choline (Ach), dopamine, epinephrine, and norepinephrine in brain tissues, a histology investigation of the brain using two distinct stains H&E and Cresyl violet was also carried out. The Morin therapy has improved skills such as spatial and retention memory, according to the Morris Water Maze test. The Novel Objects Recognition test also showed improvement. There were no signs of depression during the Morin therapy. According to the findings, Morin therapy significantly (P) improved the content of dopamine, epinephrine, Non epinephrine, and Ach. Significant improvements in the architecture of the brain have been seen in histological studies of the hippocampus and cerebral cortex with H&E and Cresyl violet stain. Thus it can conclude that Morin is significantly beneficial in reducing Arsenic toxicity in rats.

**Keywords:** Morin, Acetyl choline, dopamine, epinephrine, norepinephrine, Hippocampus

## Introduction

Arsenic (As) is a metalloid element that can be found in substantial quantities in the soil, water, and air. Furthermore, it is released into the environment by anthropogenic processes such as the production of pesticides and herbicides, glass manufacturing, semiconductor manufacturing, metal smelting, and mining waste. Agriculture (fertilizer, pesticide/herbicide, animal waste, and irrigation water) and Industry (chemicals, paints, tanning) are two sources of arsenic that are linked to anthropogenic activity. Other sources include metal mining, sewage, smelting, and municipal solid waste. Additionally, weathering of rock and minerals comes from Geogenic causes. Humans who drink water contaminated with arsenic gradually develop cancer in almost all organs, including the liver, kidneys, heart, lungs, central nervous system (CNS), gastrointestinal, and skin diseases like hyperpigmentation and hyperkeratosis. Increased morbidity and mortality is due to reproductive issues and intellectual impairment in offspring [1, 2]. In the majority of instances, exposure to arsenic at work or from the environment leads to poisoning. Millions of individuals throughout the world are affected by arsenic toxicity, which has been associated with disorders of the gastrointestinal, pulmonary, cardiovascular, neurological, genitourinary, endocrine, hematopoietic system, and skin (3).

The first lines of defence provided by antioxidant enzymes like superoxide dismutase (SOD), catalase (CAT), peroxidase (POD), and glutathione reductase (GSR) were severely inhibited by arsenic exposure, and the production of oxygen and oxygen-derived free radicals known as reactive oxygen species increased.[4,5] Studies have revealed that arsenic has severe effects on learning, memory, and cognitive impairments in animals, indicating that the brain is a vital location for arsenic-induced damage [6]. Multiple forms of organic and inorganic arsenicals observed to accumulate in various regions of the brain [7]. The blood-brain barrier is easily crossed by arsenic, which further enhances its buildup in various brain regions, resulting in an array of neurological diseases [8]. Arsenic interferes with the morphological and physiological changes that occur in brain cells. The brain is vulnerable to oxidative stress because it needs a lot of energy, and arsenic exposure damages the brain by reducing its antioxidant enzymes [9]. One of the main mechanisms of arsenic-induced neurotoxicity is increased oxidative stress [10].

Morin (3, 5, 7, 2', 4' -pentahydroxyflavone) is a flavonoid found in old fustic (*Chlorophora tinctoria*), osage orange (*Maclura pomifera*), almonds (*Prunus guajava* L.), mill (*Prunus dulcis*), fig (*Chlorophora tinctoria*), onion, and apple, as well as other moraceae. Morine is often found naturally in plants, different vegetative parts of plants, and fruits such as almond, guava, onion, apple, tea, red wine, coffee, and cereal grains. It has potent antioxidant and metal ion chelating properties, as well as antioxidation, anti-mutagenesis, anti-inflammation, cardioprotective activities, anticancer, xanthine oxidase inhibitor, protein kinase C inhibitor, and cell proliferation inhibitor properties. Morin is also a well-known medicinal agent for a variety of ailments. Morin has potency in treating rat liver fibrosis through lowering oxidative stress, cytokine production, and nuclear factor kappa [11]. It also protects against lipid peroxidation and lipid profile in ammonium chloride-induced hyperammonemic rats [12], and has a nephroprotective role in experimentally induced diabetic nephropathy (13), diabetic osteopenia [14], antioxidant and neurotoxicity in Zebra fish embryo or larval model [15], memory deficits in Alzheimer's disease rat model [16], encephalopathy and sepsis-associated cognitive functions [17]. Sleep deprivation causes neurobehavioural abnormalities, as well as the death of viable neurons in the hippocampus of mice [18, 19].

Hence, this study reports protective effects of Morin on Neurobehavioral alternations in rats, neurotransmitter levels in Brain and Histological changes in Hippocampus and Cerebral Cortex of Brain of rat, exposed to Arsenic.

## Materials and Methods

Albino Wistar rats were used for experimentation. Three month old rats were obtained from Jeeva life sciences (CPCSEA/IAEC/JLS/16/07/21/44), Hyderabad and maintained under standard laboratory conditions. Animals were divided into four following groups. First group is Group-I – Control (Control); second group Group-II - Arsenic (20mg/Kg Body Wt.,) (Ar) ; Third group is Group-III - Arsenic (20mg/Kg Body Wt.,) + Morin (50mg/kg body wt.,) (Ar+M); Fourth group is Group-IV - Morin (50mg/kg body wt.,) (M) . All animals were treated orally.

**Physical Parameters:** Body weight, Brain weight and Organ somatic index (OSI) (20).

$$\text{OSI} = \frac{\text{Weight of Brain (gm)}}{\text{Weight of Body}} \times 100$$

Weight of Body

## Behavioral studies:

**Rota Rod Test:** This test was conducted using Rotarod instrument (Dolphin). The test was conducted according to the method of Haelewyn *et al.*, 2007 (21). The speed of the instrument was set at 20 RPM.

The initial time was taken as zero seconds, and final time still animal balances itself on the instruments is noted final time.

**Water Morris Maze Learning test:** This test was conducted according to modified Morris, 1984 (22). Initially animals were trained for 5 days prior to day of experiment, in searching the platform to hold on when released in tub containing clear water. On day of experimentation water was not clear so that the platform will not visible to animals and animals should search for it. Time taken to locate platform was noted in seconds.

#### **Objective Recognition Test:**

Different objects of varying shapes and sizes which included white color rectangle, black color triangle, Red color circular and brown color wooden box, were put to use for evaluating the object bias in the recognition of several experimental groups. Each animal was familiarized with specific object during experimentation. On the day of test i.e. on 7<sup>th</sup>, 14<sup>th</sup>, 21<sup>st</sup> and 28<sup>th</sup> day animals were exposed to different objects including its familiar object. All the behaviors including object exploration (recognition) and discrimination are noted down. The time taken to recognition the object was noted in seconds, cut-off was for 600 seconds. (23).

#### **Depression test (Forced Swim test):**

This test was conducted in accordance with Porsolt *et al.*, 1978 (24). A large cylinder was filled with water up to 2/3<sup>rd</sup> of its size; animals were trained in for 15 min every day before experiment. On the day of experiment the animals were introduced into cylinder for forced swimming 90 seconds test with videotaping. Duration of immobility, which was judged as floating or remaining motionless with only minimal motion expended to maintain their head above the water). Duration of immobility was noted to be depression like response. Opposite to this was noted to be the struggling time which is represented in the graph.

#### **Estimation of Neurotransmitters**

Protein quantity in brain tissue was estimation by Lowry *et al.*, 1951, method (25)

**Estimation of monoamines (dopamine, nor-epinephrine, and epinephrine):** Extraction and estimation of these neurotransmitters were carried out according to the method of Kari *et al.*, (1978) (26). The cerebral cortex of the brain tissue was dissected and homogenized (10%) with 0.25M sucrose and centrifuged at 1000rpm at 40C for 10 min. To the supernatant, 1ml of acid Butanol was added, mixed well, and centrifuged at 1000rpm at 40C for 10 min. Butanol layer was taken into a separate test tube and 2.5ml of heptane and 1.5 ml of ddw were added, shaken thoroughly and centrifuged at 1000 rpm for 5 min. The aqueous layer was taken and 200 mg of acid alumina, 1ml of 2M sodium acetate was added mixed well for 5 min, and then adjusted to the pH8 with 1N NaOH. Centrifuged for 5 mins at 1000 rpm. The supernatant was used for the serotonin assay, and the precipitate (acid alumina) was used for the catecholamines (epinephrine, nor-epinephrine), and dopamine estimation.

#### **Acetylcholine (Ach):**

Acetylcholine content was estimated by using hydroxylamine and ferric chloride reagents. A glass homogenizer Potter Elvehjem (Braun, 3508 Melsungen, Germany) with Teflon pestle and a distance between pestle and glass wall of 0.1 mm was used for homogenization. Reagents: 1) Hydroxylamine hydrochloride 2 M. keep in ice cold condition. 2) Alkali Sodium hydroxide 3.5 N 3) acid: 1:2 concentrated hydrochloric and distilled water. 4) Ferric chloride 0.37 M dissolved in 0.1N hydrochloric acid 5) Standard solution was prepared by dissolving acetylthiocholine iodide in 0.004 M sodium acetate solution and pH 4.5 was adjusted using 0.001 N HCL and stored in refrigerator. 10mg of tissue from the cerebral cortex and hippocampus was homogenized in 1ml of 3% perchloric acid then centrifuged for 10 min at 1000rpm and the supernatant was collected for the assay. Hydroxylamine reagent was prepared freshly by mixing the equal volumes of Reagents 1 and 2 and incubated for 3 hours at room temperature. 2 ml of alkaline hydroxylamine reagent was added to 1.0 ml supernatant and before adding 1ml of FeCl<sub>3</sub> solution the pH of was adjusted to 1.5 by adding 0.001 N HCL and mixed well by vortexing. The density of the purple-brown colour of the solution was measured at 540nm (Hestrin, 1949) (27). For calculation of above neurotransmitter parameters, prepared appropriate standard graphs with pure HPLC grade chemicals were obtained from the sigma chemicals and the standard values obtained and graphs, standard curves prepared used for the calculation of test sample fluorescence units and OD. Ach levels were expressed as  $\mu\text{moles}$  of substrate hydrolyzed / min/ mg protein.

#### **Histopathological studies of brain:**

The Histopathological studies were carried out by according to the method of Luna (1968) (28). The tissue sections were made using rotary microtome (model No: 45, LipsheW MFG Co Detroit 10 Michigan L-057).

### H&E Stain

The brain tissues were fixed in 10% formaldehyde for 1 to 2 days. The tissue was hydrated serially in 100%, 75%, 50%, 30% alcohol gradients, and distilled water for 10-15 minutes for every change, followed by dehydration of the tissues with 30%, 50%, 70%, 90% and 100% alcohol for 20 min for every change and cleared the tissue with two changes of xylene for 10 mins, then kept the tissue in wax at 550C (minimum two changes required). The tissues were embedded using melted wax (600C) and the L blocks. The tissues were cut into the 4 micron sections on rotary microtome. The tissue sections were transferred onto the 0.5% gelatin coated slides without wrinkles. The slides were stored overnight in dust free chamber. Next day the tissue sections were deparaffinized with xylene I, xylene II for 30 minutes, then hydrated the tissue with 100%, 90%, 70%, 50%, 30% and dw for 10 minutes every change. Allowed the slides into Harris Hematoxylin stain solution for 5-15 minutes, and then kept the sections under running tap water for 10 minutes. Dehydrated the sections with 30%, 50%, 70%, 90% alcohol for 10 minutes. Transferred the slides into 1% eosin (alcohol soluble) for 30 seconds, then the slides kept in 100% alcohol, and cleared with Xylene I, Xylene II for 10 minutes, allowed air dry and mounted the sections with DPX without air bubbles.

### Cresyl Violet stain

The brain tissues were fixed in 10% formaldehyde for 1 to 2 days. The tissue was hydrated serially in 100%, 75%, 50%, 30% alcohol gradients, and distilled water for 10-15 minutes for every change, followed by dehydration of the tissues with 30%, 50%, 70%, 90% and 100% alcohol for 20 min for every change and cleared the tissue with two changes of xylene for 10 mins, then kept the tissue in wax at 550C (minimum two changes required). The tissues were embedded using melted wax (600C) and the L blocks. The tissues were cut into the 4 micron sections on rotary microtome. The tissue sections were transferred onto the 0.5% gelatine coated slides without wrinkles. The slides were stored overnight in dust free chamber. Next day the tissue sections were deparaffinized with xylene I, xylene II for 30 minutes, then hydrated the tissue with 100%, 90%, 70%, 50%, 30% and dw for 10 minutes every change. Allowed the slide into cresyl violet stain solution for 5-15 minutes, and then kept the sections under running tap water for 10 minutes. Dehydrated the sections with 30%, 50%, 70%, 90% alcohol for 10 minutes. Transferred the slides into 1% eosin (alcohol soluble) for 30 seconds, then the slides kept in 100% alcohol, and cleared with Xylene I, Xylene II for 10 minutes, allowed air dry and mounted the sections with DPX without air bubbles (Luna 1968)(28).

### Statistical analysis

Statistical analysis was carried out using SPSS software. Mean,  $\pm$ SD (standard deviation),  $\pm$ SE (standard error), one way ANOVA variance significance test  $p < 0.05$ , multiple regression, post hoc multiple comparison test between experimental days, Null hypothesis (H0) were performed. The data was presented in tables as Mean  $\pm$  SD, percentage of experimental over control. Graphs were plotted using Mean  $\pm$  SD with origin 6.0 and Sigma Plot 9.0 software.

### Results

**Table 1. Effect of Morin on Body Weight of Arsenic-Treated Rats**

Experimental Days/Groups	Group-I (Control)	Group-II (Ar)	Group-III (Ar+M)	Group-IV (M)	Percentage change over control		
					Group-II	Group-III	Group-IV
Day 7	224.6 $\pm$ 0.455	214.82 $\pm$ 0.490	220.8 $\pm$ 0.670	222.21 $\pm$ 1.141	-4.35	-1.69	-1.06
Day 14	232.05 $\pm$ 0.340	224.79 $\pm$ 0.307	227.6 $\pm$ 0.816	230.82 $\pm$ 0.814	-3.12	-1.91	-0.53
Day 21	242.10 $\pm$ 0.567	232.21 $\pm$ 0.346	237.60 $\pm$ 0.657	241.5 $\pm$ 0.508	-4.08	-1.85	-0.24
Day 28	251.87 $\pm$ 0.427	243.09 $\pm$ 0.984	247.05 $\pm$ 0.428	250.5 $\pm$ 0.530	-3.48	-1.91	-0.54

The values represent Mean ± SD and the percentage of variation between control and other experimental groups. (All values are significant with P<0.05. The body weight is expressed in grams.)

**Body Weight:** The body weights of Arsenic toxicant rats days decreased compared to the control group i.e -4.35%, -3.12%, -4.08%, -3.48 on 7th, 14th, 21st and 28th days. However, Morin treatment significantly improved the body weight on 7th day by -1.68 % and -1.91% on 14th day and -1.85% on 21st day, -1.91% on 28th day respectively and control animals treated with Morin have shown -1.06% on 7th day -0.53% on 14th day and -0.24% on 21st day, -0.54% on 28th day (Table.1). Thus, Morin showed time-dependent protective effectiveness on body weights of Arsenic affected rats.

**Table 2: Effect of Morin on Brain Weight of Arsenic-Treated Rats**

Experimental Days/Groups	Group-I (Control)	Group-II (Ar)	Group-III (Ar+M)	Group-IV (M)	Percentage change over control		
					Group-II	Group-III	Group-IV
Day 7	1.81±0.013	1.71±0.017	1.74±0.010	1.80±0.016	-5.52	-3.86	-0.51
Day 14	1.90±0.014	1.79±0.030	1.84±0.014	1.89±0.020	-5.78	-3.15	-0.52
Day 21	1.98±0.003	1.85±0.011	1.93±0.013	1.97±0.007	-6.56	-2.52	-0.50
Day 28	2.12±0.004	1.93±0.019	1.98±0.004	2.12±0.002	-8.96	-6.60	0

The values represent Mean ± SD and the percentage of variation between control and other experimental groups. (All values are significant with P<0.05. The brain weight is expressed in grams.)

**Brain weights:** The percentage of variation of brain weights in Arsenic treated rats was decreased than the control group i.e. -5.52%, -5.78.71%, -6.56%, -8.96%, on 7<sup>th</sup>, 14<sup>th</sup>, 21<sup>st</sup> and 28<sup>th</sup> day when compared. However, Morin treatment significantly improved the brain weight on 7<sup>th</sup> day by -3.86 % and -3.15% on 14<sup>th</sup> day and brought it down towards near normal levels -2.52% on 21<sup>th</sup> day, -6.60% on 28<sup>th</sup> day and control animals treated with Morin have -0.51% on 7<sup>th</sup> day -0.52% on 14<sup>th</sup> day and -0.50% on 21<sup>st</sup> day, 0% on 28<sup>th</sup> day (Table.2).Thus, Morin showed time dependent protective effective on Brain weights of Arsenic effected rats.

**Table 3. Effect of Morin on Organo-Somatic Index of Arsenic-treated Rats**

Table 3				
Experimental Days	Group-I	Group-II	Group-III	Group-IV
Day 7	0.81	0.79	0.78	0.81
Day 14	0.82	0.79	0.8	0.81
Day 21	0.81	0.79	0.81	0.81
Day 28	0.84	0.79	0.78	0.84

The values represent the organ somatic index of the brain expressed in percentage (%).

**Organo somatic index:** The values of organo somatic index of the brain are shown in Table.3. The control group has the highest value of the organ somatic index. Experimental groups have shown the lowest value of organo somatic index. But the experimental group treated with Morin has shown slight recovery in organo somatic index of the brain. The control group treated with Morin has shown similar values to the control group.

**Table 4: Effect of Morin on Neuromuscular Coordination of Arsenic-Treated Rats**

Experimental Days/Groups	Group-I (Control)	Group-II (Ar)	Group-III (Ar+M)	Group-IV (M)	Percentage change over control		
					Group-II	Group-III	Group-IV
Day 7	57.6±1.66	32±1.095	43.2±0.8	59.6±0.871	-44.44	-0.25	3.47
Day 14	83.6±1.363	54±1.483	62±1.843	76±2.190	-35.40	-25.83	9.09
Day 21	119.6±2.657	82±1.095	92±1.843	110.2±1.280	-31.43	-23.07	-7.85
Day 28	155.6±1.805	120±2.244	138±5.329	144.2±3.2	-22.75	-11.31	7.32

The values represent Mean ± SE and the percentage of variation between control and other experimental groups. (All values are significant with  $P < 0.05$ . The Neuromuscular coordination was measured and expressed in seconds.)

**Neuromuscular coordination test:** Neuromuscular coordination test results are shown in Table.4. The control animals (C) showed normal coordination, which increased from the first week to the fourth week. Comparatively, the experimental animals (As) showed a significant percentage of variation, i.e. -44.44%, -35.40%, -31.43 %, -22.75 on 7th, 14th, 21st, 28th day. But the experimental animals treated (As+M) with Morin showed recovery in coordination when compared with experimental animals (As) and the percentage of variation in comparison with control are 7th day by -0.25% and -25.83% on 14th day, -23.07% on 21th day, -11.31% on 28th day. The control animals (M) treated with Morin did not show any deviation from control animals (percentage of variation in comparison with control 3.47% on 7th day -9.09% on 14th day, -7.85% on 21st day and -7.32% on 28th day).

**Table 5: Effect of Morin on the Memory of Arsenic-Treated Rats**

Experimental Days/Groups	Group-I (Control)	Group-II (Ar)	Group-III (Ar+M)	Group-IV (M)	Percentage change over control		
					Group-II	Group-III	Group-IV
Day 7	11.90±0.221	20.91±0.354	15.51±0.942	11.836±0.205	75.71	30.33	0.5
Day 14	15.30±0.350	31.49±0.598	25.07±0.659	0.877±0.392	105.81	63.85	3.83
Day 21	19.29±0.364	41.49±0.600	33.67±0.5524	20.03±0.385	115.08	74.54	3.86
Day 28	22.09±0.302	52±0.566	41.61±0.540	22.69±0.216	135.89	88.36	2.71

The values represent Mean ± SE and percentage of variation between control and other experimental groups. (All values are significant with  $P < 0.05$ . The time taken for spatial learning was measured and expressed in seconds).

**Morris water maze:** Table.5 depicts the results of Morris water maze of all the experimental groups. Control animals (C) were quick to learn first week but in fourth week animals took almost double time to that of the first week. Experimental groups (Ar) showed significant deviation in comparison to control animals right from first week to fourth week and the percentage of variation in comparison with the control group is as follows 75.71 %, 105.81%, 115.08 %, 135.89 on 7<sup>th</sup>, 14<sup>th</sup>, 21<sup>st</sup>, 28<sup>th</sup> day. Experimental treated (Ar+M) groups showed recovery in time in comparison to experimental group (Ar) and the percentage of variation in comparison with control are 7<sup>th</sup> day by 30.33 % and 63.85% on 14<sup>th</sup> day, 74.54% on 21<sup>st</sup> day, 88.36% on 28<sup>th</sup> day. Control treated animals (M) did not show any deviation from that of control (C) animals (0.5% on 7<sup>th</sup> day 3.83% on 14<sup>th</sup> day, 3.86% on 21<sup>th</sup> day and 2.71% on 28<sup>th</sup> day).



**Table 6: Effect of Morin on Memory Using Novel Object Recognition Tests in Arsenic-Treated Rats**

Experimental Days/Groups	Group-I (Control)	Group-II (Ar)	Group-III (Ar+M)	Group-IV (M)	Percentage change over control		
					Group-II	Group-III	Group-IV
Day 7	31.0±0.447	152±0.583	118.6±1.029	31±0.316	390.32	258.69	0
Day 14	61.4±0.509	300.8±0.374	240.8±0.374	618±0.489	389.90	292.18	0.65
Day 21	90.8±0.374	402±0.374	301.4±0.509	96±0.632	342.73	231.93	5.72
Day 28	122.2±0.583	502.4±0.871	402.4±0.748	124±0.774	311.12	299.29	1.47

The values represent Mean ± SE and the percentage of variation between control and other experimental groups. (All values are significant with P<0.05. The novel object recognition is expressed in seconds).

**Novel object recognizing test:** The results are present in Table.6. There is no significant delay of control animals (C) in recognizing the object from the first week to the fourth week. The experimental animals (As) showed significant delay in recognizing the object in comparison to control animals (C) from first week to fourth week and the percentage of variation in comparison with the control group is as follows: 390.32%, 389.90%, 342.73 %, 311.12% on 7th, 14th, 21st, 28th day. But in the experimental animals treated (As+M) with Morin there was significant recovery in time for recognizing the object and the percentage of variation in comparison with the control group was as follows, on the 7th day to 288.69 % and 292.18% on the 14th day , 231.93% on 21th day, 299.29 on 28th day. The control animals (M) treated with Morin did not show much variation in comparison with control animals (C) and the percentage of variation in comparison with the control group is as follows: 0% on 7th day, 0.65% on 14<sup>th</sup> day, -6.07% on 21st day and -4.06% on 28th day.

**Table 7: Effect of Morin on Depression in Arsenic-treated Rats**

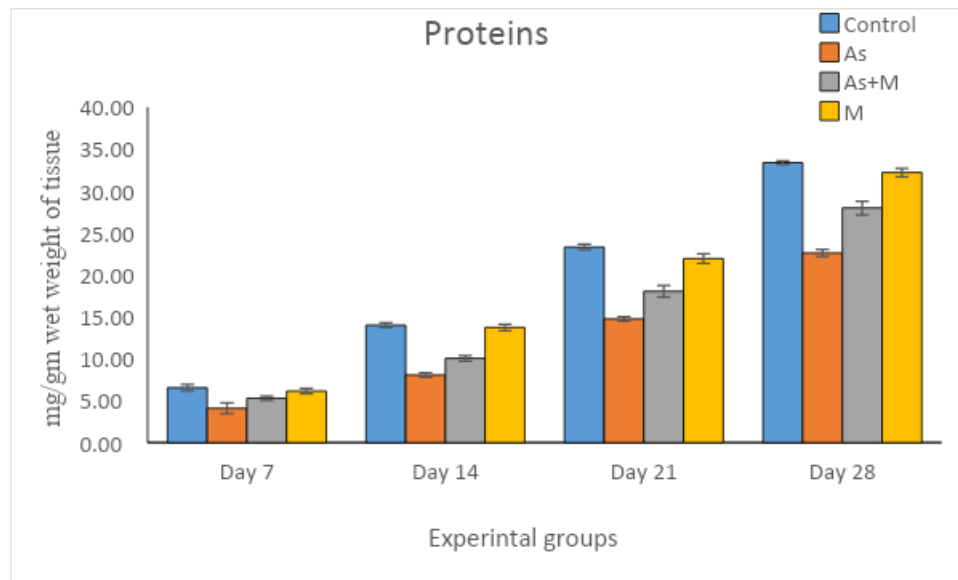
Experimental Days/Groups	Group-I (Control)	Group-II (Ar)	Group-III (Ar+M)	Group-IV (M)	Percentage change over control		
					Group-II	Group-III	Group-IV
Day 7	50.8±0.374	31.2±0.741	42±0.836	57.8±0.374	-38.58	-17.32	1.96
Day 14	61.6±0.509	41.8±0.663	53±0.836	61.4±0.678	-32.14	-13.96	-0.32
Day 21	72.4±0.927	53.8±1.067	63±1.140	68.4±0.979	-- 25.69	-12.98	-6.09
Day 28	83.6±0.509	64.2±1.157	75±.0.836	80.2±0.583	-23.20	-10.28	-4.06

The values represent Mean ± SE and the percentage of variation between control and other experimental groups. (All values are significant with P<0.05. The Depression is expressed in seconds.)

**Depression test:** The struggling time in control animals (C) was highest from week to fourth week, which means they were not showing depression like response (Fig.6). The experimental animals (As) in comparison with control (C) were showing less struggling time with more immobility responses, and the percentage of variation in comparison with control group is as follows -38.58%, -32.14%, -25.69 %, -23.20 on 7th, 14th, 21st, 28th day. But the Experimental animals (As+M) treated with Morin were little better when compared to experimental (As) with more struggling time and the percentage of variation in comparison with the control group is as follows -17.32%, -13.96%, -12.98 %, -10.28 on 7th, 14th, 21st, 28th day (Table.9). The control animals (M) treated with Morin almost showed a response similar to

control animals and the percentage of variation in comparison with the control group is as follows: 1.96%, -0.32%, -6.09 %, -4.06 on 7th, 14th, 21st, 28th day.

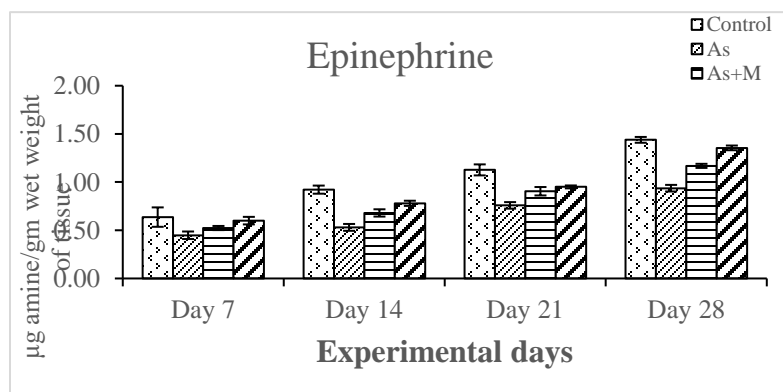
**Figure 1: Effect of Morin on Protein Content in the Brain Tissue of Arsenic-Treated Rats**



The values represent Mean ± SE and the percentage of variation between control and other experimental groups. (All values are significant with P<0.05. The protein content is expressed in mg per gram weight of the tissue.)

**Proteins:** The total protein levels in brain tissue are shown in Fig.1. The experimental group (As) showed a decreased trend of protein quantity (percentage of variation in comparison with the control group (C) is as follows -37.55%, -42.35%, -36.67 %, -32.27 on 7th, 14th, 21st, 28th day). The protein quantity of the experimental group treated with Morin (As+M) has shown recovery (the percentage of variation in comparison with the control group (C) is as follows, on the 7th day to -19.08 % and -28.21% on 14th day, -22.60% on 21<sup>st</sup> day, -16.18 on 28th day). Control animals treated with Morin (M) have shown similar quantities of protein as that of the control group (C) (the percentage of variation in comparison with the control group (C) is as follows -6.25% on 7th day -1.92% on 14th day, -5.87% on 21<sup>st</sup> day and -3.50% on 28th day).

**Figure 2: Effect of Morin on Epinephrine Content of Brain Tissue in Arsenic-Treated Rats**

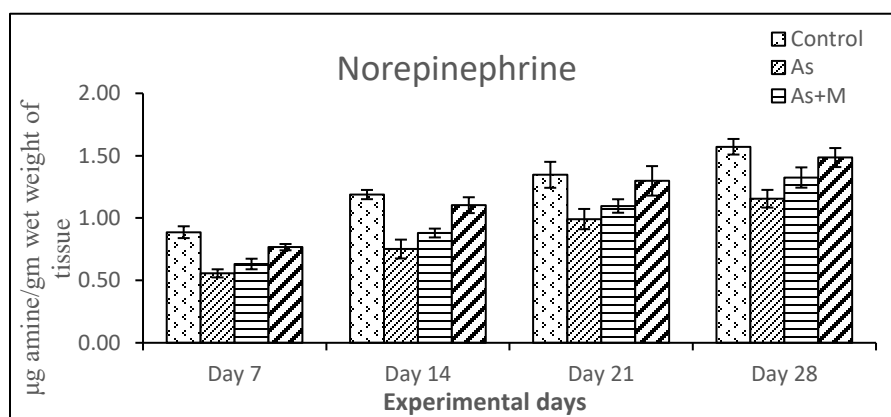




The values represent Mean  $\pm$  SE and the percentage of variation between control and other experimental groups. (All values are significant with  $P < 0.05$ . The Epinephrine content is expressed in  $\mu\text{g}$  amine/gm wet weight of tissue.)

**Epinephrine:** Figure 2 depicts the levels of Epinephrine in the brain during four weeks of study. But the experimental group (As) significantly lowered levels of Epinephrine when compared with the control group (C) and the percentage of variation in comparison with the control group was -29.68%, 42.39%, -32.74 %, -34.72 on 7th, 14th, 21st, 28th day. The treated group (As+M) showed significant recovery of Epinephrine in comparison to the Experimental group (As) and the percentage of variation in comparison with the control group was as follows: on the 7th day, on -18.75 % and -26.08% on 14th day, -19.46% on 21<sup>st</sup> day, -18.75 on 28th day. The control (M) group showed no variation when compared with the control group (C) (the percentage of variation in comparison with the control group is -6.25% on 7th day -15.21% on 14th day, -15.92% on 21st day and -5.55% on 28th day.

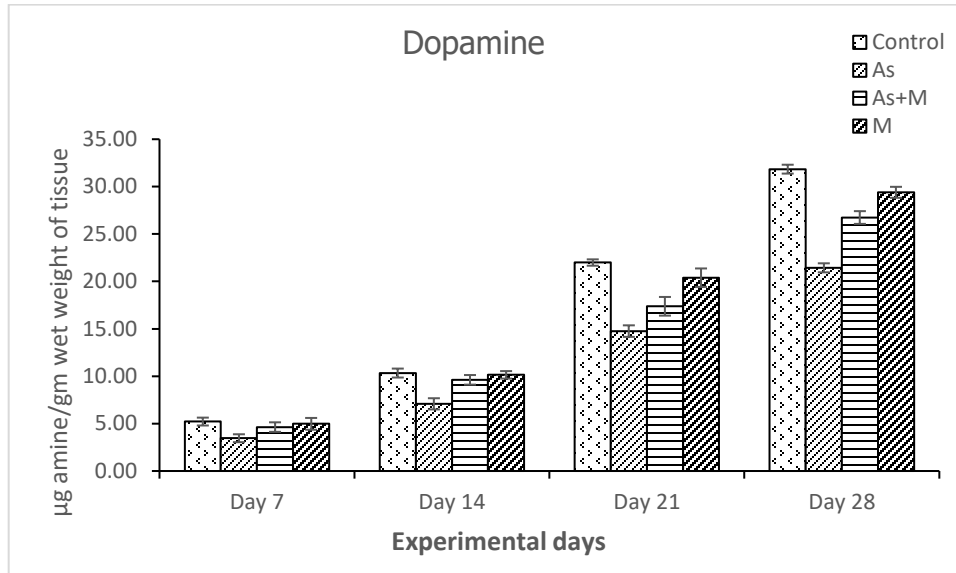
**Figure 3: Effect of Morin on Norepinephrin Content of Brain Tissue in Arsenic-Treated Rats**



The values represent Mean  $\pm$  SE and the percentage of variation between control and other experimental groups. (All values are significant with  $P < 0.05$ . The Norepinephrine content is expressed in  $\mu\text{g}$  amine/gm wet weight of tissue).

**Norepinephrin:** Fig.3 depicts Norepinephrin levels in the brain in all experimental groups for four weeks of study. The control group (C) showed normal levels of the brain Norepinephrin during all the four weeks of estimation. But in the Experimental group (As), it showed significant variation in Norepinephrin levels when compared to the control group (C) and the percentage of variation in comparison with the control group was -37.07%, -36.97%, -26.66 %, -26.11 on 7th, 14th, 21st, 28th day. The treated group (As+M) showed recovery of Norepinephrin levels in comparison to experimental groups (As) and the percentage of variation in comparison with the control group was on 7th day by -29.21% and -26.05% on 14th day, -18.51% on 21<sup>st</sup> day, -15.28 on 28th day. The control treated group (M) showed no variation when compared with the control group (C) (the percentage of variation in comparison with the control group is as follows -13.48% on 7th day -7.56% on 14th day, -3.70% on 21th day and -5.07% on 28th day.)

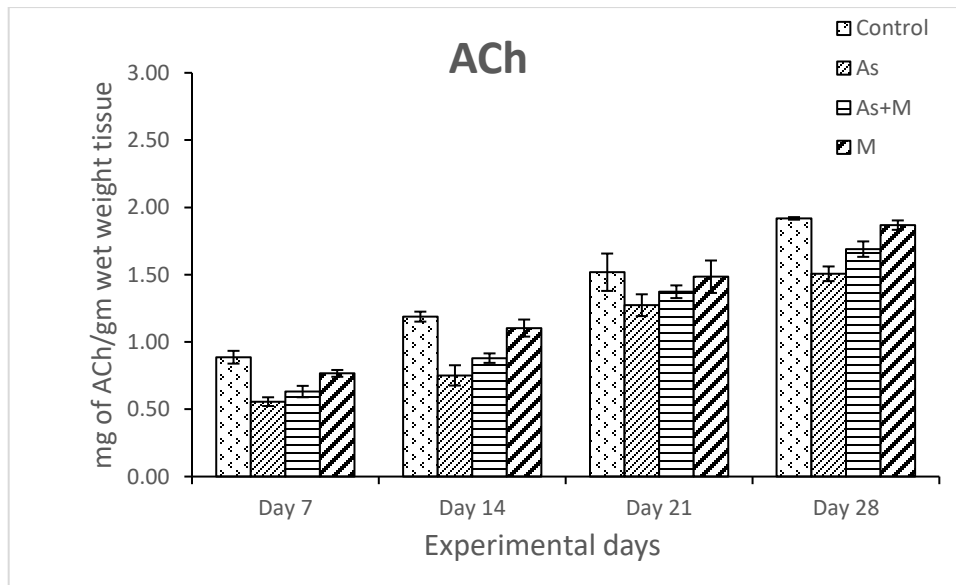
**Figure 4: Effect of Morin on Dopamine Content of Brain Tissue in Arsenic-Treated Rats**



The values represent Mean ± SE and the percentage of variation between control and other experimental groups. (All values are significant with  $P < 0.05$ . The Dopamine content is expressed in µg amine/gm wet weight of tissue).

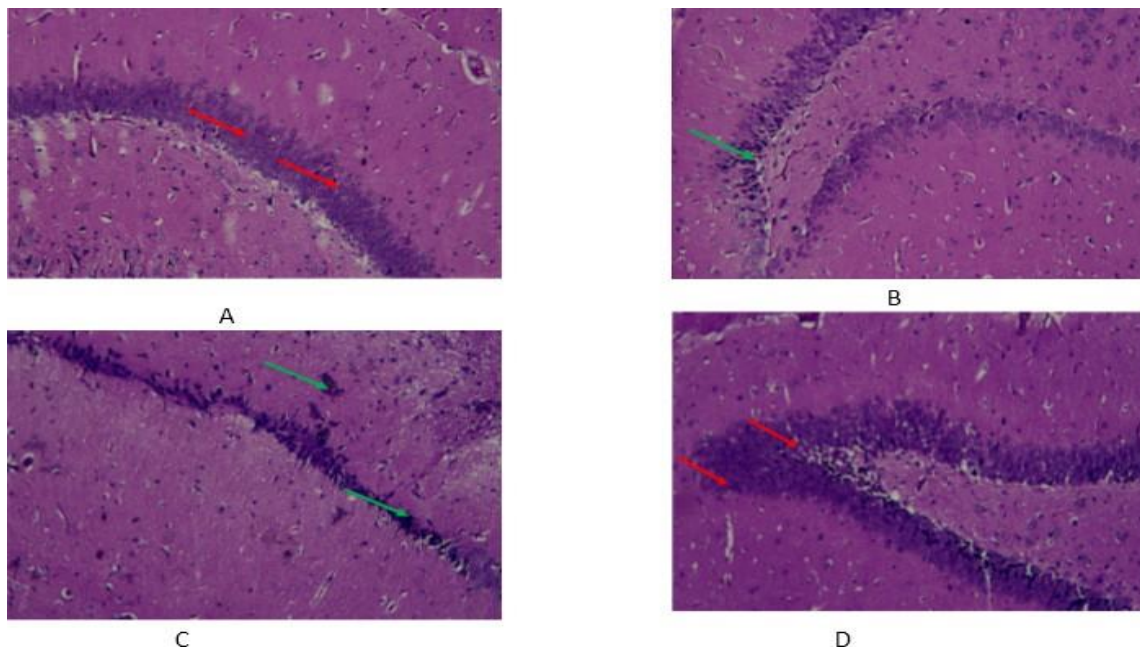
**Dopamine:** Fig.4 depicts the Dopamine levels in the brain of all experimental groups for four weeks of study. Control animals (C) showed normal dopamine levels in all weeks of the study. But the experimental group (As) showed significant variation in dopamine levels in comparison with the control (C) group and the percentage of variation in comparison with the control group is as follows -33.71%, -31.36%, -32.87 %, -33.04 on 7th, 14th, 21st, 28th day. The treated group (As+M) showed significant recovery of dopamine levels in comparison with the experimental group (As) and the percentage of variation in comparison with the control group was as follows: on the 7th day, by -11.30 % and -6.87% on 14th day, -20.96% on 21<sup>st</sup> day, -16.09 on 28th day. The control group (M) did not show any variation when compared with the control group (C) (the percentage of variation in comparison with the control group is as follows -4.59% on 7th day -1.83% on 14th day, -7.27% on 21<sup>st</sup> day and -7.75% on 28th day.)

**Figure 5: Effect of Morin on Acetylcholine Content of Brain Tissue in Arsenic-Treated Rats**

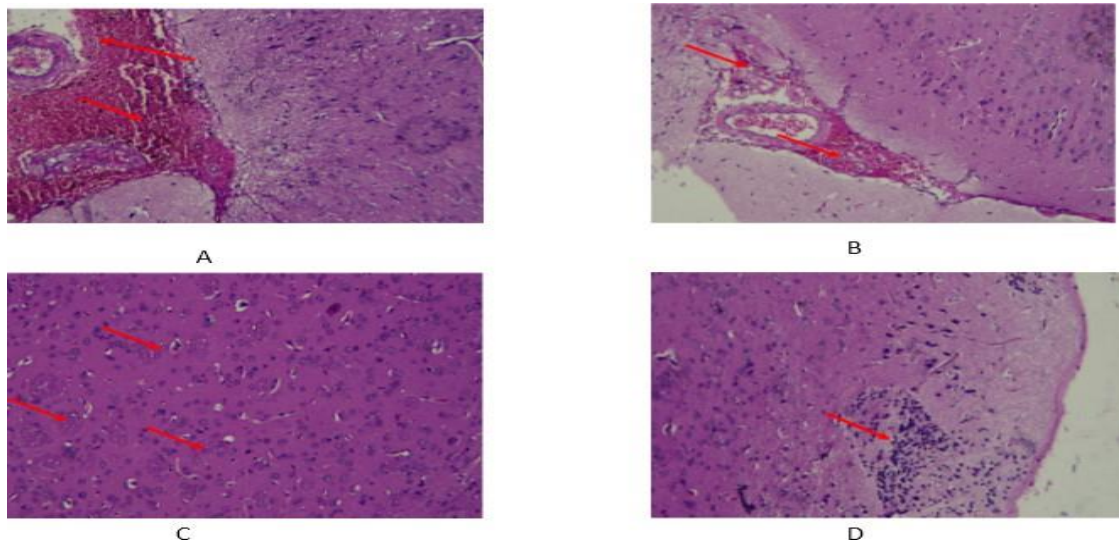


**The values represent Mean  $\pm$  SE and the percentage of variation between control and other experimental groups.** (All values are significant with  $P < 0.05$ . ACh content is expressed in mg of ACh/gm wet weight of tissue).

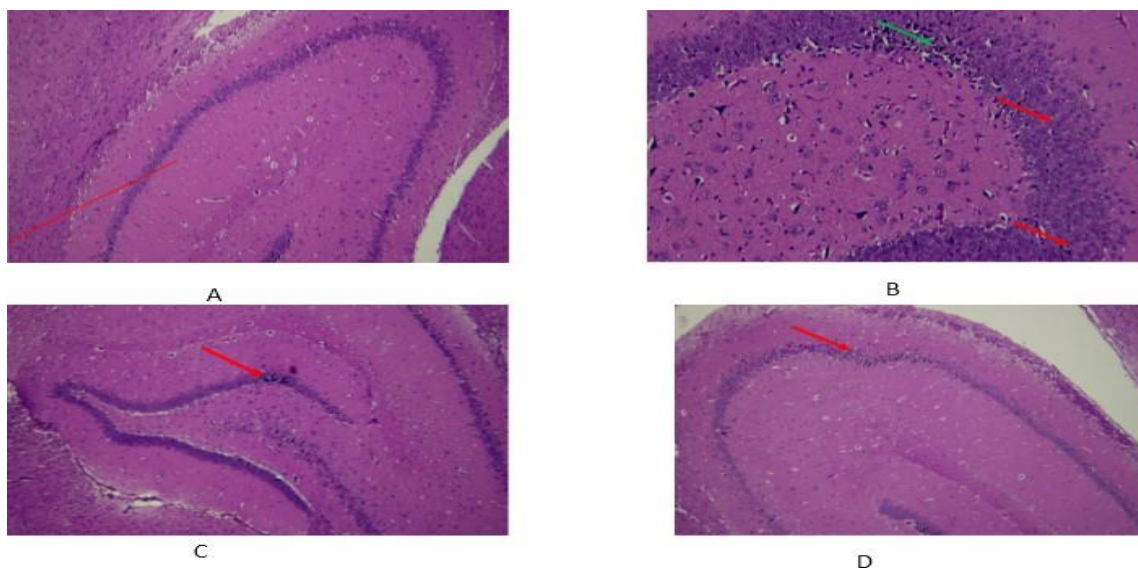
**Acetylcholine:** Fig. 5 depicts the Ach levels in the brain in an experimental group of four weeks of study. The control group (C) showed normal Ach levels in all four weeks of study. Experimental groups (As) showed significant variation when compared with the control group (C) and the percentage of variation in comparison with the control group is as follows -37.07%, -36.97%, -16.44 %, -21.35 on 7th, 14th, 21st, 28th day. The experimental treated group (As+M) showed significant recovery in Ach levels in comparison with the experimental group (As) and the percentage of variation in comparison with the control group is as follows: on the 7th day by -29.21% and -26.05% on 14th day, -9.86% on 21st day, 11.97 on 28th day. The control group (M) did not show any variation when compared with the control group (C) (the percentage of variation in comparison with the control group is as follows -13.48% on 7th day -7.56% on 14th day, -1.56% on 21<sup>st</sup> day and -2.60% on 28th day.)



**Fig.6:** First (7<sup>th</sup>) week of study Brain (Hippocampus) histological sections of all experimental groups stained with H&E. (A) Normal control group (Control) :Mild proliferation of hippocampus neurons was observed - red arrow; (B) As (Experimental group) :Mild proliferation of hippocampus neurons was observed, and Foci of apoptotic neurons were observed in the hippocampus – green arrow; (C) experimental group treated with Morin: Moderate multi focal necrosis [green arrow] and apoptotic neurons were observed hippocampus of the brain; (D) Control treated group (M) Mild proliferation of hippocampus neurons was observed - red arrow (40X, H&E stained).

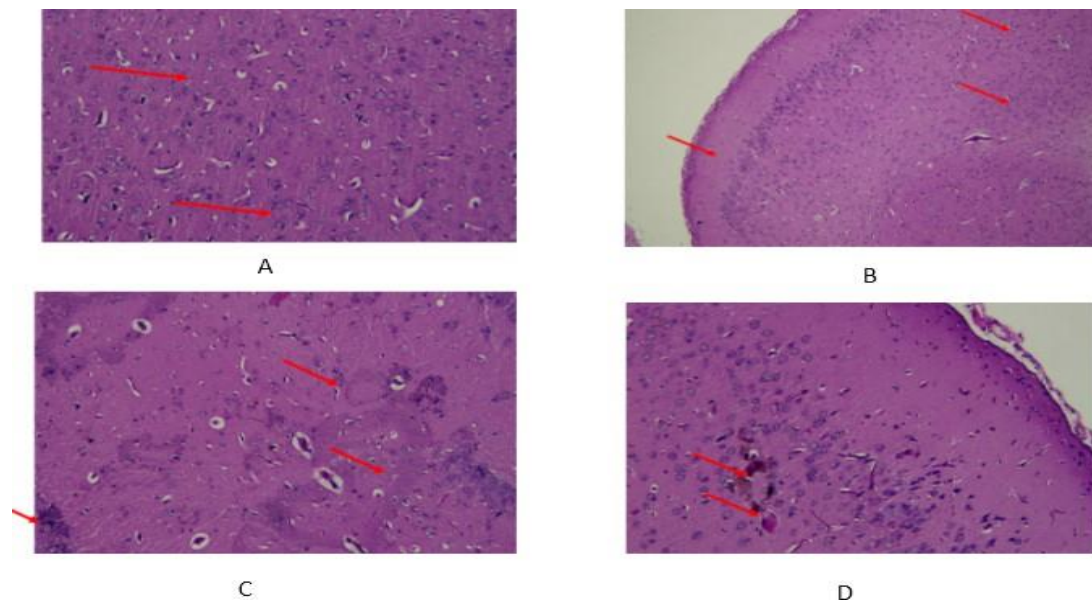


**Fig.7:** Second (14<sup>th</sup>) week of study Brain (cerebral cortex ) histological sections of all experimental groups stained with H&E. (A) Normal control group (Control) : Moderate meningeal hemorrhages were observed in the meninges covering the cerebral hemispheres; (B) As: (Experimental group) : Foci of apoptotic neurons in cerebral cortex and Moderate meningeal hemorrhages was observed in the meninges covering the cerebral hemispheres; (C) experimental group treated with Morin: Moderate multi-focal area of demyelination was observed in cerebral cortex arrow; (D) Control treated group (M) Multi focal gliosis was observed in cerebral cortex region of the brain - arrow (40X, H&E stained).

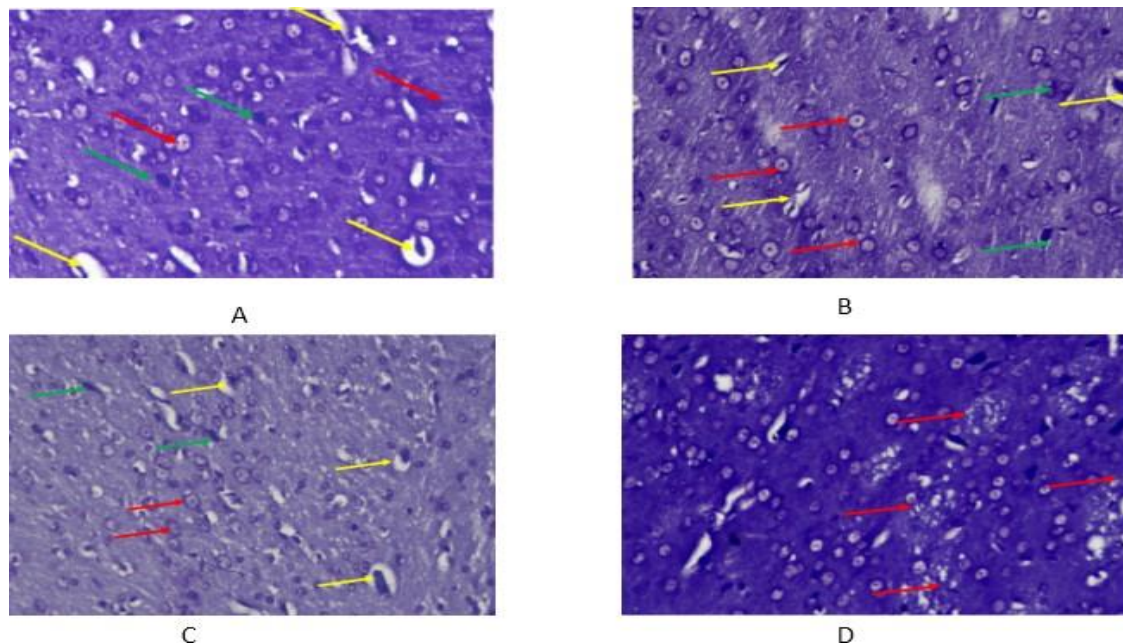


**Fig.8:** Third (21<sup>st</sup> Day) week of study Brain (Hippocampus) histological sections of all experimental groups stained with H&E. (A) Normal control group (Control) : Normal morphology of hippocampus region of the brain; (B) As: (Experimental group) : Foci of apoptotic neurons were observed in the hippocampus – the green arrow and Mild proliferation of hippocampus neurons were observed - red arrow; (C) experimental group treated with Morin: Normal histology with mild focal of apoptotic neurons were observed hippocampus of the brain - arrow; (D) control treated group (M): Moderate multi focal apoptotic neurons was observed hippocampus of the brain - arrow (40X, H&E stained).

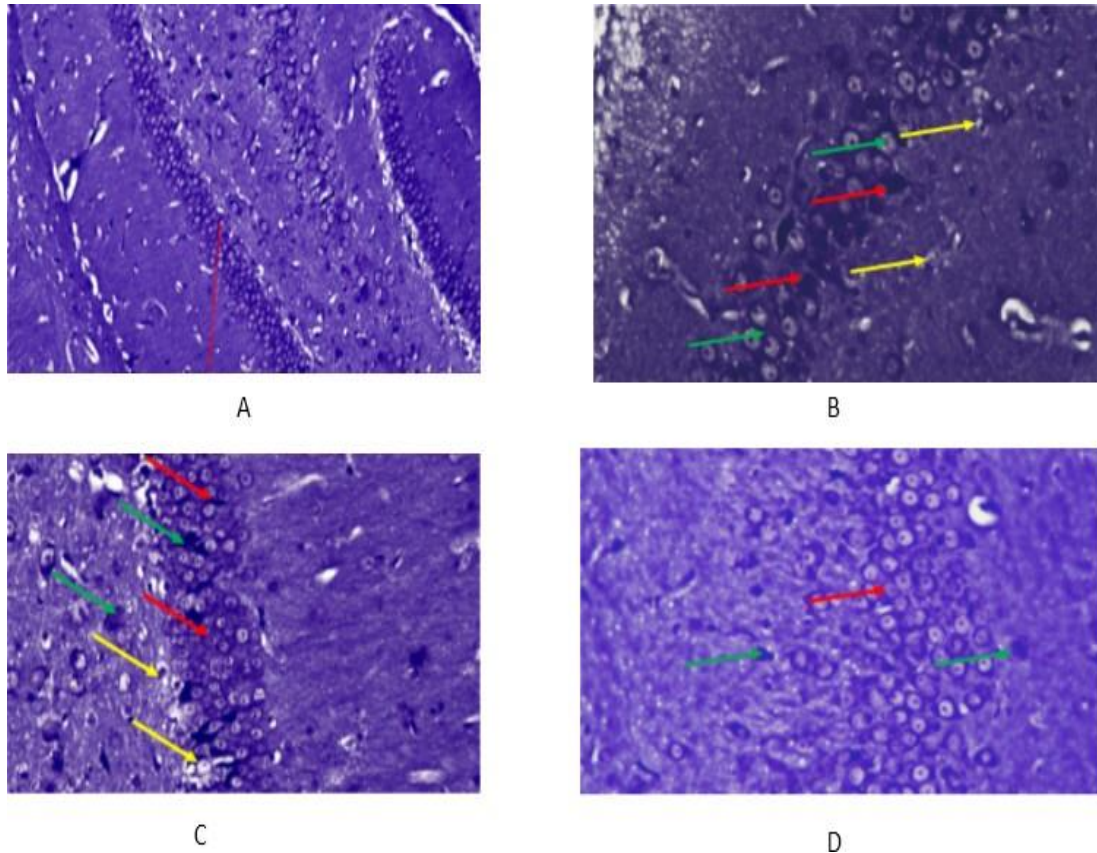




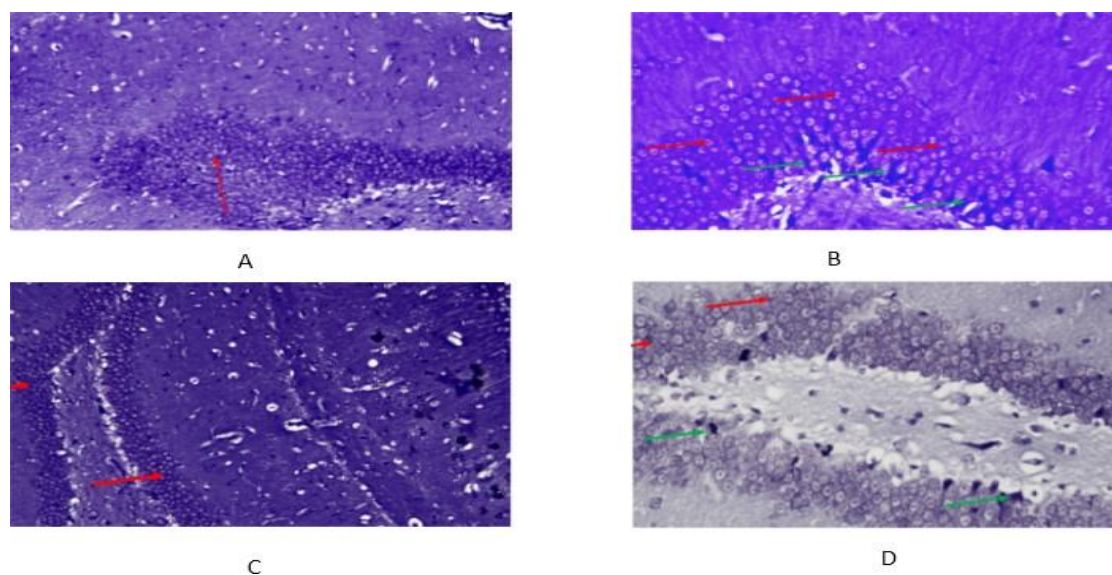
**Fig 9:** Fourth (28<sup>th</sup> Day) week of study Brain (cerebral cortex) histological sections of all experimental groups stained with H&E. (A) Normal control group (Control): Normal morphology of the cerebral cortex; (B) As: (experimental group) : Multifocal necrosis was observed in the cerebral cortex - arrow; (C) experimental group treated with Morin: Normal morphology of the cerebral cortex; (D) control treated group (M): Foci of necrosis and deposition of eosinophilic substances in cortex region - arrow (40X, H&E stained).



**Fig. 10:** First (7<sup>th</sup> day) week of study Brain (midbrain) histological sections of all experimental groups were stained with Cresyl violet. (A) Normal control group (Control): normal neurons [red], apoptotic [green] neurons, and degenerated neurons [yellow] in the midbrain; (B) As (experimental group): Scattered distribution of apoptotic and necrotic hippocampus neurons (green arrow); normal neurons (red arrow); degenerated neurons (yellow colour); (C) Experimental group treated with Morin: Scattered distribution of apoptotic and necrotic hippocampus neurons (green arrow); normal neurons (red arrow); degenerated neurons (yellow colour); (D) Control treated group (M) Mild demyelination [lack of myelin layer, lack of blue colour] in mid-brain (arrow) (40X, Cresyl violet stained)

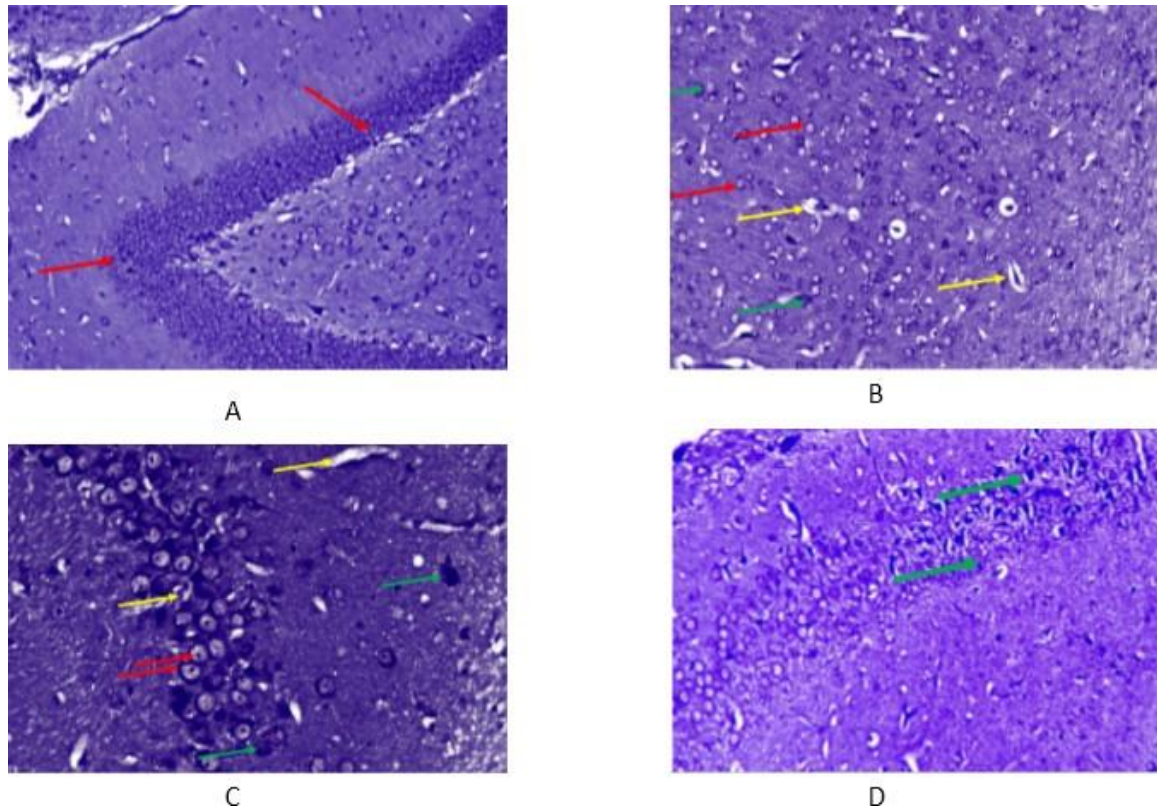


**Fig. 11:** Second (14<sup>th</sup> day) week of study the brain (hippocampus) histological sections of all experimental groups were stained with Cresyl violet. (A) Normal control group (Control): Normal morphology of the hippocampus neurons; (B) As (Experimental group): Scattered distribution of apoptotic and necrotic hippocampus neurons (green arrow); Normal neurons (red arrow); Degenerated neurons (yellow colour); (C) Experimental group treated with Morin: Foci of normal neurons [red], apoptotic neurons [green], degenerated neurons [yellow] in Hippocampus; (D) Control treated group (M) Mild hyperplasia of hippocampus neurons CA 3 region was observed in brain (red arrow) and few necrotic or apoptotic neurons (green arrow) (40X, Cresyl violet stained)



**Fig. 12:** Third (21<sup>st</sup> day) week of study Brain (hippocampus) histological sections of all experimental groups were stained with Cresyl violet. (A) Normal control group (Control): Massive proliferation of hippocampus neurons in CA3 region; (B) As (Experimental group): mild hyperplasia of hippocampus neurons of CA3 region was observed in the brain (red arrow) and few necrotic or apoptotic neurons (green arrow); (C) Experimental group treated with Morin: mild hyperplasia of hippocampus neurons of CA3 region was observed in the brain (red arrow) and few necrotic or apoptotic neurons (green arrow) (40X, Cresyl violet stained).





**Fig. 13:** Fourth (28<sup>th</sup> day) week of study Brain (hippocampus) histological sections of all experimental groups were stained with Cresyl violet. (A) Normal control group (control): Mild hyperplasia of hippocampus neurons in the CA3 region was observed in the brain (red arrow); (C) Experimental group treated with Morin: Scattered distribution of apoptotic and necrotic hippocampus neurons: green arrow; normal neurons: red arrow; degenerated neurons: yellow colour (D) Control-treated group (M): mild hyperplasia of hippocampus neurons in the CA 3 region was observed in the brain, and few foci necrotic or apoptotic neurons in the CA2 region (green arrow; (40X, Cresyl violet stained)

### Discussion

In the current study's behavioral trials, arsenic impairs rats' cognitive abilities. Rats' cognitive performance was enhanced by the Morin therapy from the first to the fourth week other trial. Arsenic induces neurotoxicity in Wistar rat brains by changing neurotransmitters, decreasing motor coordination, and inducing histological changes in the cerebral cortex and hippocampus tissue. In arsenic-treated rats, physical measures such as body weight and brain weight decreased. Body weight loss is thought to be the consequence of protein wasting caused by arsenic toxicity, which has been alleviated by Morin treatment by the fourth week of the trial.

The observed loss in brain weight could be attributed to a decrease in the number of glial cells and neurons. Previously, Nagaraja and Desiraju (1994) [29] observed arsenic-induced weight loss in the body and brain. Tolins et al. (2014) [30] reported that arsenic can enter the developing brain and induce neurological effects. Further, they hypothesized that exposure to arsenic during pregnancy and the first few months after birth caused the brain to weigh less, have less glia and neurons, and have different neurotransmitter systems. This study found that arsenic poisoning causes severe impairments in muscle strength and motor coordination in rats, as evidenced by a considerable decrease in retention time on the rota rod device. The result of this study is consistent with previous findings in rats with arsenic toxicity. (31) Morin therapy reduced rotorod retention time, indicating an improvement in neuromuscular coordination in arsenic-toxic rats.



Many studies employ the Morris water maze paradigm to assess how toxicants affect spatial learning. Increases in the amount of time spent on spatial learning in these arsenic-toxic animals demonstrate changes in learning and memory. Morin showed a considerable decrease in the amount of time needed for spatial learning. An object recognition test with episodic memory lasting for at least 60 minutes measures non-spatial working memory (32). The focus of ORT is on the innate tendency to spend more time studying unfamiliar objects than familiar ones. The choice to investigate the novel object demonstrates how learning and recognition memory are used. The cholinergic framework's integrity is necessary for object identification, as evident by many studies (33). It is well known that learning and memory systems are inextricably linked with cholinergic pathways leading to the cerebral cortex and hippocampus (33). According to research, cholinergic insufficiency may account for a portion of the cognitive debilitations seen in some neurodegenerative diseases, like Alzheimer's disease (AD) (34). The current investigation reveals the protective capacity of Morin in rats from the learning and memory impairment caused by arsenic toxicity, which is evident by the significant decrease in time spent on spatial learning and time spent investigating novel objects.

Any substance that can block vacuolar monoamine reuptake and cause monoamine evacuation in the brain can cause depressive-like behavior in animals (35). In this study, arsenic toxicity rats have shown depression-like behavior with increased immobility time in a forced swim test. Three weeks of treatment with Morin significantly decreased immobility time and increased time spent climbing and swimming in the forced swim test. The rise in oxidative stress in the brain is one of the factors that contribute to depression. Arsenic has been noted to exacerbate oxidative damage, which can lead to depression (36). Morin's antioxidant capabilities may have mitigated the effects of arsenic. The neurochemical analysis has revealed certain changes in neurotransmitters in arsenic-toxic rats in comparison to the control rats. Neurotransmitters, which are crucial for cellular communication inside the brain, are impacted by arsenic-induced neurotoxicity. According to Nagaraja et al. (1993) arsenic does increase dopamine and serotonin levels while inversely regulating norepinephrine levels. Arsenic can also change the amounts of aminobutyric acid (GABA) glutamate and other biogenic amines [38].

Acetylcholinesterase (AChE) which catalyses the metabolism of acetylcholine, was shown to be less active in rats exposed to arsenic [39]. The results suggest there may be a slight decrease in the binding of muscarinic cholinergic receptors in arsenic-treated rats when compared to the control group. Partial learning and memory loss, as well as changes to the cholinergic system, were brought on by arsenic induction. This is because cholinergic cell injury has been linked to neuronal cell death. In this study, we have also observed a decrease in ACh levels in comparison with control rats. Several reports have noted reduced acetylcholinesterase (AChE) activity and choline acetyltransferase functioning after arsenic exposure. A decreased level of ACh activity in muscle coordination is evident in our study and also according to other studies (40). According to Jiang et al., 2014 (41) a poor outcome in learning and memory could be mechanistically linked with altered levels of neurotransmitters released. Arsenic can cause neurotoxicity by affecting the amounts of neurotransmitters in the brain, such as serotonin, dopamine, and norepinephrine. (42) Dopamine and Norepinephrine are significant catecholamines. With varying exposure times and dosages, arsenic exhibits diverse neurotoxic effects in various brain areas. (43) Tripathi et al., 1997 (44) have shown that in rats treated with sodium arsenite (100 mg/l in drinking water) for 16 weeks, levels of dopamine and Norepinephrine in the whole brain were reduced. In the cortical region of the brain, research has shown lower levels of dopamine, adrenaline, and norepinephrine, which is consistent with our findings. In the current study, the administration of morin to rats exposed to arsenic led to the recovery of low levels of dopamine and norepinephrine, indicating an antidepressant effect that was demonstrated by a depression test. In the current study, rats treated with Morin alone had no discernible changes in the levels of biogenic amines; however, rats treated simultaneously with arsenic and Morin exhibited higher levels of catecholamines in their brains than rats treated with arsenic alone. These findings are conclusive and imply that Morin may protect against arsenic-induced neurotransmitter alterations in the rat brain.

Histopathological examination of the hippocampus, cerebral cortex and midbrain with H&E and Creyl violet stain revealed substantial neuronal degeneration in arsenic-treated rats, as evidenced by foci of apoptotic neurons in the hippocampus (1st and 3rd weeks). The H&E stain revealed moderate meningeal haemorrhages in the meninges covering the cerebral hemispheres (2nd week) and multifocal necrosis (4th week). And, using the Creyl violet stain, the dispersed distribution of apoptotic and necrotic hyperplasia of neurons in the CA3 region (1st to 4th week) was seen. It is well recognised that ROS plays a role in nervous system toxicity, which could be caused by arsenic-induced oxidative stress. Morin treatment, on the other hand, significantly decreased neurotoxicity, and its beneficial

effect may be attributed to its antioxidant features (45).

Chronic arsenic exposure causes oxidative damage in the brains of rats, according to Ghosh et al (2011) (46). According to the current study, arsenic-mediated oxidative stress may be the cause of the altered brain architecture. According to Okoji et al. (2015) (47), the mechanism behind oxidative stress caused by long-term arsenic exposure is linked to methyl deficiency and loss of DNA methylation in animals, which could account for histological alterations (48). Yousuf et al. (2023) (49) demonstrated a comparable investigation of the cerebral cortex with arsenic toxicogenic insults in the form of neuronal cell death, haemorrhage, and lymphocyte infiltration in the meninges. Morin pretreatment resulted in milder histological abnormalities, such as neuronal degeneration. This implies Morin's antioxidant capabilities in terms of protecting the cerebral cortex. Similar results, such as neuronal degeneration in the cerebral cortex of rats following subacute exposure to arsenic, have been reported by Singh et al., 2020 (50). Mostafa Falah et al. (2018) (51) demonstrated arsenic-toxic rats with severe white matter lesions and cellular damage in hippocampus CA1, which was not evident in our investigation.

Many environmental pollutants have been linked to behavioural alterations, and this has been elucidated in numerous studies (52). After being exposed to arsenic, rats exhibited abnormal roto rod, learning, and emotional behaviors. Arsenic-mediated behavioural abnormalities seen in the current study may be attributed in part to arsenic's detrimental impact on neurotransmitter levels in the brain. According to Sarter et al., 2007 (53) abnormalities in neurotransmitter release regulation and/or abnormal levels of extracellular neurotransmitter concentrations are core components of hypotheses on the neuronal foundations of behavioural and cognitive disorders, as well as the symptoms of neuropsychiatric and neurodegenerative disorders. Previous studies have shown a clear connection between oxidative stress and behavioural alterations (54). According to Selvakumar et al. (2013) (55) oxidative stress can mediate hippocampal neurodegeneration and behavioural alterations in adult rats. Although several transmitter systems have been proposed to play an integral part in specific cognitive processes, the extent of interactions between chemical systems is most likely enormous. According to Cheng et al. (2021) (56) memory function is modulated by interactions between the cholinergic and glutamatergic systems. Acetylcholine interacts with dopamine in cognitive functions (57). Other studies have suggested that the toxicant's interaction with the hippocampus and other limbic brain regions is responsible for its influence on learning and memory (58). Concurrently, arsenic caused degenerative changes on a histological level in the brain tissue of the treated rats, which could be a contributing factor to the detrimental behavioural changes. Previous research has found haemorrhage, neuronal degeneration, and vacuolation in rat brain tissue after arsenic toxicity, which is similar to our study. The results we obtain demonstrate that oral administration of arsenic has a direct influence on rat behavioural levels, neurotransmitter content, and brain histomorphology.

### Conclusion

Arsenic has the potential to directly affect the central nervous system. Arsenic can alter learning behaviour, neurotransmitter levels, and the histological structure of the brain. Conclusively, Morin has shown a neuroprotective effect on learning, behaviour, neurotransmitter levels, and the histological structure of the brain. Further studies are required to resolve the actual neuroprotective mechanism of Morin.

### References

1. Guha Mazumder DN. Chronic arsenic toxicity & human health. *Indian J Med Res.* 2008 Oct; 128(4):436-47. PMID: 19106439.
2. Kapaj S, Peterson H, Liber K, Bhattacharya P. Human health effects from chronic arsenic poisoning--a review. *J Environ Sci Health A Tox Hazard Subst Environ Eng.* 2006; 41(10):2399-428
3. Ratnaik RN. Acute and chronic arsenic toxicity. *Postgrad Med J.* 2003 Jul; 79(933):391-6.
4. Agarwal A, Virk G, Ong C, Du Plessis SS. Effect of oxidative stress on male reproduction. *World J Mens Health.* 2014 Apr; 32 (1), 1-17.
5. Powers SK, Jackson MJ. Exercise-induced oxidative stress: cellular mechanisms and impact on muscle force production. *Physiol rev.* 2008 Oct; 88 (4): 1243-76.

6. Lewchalermvong K, Rangkadilok N, Nookabkaew S, Suriyo T, Satayavivad J. Arsenic Speciation and Accumulation in Selected Organs after Oral Administration of Rice Extracts in Wistar Rats. *J. Agric. Food Chem.* 2018; 66:3199–3209.
7. Chen P, Miah M.R, Aschner M. Metals and Neurodegeneration. *F1000Research* 2016; 5: 366.
8. Uttara B, Singh A, Zamboni P, Mahajan R. Oxidative Stress and Neurodegenerative Diseases: A Review of Upstream and Downstream Antioxidant Therapeutic Options. *Curr. Neuropharmacol.* 2009; 7: 65–74.
9. Breijyeh Z, Karaman R. Comprehensive Review on Alzheimer's disease: Causes and Treatment. *Molecules.* 2020; 25:5789.
10. Baker B.A, Cassano V.A, Murray C. Arsenic Exposure, Assessment, Toxicity, Diagnosis, and Management: Guidance for Occupational and Environmental Physicians. *J. Occup. Environ. Med.* 2018; 60: e634–e639.
11. Gehan H Heeba, Magda E Mahmoud. Therapeutic potential of Morin against liver fibrosis in rats: Modulation of oxidative stress, cytokine production and nuclear factor kappa. *Environ Toxicol Pharmacol.* 2014 March; 37(2):662-71.
12. Subash S and Subramanian P. Protective effect of morin on lipid peroxidation and lipid profile in ammonium chloride-induced hyperammonemic rats. *Asia Pacific J of Tropic diseases.* 2012 (April); 2(2): 102-106.
13. Abdulaziz M, Aleis, Salim S, Al-Rejaie, Hatem M, Abuhashish, Mohammed M, Ahmed, Mihir Y, Parmar. Nephro-protective role of morin against experimentally induced diabetic nephropathy. *Digest Journal of Nanomaterials and Biostructures.* 2013 Jan-Mar; 8(1):395 – 401.
14. Hatem M, Abuhashish, Salim S, Al-Rejaie, Khaled A, Al-Hosaini, Mihir Y, Parmar and Mohammed M, Ahmed. Alleviating effects of morin against experimentally-induced diabetic osteopenia. *Diabetology & Metabolic Syndrome* 2013 Feb; 5:5.
15. Praveen Kumar, Issac, Ajay, Guru, Manikandan, Velayutham, Raman, Pachaiappan, Mariadhas, Valan, Arasu, Naif, Abdullah, Al-Dhabi, Ki Choon, Choi, Ramasamy, Harikrishnan, Jesu, Arockiaraj. Oxidative stress induced antioxidant and neurotoxicity demonstrated in vivo zebrafish embryo or larval model and their normalization due to morin showing therapeutic implications. *Life Science.* 2021; 283:119864.
16. Negin Mohammadi, Masoumeh Asle-Rousta, Mehdi Rehnema, Rahim Amini. Morin attenuates memory deficits in a rat model of Alzheimer's disease by ameliorating oxidative stress and neuroinflammation. *European J of pharmacology.* 2021; 910:174506.
17. Xie Xu, Li Mengzhu, Yao Ensheng, Gong Song, Xie Jie, Gao Wei, Xie Zhenxing, Li Zhanfei, Bai Xiangjun, Liu Lu, Liu Xing-hua. Morin exerts protective effects on encephalopathy and sepsis-associated cognitive functions in a murine sepsis model. *Brain Res Bulletin.* 2020; 159:53-60.
18. Elizabeth T. Olonode, Adegbuyi O. Aderibigbe, Olusegun A. Adeoluwa, Anthony T. Eduviere, Benneth Ben-Azu. Morin hydrate mitigates rapid eye movement sleep deprivation-induced neurobehavioural impairments and loss of viable neurons in the hippocampus of mice. *Behavioural Brain Res.* 2019; 356:518-525.
19. Hamit Celik, Sefa Kucukler, Selim Comaklı, Selçuk Ozdemir, Cuneyt Caglayan, Ahmet Yardım, Fatih Mehmet K andemir. Morin in attenuates ifosfamide-induced neurotoxicity in rats via suppression of oxidative stress, neuroinflammation and neuronal apoptosis. *NeuroToxicology.* 2019; 76:126-137.
20. Neelima Gupta, D. K. Gupta, P. K. Sharma. Condition factor and organosomatic indices of parasitized *Rattus rattus* as indicators of host health. *J Parasit Dis.* 2017 Mar; 41(1):21-28.
21. Benoit Haelewyn, Thomas Freret, Emilie Pacary, Pascale Schumann-Bard, Michel Boulouard, Myriam Bernaudin, Valentine Boue. Long-term evaluation of sensorimotor and mnemonic behavior following striatal NMDA-induced unilateral excitotoxic lesion in the mouse. *Behavioral Brain Research.* 2007; 178: 235–243.

22. R.Morris, Developments of a water-maze procedure for studying spatial learning in the rat. *J Neurosci Methods*. 1984 May; 11(1):47-60.
23. Joanne R Mathiasen , Amy DiCamillo. Novel object recognition in the rat: a facile assay for cognitive function. *Current Protoc Pharmacol*, 2010;Chapter 5, Unit:5.59, doi: 10.1002/0471141755.ph0559s49.
24. Porsolt, R.D., Anton, G., Blavet, N. and Jalfre, M. Behavioural Despair in Rats: A New Model Sensitive to Antidepressant Treatments. *European Journal of Pharmacology*. 1978; 47: 379- 391.
25. O H Lowry, N J Rosebrough, A L Farr, R J Randal. Protein measurement with the Folin phenol reagent. *J Bio Chem*. 1951 Nov; 193(1):265-75.
26. HP Kari, PP Davidson, HH Kohl, Kochhar MM. Effects of ketamine on brain monoamine levels in rats. *Research Communications in Chemical Pathology and Pharmacology*. 1978 Jun; 20(3):475-488.
27. Hestrin S. The reaction of acetylcholine and other carboxylic acid derivatives with hydroxylamine, and its analytical application. *J Bio Chem*. 1949 August; 180(1):249-61.
28. Luna, L.G. (1968) *Manual of histologic staining methods of the Armed Forces Institute of Pathology*. 3rd Edition, McGraw-Hill; 1968. New York.
29. Nagaraja TN, Desiraju T. Effects on operant learning and brain acetylcholine esterase activity in rats following chronic inorganic arsenic intake. *Hum Exp Toxicol*. 1994; 13(5):353–356
30. Tolins M, Ruchirawat M, Landrigan P. The developmental neurotoxicity of arsenic: cognitive and behavioral consequences of early life exposure. *Ann Glob Health*. 2014; 80:303–314
31. Saba Naqvi , Prince Kumar , S.J.S Flora. Comparative efficacy of Nano and Bulk Monoisomyl DMSA against arsenic-induced neurotoxicity in rats. *Biomedicine& Pharmacotherapy*. 2020; 132:110871
32. Bartolini L, Casamenti F, Pepeu G. Aniracetam restores object recognition impaired by age, scopolamine, and nucleus basalis lesions. *Pharmacol Biochem Behav*. 1996; 53:277-283, 1996.
33. Giovannini MG, Casamenti F, Bartolini L, Pepeu G. The brain cholinergic system as a target of cognition enhancers, *Behav Brain Res*. 1997; 83:1-5.
34. Huff FJ, Mickel SF, Corkin S, Growdon JH. Cognitive functions affected by scopolamine in Alzheimer's disease and normal aging. *Drug Dev Res*. 1988; 12 :271-278, 1988.
35. Dilek Kuzay , Ergin Dilekoz , Çigdem Ozer. Effects of thymoquinone in a rat model of reserpine-induced depression. *Braz. J. Pharm. Sci*. 2022; 58:1-18.
36. Nino S.A, Morales-Martínez A, Chi-Ahumada E, Carrizales L, Delgado R.S, Pérez-Severiano F, Díaz-Cintra S, et al. Arsenic Exposure Contributes to the Bioenergetic Damage in an Alzheimer's Disease Model. *ACS Chem. Neurosci*. 2018;10:323–336.
37. Nagaraja TN, Desiraju T. Regional alterations in the levels of brain biogenic amines, glutamate, GABA and GAD activity due to chronic consumption of inorganic arsenic in developing and adults rats. *Bull Environ Contam Toxicol*. 1993;50(1):100-107.
38. Mejía JJ, Díaz-Barriga F, Calderón J, Ríos C, Jiménez-Capdeville ME. Effects of lead-arsenic combined exposure on central monoaminergic systems. *Neurotoxico Teratol*. 1997;19(6):489-497.
39. Nagaraja TN, Desiraju T. Effects on operant learning and brain acetylcholine esterase activity in rats following chronic inorganic arsenic intake. *Hum Exp Toxicol*. 1994; 13(5): 353-356
40. Yadav RS, Sankhwar ML, Shukla RK, Chandra R, Pant AB, Islam F, Khanna VK. Attenuation of arsenic neurotoxicity by curcumin in rats. *Toxicol Appl Pharmacol*. 2009; 240(3):367–376

41. Jiang S, Su J, Yao S, Zhang Y, Cao F, Wang F, Wang H, Li J, Xi S. Fluoride and Arsenic Exposure Impairs Learning and Memory and Decreases mGluR5 Expression in the Hippocampus and Cortex in Rats. PLoS ONE. 2014; 9(4): 1-10, e96041.
42. Alao M.E, Perin J, Brooks WA, Hossain L, Goswami D, Zaman K, et al. Urinary arsenic is associated with wasting and underweight status in young children in rural Bangladesh. Environ. Res. 2020; 195: 110025.
43. Rajesh S, Yadav, Rajendra K, Shukla, Madhu Lata Sankhwar, Devendra K. Patel, Reyaz W. Ansari, Aditya B. Pant, Fakhru Islam, Vinay K. Khanna. Neuroprotective effect of curcumin in arsenic-induced neurotoxicity in rats. NeuroToxicology. 2010; 31:533–539.
44. Tripathi N, Kannan GM, Pant BP, Jaiswal DK, Malhotra PR, Flora JS. Arsenic-induced changes in certain neurotransmitter levels and their recoveries following chelation in rat whole brain. Toxicol Lett. 1997; 92:201–8.
45. Panhwar, Qadeer K., and Shahabuddin Memon. Synthesis and evaluation of antioxidant and antibacterial properties of morin complexes. Journal of Coordination Chemistry. 2011; 64(12): 2117-2129.
46. Ghosh A, Mandal AK, Sarkar S, Das N. Hepatoprotective and neuroprotective activity of liposomal quercetin in combating chronic arsenic induced oxidative damage in liver and brain of rats. Drug Deliv. 2011; 18:451–459.
47. Okoji RS, Yu RC, Maronpot RR, Froines JR. Sodium arsenite administration via drinking water increases genome-wide and Ha-ras DNA hypomethylation in methyl-deficient C57BL/6J mice. Carcinogenesis. 2002; 23:777–785.
48. Noman AS, Dilruba S, Mohanto NC, Rahman L, Khatun Z, Riad W, et al. Arsenic-induced Histological Alterations in Various Organs of Mice. J Cytol Histol. 2015 May; 6(3):323.
49. Yousuf R, Verma PK, Sharma P, Sood S, Bhatti MA, Bhat ZF. Neuroprotective effect of quercetin and *Zingiber officinale* on sodium arsenate-induced neurotoxicity in rats. Food Sci Nutr. 2023 Feb;11(6):2964-2973.
50. Singh, P, Verma, P. K, Raina, , Sood, S, & Sharma, P. (2020). Maximum contaminant level of arsenic in drinking water potentiates quinalphos-induced renal damage on co-administration of both arsenic and quinalphos in Wistar rats. Environmental Science and Pollution Research. 2020; 27:21331–21340.
51. Mostafa Fallah, Najmeh Moghble1, Iraj Javadi, Hossein Bahadoran, Alireza Shahriary. Effect of Curcumin and N-Acetylcysteine on Brain Histology and Inflammatory Factors (MMP-2, 9 and TNF- $\alpha$ ) in Rats Exposed to Arsenic. Pharmaceutical Sciences. 2018 Dec; 24: 264-272.
52. Viberg H, Johansson N, Fredriksson A, Eriksson J, Marsh G, Eriksson P. Neonatal exposure to higher brominated diphenyl ethers, hepta- octa- or nonabromodiphenyl ether, impairs spontaneous behavior and learning and memory functions of adult mice. Toxicol Sci. 2006; 92:211–8.
53. Sarter M, Bruno JP, Parikh V. Abnormal neurotransmitter release underlying behavioral and cognitive disorders: toward concepts of dynamic and function-specific dysregulation. Neuropsychopharmacology. 2007; 32:1452–61.
54. da-Rosa DD, Valvassori SS, Steckert AV, Ornell F, Ferreira CL, Lopes-Borges J, et al. Effects of lithium and valproate on oxidative stress and behavioral changes induced by administration of m-AMPH. Psychiatry Res. 2012; 15:521–6.
55. Selvakumar K, Bavithra S, Ganesh L, Krishnamoorthy G, Venkataraman P, Arunakaran J. Polychlorinated biphenyls induced oxidative stress mediated neurodegeneration in hippocampus and behavioral changes of adult rats: anxiolytic-like effects of quercetin. Toxicol Lett. 2013;222:45–54.
56. Cheng YJ, Lin CH, Lane HY. Involvement of Cholinergic, Adrenergic, and Glutamatergic Network Modulation with Cognitive Dysfunction in Alzheimer's disease. Int J Mol Sci. 2021 Feb;22(5):2283.
57. Lester DB, Rogers TD, Blaha CD. Acetylcholine-dopamine interactions in the pathophysiology and treatment of

CNS disorders. *CNS Neurosci Ther.* 2010 Jun; 16(3):137-62.

58. Tyng CM, Amin HU, Saad MNM, Malik AS. The Influences of Emotion on Learning and Memory. *Front Psychol.* 2017 Aug; 8:1454.