

<https://doi.org/10.48047/AFJBS.6.12.2024.2591-2601>



African Journal of Biological Sciences

Journal homepage: <http://www.afjbs.com>



Research Paper

Open Access

Topically Administered Vitamin D Derivatives Are Superior To Topically Administered Vitamin A Derivatives In The Management Of Potentially Malignant Lesions Through MMP-9 Induction Pathways. A double-blinded randomized controlled trial

Running title: Vitamin D Derivatives in Management Of Potentially Malignant Lesions

Rania Shalaby¹, Asmaa M.Elshaer², Sameh S. Zaghlool³, Shymaa Hamza⁴, Sally Ibrahim⁵, Salsabeel Afifi^{1*}

1. Oral Medicine, Oral Diagnosis and Periodontology, Faculty of Dentistry, Fayoum University, Fayoum, Egypt.
2. Clinical Pharmacology department, Faculty of Medicine, Ain Shams University, Cairo, Egypt.
3. Department of Pharmacology and Toxicology, College of Pharmacy, Almaaqal University, Al-Maaqal, Basra, Iraq.
4. Oral & Maxillofacial pathology, Faculty of Dentistry, Cairo University, Giza, Egypt.
5. Oral and Maxillofacial Pathology, Faculty of Dentistry, Fayoum University, Fayoum, Egypt.

***Corresponding author's name:** Salsabeel Afifi

ORCID ID: <https://orcid.org/0000-0002-8690-6078>

Address: 1890 ReasetelGomhorya St. 6th October city, Egypt.

Email address: sam24@fayoum.edu.eg

Article History

Volume 6, Issue 12, 2024

Received : 25 Apr 2024

Accepted : 13 Jul 2024

doi:

10.48047/AFJBS.6.12.2024.2591-2601

Abstract

The objective of this study is to assess the efficacy of topical Vitamin D derivative compared to topical retinoids in treating oral premalignant lesions, such as oral leukoplakia and oral lichen planus. The evaluation focused on the changes in clinical scores and salivary MMP-9 levels measured by ELISA. Results showed that 80% of cases in the Vitamin D derivative group and 70% of cases in the retinoids group were clinically improved after 4 weeks of therapy. There was a statistically significant difference in terms of the reduction in MMP-9 level before and after treatment with Vitamin D derivative more than retinoids, with a p-value of 0.01405. This investigation provides more evidence to support the idea that Vitamin D derivative may serve as a viable alternative to retinoids in the treatment of premalignant lesions depending on the significant impact of Vitamin D derivative in reducing salivary MMP-9 levels.

Keywords: vitamin D Derivatives, vitamin A Derivatives, Potentially Malignant Lesions, MMP-9, oral lichen planus, leukoplakia.

Introduction

Some potentially malignant lesions (PMLs), like leukoplakia, erythroplakia, lichen planus, and oral submucous fibrosis, can show up before oral cancer does. The most common potentially cancerous abnormality in the oral cavity is leukoplakia. Oral lichen planus (OLP) is a prevalent mucocutaneous illness characterized by T cell-mediated inflammation, the cause of which is still unclear (Nogueira et al., 2015; Warnakulasuriya et al., 2021)

Matrix metalloproteinase 9 (MMP-9) is an enzyme that relies on zinc to break down collagen type IV which is considered as a key component of the basement membrane. MMP-9 plays an important role in tumor biology. Originally, it was thought that the primary function of MMPs was to assist in the degradation of physical barriers, such as the disintegration of the basal membrane. Nevertheless, there is evidence indicating that MMPs play a multifaceted role in the process of metastasis. This includes their involvement in tumor-induced angiogenesis, tumor invasion, and the formation of metastatic foci in secondary locations (Bahar-Shany et al., 2010; Dutta et al., 2010; Meehansan et al., 2012; Reunanen and Kähäri 2013; Nogueira et al., 2015).

Oral squamous cell carcinoma (OSCC) is a major consequence of the course and prognosis of OLP. This drove the World Health Organization (WHO) to designate OLP as a potentially malignant lesion. Hence, a significant result in the management of both oral leukoplakia and OLP is the mitigation of the likelihood of malignant transformation (Brouns et al., 2013; Warnakulasuriya et al., 2021). Studies have documented elevated MMP-9 expression in OSCC as well as in the progression of oral leukoplakia and OLP towards malignancy. MMP-9 has been extensively investigated as a possible cancer biomarker in OSCC, as documented by several studies (Chen et al., 2008; Stott-Miller et al., 2011; Meehansan et al., 2012; Reunanen and Kähäri 2013).

Topical retinoids ability to reduce keratinization and modulate the immune system has led them to be used in treating both human oral leukoplakias and OLP. Researchers have attributed their effectiveness against cancer to their capacity to alter differentiation, apoptosis, proliferation, and MMP expression and activity (Chen et al., 2022). Several normal and malignant cell types have demonstrated the antiproliferative and pro-differentiating effects of vitamin D3 and its analogs. Additionally, vitamin D derivative has the ability to reduce the harmful effects by decreasing the levels of MMP-9 (Bahar-Shany et al., 2010, Bikle 2021). Umehara et al. (2023) have investigated the effects of calcitriol, activated Vitamin D3, in the management of certain cutaneous disorders characterized by dysfunctional skin barriers. Thus, the objective of this study is to assess the efficacy of topical Vitamin D derivative compared to topical retinoids in treating oral premalignant lesions, such as oral leukoplakia and oral lichen planus depending on the changes in clinical scores and salivary MMP-9 levels.

Materials and Methods

It is a double-blinded randomized controlled trial. Neither the participants nor the researchers knew which treatment they were using. The proposal of the study was approved by the scientific and ethical committees of the Faculty of Oral and Dental Medicine, Cairo University.

Patient Selection

Prior to their allocation to the experiment, informed consent was obtained from all participants. Every participant was given comprehensive information on the potential negative consequences of the experimental medications. The current investigation was conducted on a cohort of 40 individuals diagnosed with either oral leukoplakia or OLP which was verified by histopathological examination. The participants were recruited from the outpatient clinic of the Department of Oral Medicine and

Periodontology at the Faculty of Oral and Dental Medicine, Cairo University, located in Cairo, Egypt. The severity of epithelial dysplasia ranged from mild to moderate, and all forms of OLP lesions were present.

Included lesions were in areas where patients could easily apply a topical medication and expect it to stay in that specific location for a few minutes. Consequently, the possibility of leukoplakia on the soft palate was ruled out because it is impossible to reach and provide topical medication to that area. The chosen patients demonstrated both willingness and capability to attend many subsequent appointments for follow-up. Patients exhibiting oral lesions other than OLP or leukoplakia were excluded. In addition, researchers did not include patients with periodontitis because chronic periodontitis can potentially impact the level of salivary MMP-9 (Rathnayake et al., 2015; Silosi et al., 2015). Moreover, patients who had received any treatment for lesions within 2 months prior to the start of the study were excluded (Volz et al., 2008), those who were not suitable for the use of Vitamin D derivative as determined by Shahzad et al. (2006), or those who were undergoing any treatment that could cause an oral lichenoid reaction were also excluded.

Participant allocation and randomization

Patients from each research group were randomly allocated to one of two parallel groups in a 1:1 ratio. Group A administered 50 mcg/g of Vitamin D derivative in an adhesive carrier (carboxymethylcellulose) twice daily for 4 weeks, while Group B administered 0.05% Retinoids cream twice daily for the same duration. The participants' random allocation sequence was constructed using a computer-generated set of random integers. A trial coordinator, who was not responsible for the regular treatment of patients, created the allocation sequence and recruited volunteers. The allocation was performed using a basic randomized process, utilizing a sequentially numbered randomization list. Each patient was assigned a serial number, with each new patient added to the list and occupying the next available serial number.

Medical evaluation and gathering of information

A thorough oral diagnosis was conducted for each patient, utilizing the oral diagnostic chart of the Faculty of Oral and Dental Medicine, Cairo University. Following a thorough inspection with a spot light, the established criteria for OLP and oral leukoplakia was followed as mentioned by Warnakulasuriya et al., (2021) to tentatively diagnose oral leukoplakia and oral lichen planus. A histopathological investigation confirmed the definitive diagnosis. Thorough medical and dental histories were conducted in order to meet the requirements for inclusion. In order to identify any medication contraindications, patients also underwent liver function tests, thyroid function tests, serum calcium level testing, and urea and electrolyte level tests.

Lesions were assessed, documented photographically, and assigned scores at the beginning of the study, with additional clinical evaluations conducted at 0, 2, and 4 weeks for groups A and B. The roughness and intensity of whiteness in both leukoplakia and lichen planus were assessed using clinical scoring. These scores were determined visually and assigned the following values: 0: Complete resolution of lesions. 1: Moderate resolution refers to a decrease in the firmness of the lesion together with a leveling effect. 2: A minimal change indicates a decrease in firmness without a leveling effect. 3: No visible change means that there is no apparent difference.

Salivary sample collection

Groups A and B were sampled for baseline whole saliva. Furthermore, specimens were gathered from both groups four weeks post-treatment. The collection occurred in a tranquil room during the morning,

between 8 a.m. and noon, when at least one hour had passed since the last meal. Participants were directed to generate saliva in their mouths and expel it into a large test tube for 10 minutes. The saliva was collected and stored at a temperature of 4 °C for a maximum of 2 hours. Subsequently, it was instantly subjected to centrifugation at a speed of 800 g at a temperature of 4 °C for 10 minutes. The liquid remaining above the silt, referred to as the supernatant, was used for further biochemical investigation following the method described by Nagler et al. in 2001. The concentration of MMP-9 in saliva was measured using a human MMP-9 ELISA kit provided by Affymetrix (eBioscience, Inc., Affymetrix Pte Ltd., USA).

Statistical analysis

The statistical analysis was conducted using SPSS (version 17). Continuous data were expressed as the mean, standard deviation (SD), and range (maximum and minimum). Categorical data were defined using proportions and percentages. The pre-post measures within the same group were assessed using paired sample t-test and Wilcoxon Signed Ranks Test are utilized to assess, while the independent sample t-test and Mann-Whitney U test are employed to compare the mean changes between two groups.

The significance threshold was set at $P < 0.05$, indicating a moderate degree of significance. A more stringent level of significance, $P < 0.01$, is regarded as highly significant.

Results

The demographic parameters of the two groups were closely aligned, as seen in Table 1.

Table 1 presents the descriptive data for all participants that were included in the study.

		Vitamin D derivative n=20	Retinoids n=20	Control n=10
Lesion	LP	14(70%)	17(85%)	
	Leukoplakia	6(30%)	3(15%)	
Age	Mean± SD	38.2±10.1	36.05±8.37	35.3±6.3
Gender	Female	14 (70%)	12(60%)	7(70%)
	Male	6(30%)	8(40%)	3(30%)

Regarding the results for clinical score at 2 weeks of treatment, neither group A nor group B exhibited complete remission of the lesion in any patient. Nevertheless, the percentage of patients with moderate clearance of lesions was 20% in group A compared to 10% in group B. Subsequently, the percentage was greater in the Vitamin D derivative-treated group compared to the retinoids-treated group; however, this difference did not achieve statistical significance (P value = 0.943). In addition, the percentage of patients with minor changes was 50% in the Vitamin D derivative group compared to 45% in the retinoids group. The percentage of improved cases in the Vitamin D derivative group is somewhat greater than in the retinoids group, but this difference is not statistically significant (P value = 0.8808). Furthermore, the Vitamin D derivative group showed no apparent change in 30% of patients, compared to 45% in the retinoids group. This suggests that a greater number of patients in the retinoids group did not see any visible improvement. Nevertheless, the statistical analysis showed that it is not significant (P value = 0.8808). After 4 weeks of therapy, the proportion of patients showing

improvement was somewhat greater in the Vitamin D derivative group compared to the retinoids group. However, this difference was not statistically significant (P value 0.7233), as seen in Table 2.

Table 2: Comparison of the clinical improvement in groups A versus group B after 4 weeks of treatment.

Clinical scores at 4 weeks	Vitamin D derivative Group (%)	Retinoids Group (%)	P-value
0: Total cure	25%	10%	0.3
1: Moderate cure	30%	30%	1.000
2: Minor change	25%	30%	0.7
3: No apparent change	10%	10%	1.000

Furthermore, the clinical scores within each group exhibited a substantial increase at the 4-week mark compared to the scores at the 2-week mark of the treatment period. Comparing instances that showed any degree of improvement, whether it was significant, moderate, or minor, against those that showed no obvious improvements throughout the 4-week follow-up period. The number of improved cases in the Vitamin D derivative group was 16 out of 20, which corresponds to 80%. In the retinoids group, there were 14 improved cases out of 20, which is equivalent to 70%. However, there were 2 out of 20 instances in the Vitamin D derivative group that showed no apparent changes, accounting for 10% of the total cases. This is the same percentage as the 2 out of 20 patients in the retinoids group that also showed no visible improvements. Consequently, there is a greater proportion of instances that had shown improvement compared to those that had not shown improvement in both groups. Overall, there was no statistically significant distinction between the two groups, as indicated by the P value of 0.854 (Figure 1).

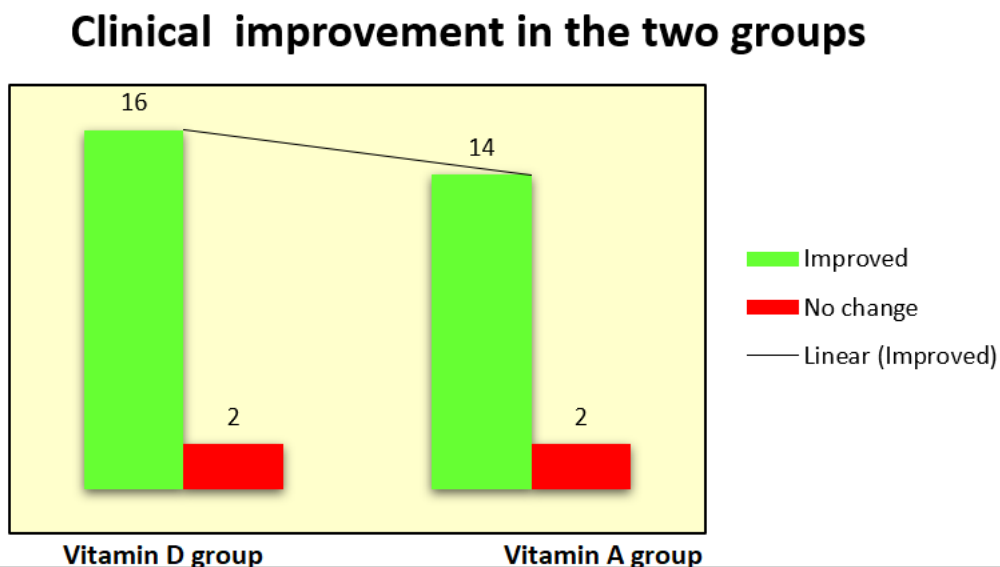


Figure 1 Comparison of the clinical improvement between the two study groups

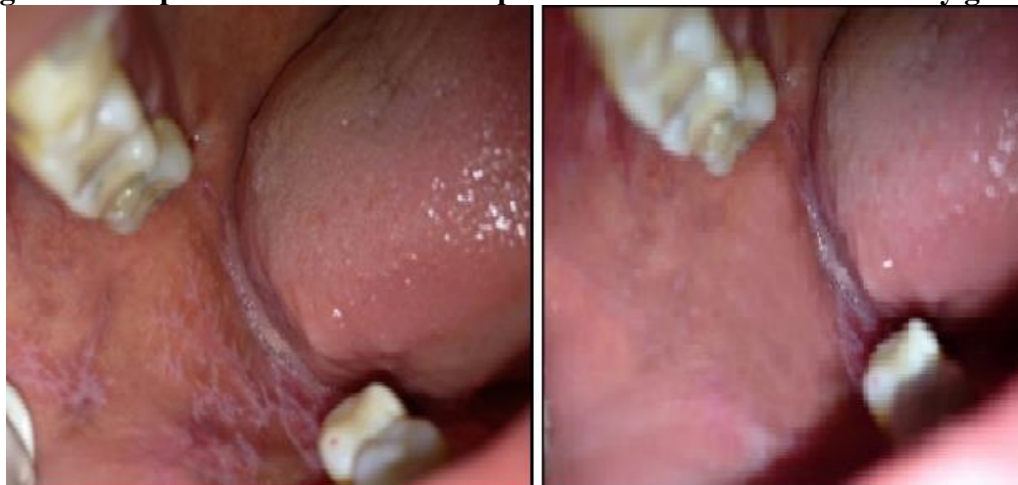

Figure 2 A 46-year-old female patient with oral lichen planus. The image shows the patient's condition before and after undergoing 4-week therapy with Vitamin D derivative.

The average and standard deviation values for the difference in MMP-9 ($\mu\text{g/L}$) levels between pre-treatment and post-treatment in group A were $-2.13(\pm 0.87)$, whereas the average and standard deviation values of MMP-9 ($\mu\text{g/L}$) levels in group B were $-1.46(\pm 0.60)$. The average discrepancy between the two groups (Vitamin D derivative and retinoids) was -0.68 , with a standard error of 0.26 . Thus, there was a statistically significant difference between the groups treated with Vitamin D derivative and retinoids in terms of the reduction in MMP-9 level before and after treatment, with a p-value of 0.01405 . These findings are illustrated in Figure 3. Furthermore, a non-parametric Mann-Whitney test was employed to verify the disparity in MMP-9 levels (before and after therapy) between the two groups.

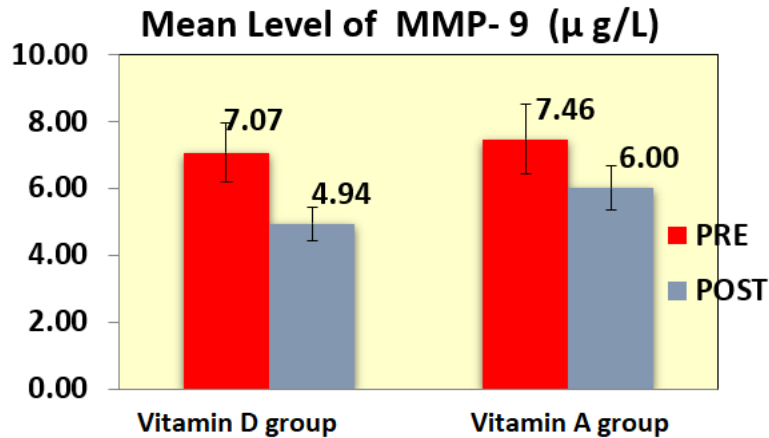


Figure 3 Comparison between groups A and B regarding the mean and standard deviation values of salivary MMP-9 levels after therapy.

Discussion

The etiopathogenesis of PMLs, such as leukoplakia and OLP, involves the continuous expression of MMP-9, which leads to tissue damage caused by excessive proteolytic activity. This process plays a crucial role in various aspects of tumor biology, including initiation/promotion, angiogenesis, dissemination, immunological surveillance, and metastatic growth (Bahar-Shany et al., 2010; Gupta et al., 2015). Presently, the prevailing treatment method for managing oral leukoplakia lesions is the surgical excision of the affected tissue. Nevertheless, there is a lack of data supporting the notion that surgical excision can effectively decrease the likelihood of recurrence or the development of malignancy. In addition, a Cochrane review found that there are no randomized controlled trials (RCTs) currently available on the surgical treatment of oral leukoplakia (Lodi et al., 2016). Thus, non-surgical therapy, which is more cautious, appears to be a more compelling choice (Feller and Lemmer, 2012).

When it comes to managing OLP, powerful topical corticosteroids are regarded as the most effective initial therapy option. Extended usage of topical corticosteroids might lead to medication tolerance, secondary candidiasis, or allergy. In addition, several individuals may not have a satisfactory response to steroid treatment (Gonzalez-Moles et al., 2008; Thongprasomet al., 2013). Compounds such as vitamin A derivatives and vitamin D3 analogues have the potential to be used as therapeutic treatments for PMLs. This is because they have anti-keratinizing, immune-modulatory, anti-proliferative, and pro-differentiating actions, which can stop the development of cancer. Retinoids, which are chemicals related to vitamin A, have been effectively utilized in the treatment of OLP and oral leukoplakia, as demonstrated by studies conducted by Femiano et al. in 2001 and Kini et al. in 2011. Vitamin D derivative, a vitamin D3 analogue, can reduce the harmful consequences produced by excessive activity of MMPs by decreasing the levels of MMP-9 (Bahar-Shany et al., 2010; Bikle 2021).

Hence, the objective of this clinical research was to assess the efficacy of topical Vitamin D derivative compared to topical retinoids in treating oral PMLs, specifically oral leukoplakia and OLP. The evaluation focused on measuring changes in clinical score and salivary MMP-9 level. Only individuals who were in good overall health were selected, whereas those with periodontitis were not included. The purpose of this is to rule out any underlying medical conditions that could cause an increase in salivary MMP-9 levels and to prevent any potential issues with the drugs being tested, particularly in individuals with diabetes, vascular changes related to atheroma, liver damage, and disorders of calcium metabolism (Femiano et al., 2001; Shahzad et al., 2006; Rai et al., 2008; Liu et

al., 2015; Rathnayake et al., 2015; Silosi et al., 2015). In this investigation, topical preparations were favored over systemic ones due to their ability to achieve a greater concentration of the chemical directly in the target tissue. Additionally, topical preparations were shown to adhere effectively to the oral mucosa with a suitable exposure period. The follow-up duration of 4 weeks was selected based on the findings of Günther (1973), who saw significant improvement in lesions during this timeframe. This interval likely corresponds to the duration necessary for the regeneration of the epithelium.

The results of the current study demonstrated that both leukoplakia and OLP lesions exhibited a notable enhancement in clinical ratings within the retinoids group. This improvement was statistically significant and was more pronounced after 4 weeks of therapy compared to 2 weeks. The clinical outcomes in the retinoids group aligned with the findings of previous studies (Epstein and Gorsky, 1999; Starzyńska et al., 2015) that established the efficacy of comparable dosages of retinoids in treating oral leukoplakia, albeit with varying treatment periods. In a study conducted by Starzyńska et al. (2015), it was shown that retinoids led to improvement in more than 77% of patients with leukoplakia following a treatment period of 4 weeks. In addition, Piattelli et al. (2007), Scardina et al. (2006), and Tetè et al. (1999) have shown that topical retinoids or isotretinoids can ameliorate oral leukoplakia lesions. Nevertheless, the dosages used in the previous experiment were greater and were administered for a longer duration compared to the current trial. In addition, other studies (Kar et al., 1996; Laeijendecker et al., 2005) have compared topical retinoids with a dosage equivalent to our research to topical corticosteroids. These studies found that the retinoids groups showed a higher improvement in symptoms.

Nevertheless, our findings contradicted the conclusions of Buajeeb et al. (1997) and Scardina et al. (2006) since they did not demonstrate a substantial advantage of retinoids compared to topical steroids. Possible factors contributing to the disparities between the prior investigation and the current investigation include the extent of lesions, the specific retinoid employed, the kind of vehicle used, and the duration of therapy. In conclusion, it is feasible to verify the therapeutic efficacy of topical retinoids on OLP. Their advantages were proven by clinical, histological, and ultrastructural demonstrations. They can serve as a viable treatment option instead of corticosteroids or can be used in conjunction with them (Petruzzi et al., 2013). Indeed, the World Workshop in Oral Medicine IV guidelines (Al-Hashimi et al., 2007) established that they were regarded as the second choice for treating OLP.

The data from the study demonstrated that both leukoplakia and OLP lesions exhibited a substantial increase in clinical ratings within the group treated with Vitamin D derivative. This improvement was shown to be statistically higher after 4 weeks compared to the 2-week treatment period. Furthermore, in the current clinical study, after 4 weeks, the proportion of patients showing improvement was somewhat greater in the Vitamin D derivative group compared to the retinoids group, but the difference between the two groups was not statistically significant. These findings were consistent with the results of a non-blinded study done by Femiano et al. (2001). Their findings indicated that 80% of patients in both the Vitamin D derivative and retinoids groups achieved complete clinical clearance of lesions by the fifth week of therapy, which aligns with the outcomes of the current research. The present investigation revealed that topical Vitamin D derivative is equally beneficial in treating oral leukoplakia as topical retinoids, as stated by previous research.

The findings of our study showed a substantial decrease in the level of salivary MMP-9 ($\mu\text{g/L}$) in the group treated with Vitamin D derivative, and this decrease was statistically significant. The findings were consistent with Meephansan et al. (2012), who discovered that Vitamin D derivative effectively inhibited the generation of MMP-9 mRNA and proteins in a human squamous cell carcinoma cell line. This suppression was observed to be dose-dependent. Furthermore, our

findings demonstrated a substantial decrease in MMP-9 levels following treatment with both retinoids and Vitamin D derivative. Nevertheless, the group treated with Vitamin D derivative had a statistically significant greater decrease in salivary MMP-9 levels compared to the group treated with retinoids.

Based on these findings, it can be inferred that the ability of both retinoids and Vitamin D derivative to inhibit the process of malignant transformation and enhance clinical outcomes may be attributed to their impact on MMP-9 expression. The significant impact of Vitamin D derivative in reducing salivary MMP-9 levels provides more evidence to support the idea that Vitamin D derivative may serve as a viable alternative to retinoids in the treatment of premalignant lesions.

References

- Al-Hashimi, I., Schifter, M., Lockhart, P. B., Wray, D., Brennan, M., Migliorati, C. A., Axéll, T., et al. (2007). Oral lichen planus and oral lichenoid lesions: diagnostic and therapeutic considerations. *Oral surgery, oral medicine, oral pathology, oral radiology, and endodontics*, 103 Suppl, S25.e1–12.
- Bahar-Shany, K., Ravid, a., and Koren, R. (2010). Upregulation of MMP-9 production by TNF?? in keratinocytes and its attenuation by vitamin D. *Journal of Cellular Physiology*, 222(3), 729–737.
- Bikle DD. Vitamin D: Production, Metabolism and Mechanisms of Action. [Updated 2021 Dec 31]. In: Feingold KR, Anawalt B, Blackman MR, et al., editors. Endotext [Internet]. South Dartmouth (MA): MDText.com, Inc.; 2000-. Available from: <https://www.ncbi.nlm.nih.gov/books/NBK278935/>
- Brouns ER, Baart JA, Bloemena E, Karagozoglu H, van der Waal I. The relevance of uniform reporting in oral leukoplakia: definition, certainty factor and staging based on experience with 275 patients. *Med Oral Patol Oral Cir Bucal*. 2013 Jan 1;18(1):e19-26. doi: 10.4317/medoral.18756. PMID: 23085711; PMCID: PMC3548640.
- Buajeeb, W., Medicine, O., Kraivaphan, P., and Poburksa, C. (1997). Efficacy of topical retinoic acid compared with topical fluocinolone acetonide in the treatment of oral lichen planus. *Oral Surgery, Oral Medicine, Oral Pathology, Oral Radiology and Endodontology*, 83(1), 21–25.
- Chen, Y., Zhang, W., Geng, N., Tian, K., and Jack Windsor, L. (2008). MMPs, TIMP-2, and TGF-beta1 in the cancerization of oral lichen planus. *Head & neck*, 30(9), 1237–1245.
- Chen Shuting , Hu Qinchao , Tao Xiaoan , Xia Juan , Wu Tong , Cheng Bin , Wang Juan. (2022). Retinoids in cancer chemoprevention and therapy: Meta-analysis of randomized controlled trials. *Frontiers in Genetics*, 13, 1-14.
- Dutta, A., Sen, T., and Chatterjee, A. (2010). All-trans retinoic acid (ATRA) downregulates MMP-9 by modulating its regulatory molecules. *Cell Adhesion and Migration*, 4(3), 409–418.
- Epstein, J. B., and Gorsky, M. (1999). *Topical application of vitamin A to oral leukoplakia: A clinical case series. Cancer* (Vol. 86).
- Feller, L., and Lemmer, J. (2012). Oral leukoplakia as it relates to HPV infection: A review. *International Journal of Dentistry*, 2012.
- Femiano, F., Gombos, F., Scully, C., Battista, C., Belnome, G., and Esposito, V. (2001). Oral leukoplakia: open trial of topical therapy with Vitamin D derivative compared with retinoids. *International journal of oral and maxillofacial surgery*, 30(5), 402–406.
- Gonzalez-Moles, M. A., Scully, C., and Gil-Montoya, J. A. (2008). Oral lichen planus: Controversies surrounding malignant transformation. *Oral Diseases*.
- Günther, S. H. (1973). Vitamin A acid in treatment of oral lichen planus. *Archives of dermatology*, 107(2), 277.
- Gupta, S., and Jawanda, M. K. (2015). Oral Lichen Planus: An Update on Etiology, Pathogenesis, Clinical Presentation, Diagnosis and Management. *Indian journal of dermatology*, 60(3), 222–9. Medknow Publications and Media Pvt. Ltd.
- Kar, H. K., Parsad, D., Gautam, R. K., Jain, R. K., and Sharma, P. K. (1996). Comparison of topical

- retinoids and betamethasone in oral lichen planus. *Indian journal of dermatology, venereology and leprology*, 62(5), 304–5.
- Kini, G., Nagaratna, D., and Saha, A. (2011). Therapeutic Management of Oral Lichen Planus: A Review for the Clinicians. *world journal of dentistry*, 2(3), 249–253.
- Laeijendecker, R., van Joost, T., Kuizinga, M. C., Tank, B., and Neumann, H. a M. (2005). Premalignant nature of oral lichen planus. *Acta dermato-venereologica*, 85(6), 516–520.
- Liu, Y., Chen, H., Wang, J., Zhou, W., Sun, R., and Xia, M. (2015). Association of serum retinoic acid with hepatic steatosis and liver injury in nonalcoholic fatty liver disease. *The American journal of clinical nutrition*, 102(1), 130–7.
- Lodi, G., Franchini, R., Warnakulasuriya, S., Varoni, E. M., Sardella, A., Kerr, A. R., Carrassi, A., et al. (2016). Interventions for treating oral leukoplakia to prevent oral cancer. *The Cochrane database of systematic reviews*, 7(7), CD001829.
- Meehansan, J., Komine, M., Tsuda, H., and Ohtsuki, M. (2012). Suppressive effect of Vitamin D derivative on the induction of matrix metalloproteinase (MMP)-9 and MMP-13 in a human squamous cell carcinoma cell line. *Clinical and Experimental Dermatology*, 37(8), 889–896.
- Nagler, R. M., Lischinsky, S., Diamond, E., Klein, I., and Reznick, a Z. (2001). New insights into salivary lactate dehydrogenase of human subjects. *The Journal of laboratory and clinical medicine*, 137(5), 363–9.
- Nogueira, P. a., Carneiro, S., and Ramos-e-Silva, M. (2015). Oral lichen planus: an update on its pathogenesis. *International Journal of Dermatology*, 54(9), 1005–1010.
- Petruzzi, M., Lucchese, A., Lajolo, C., Campus, G., Lauritano, D., and Serpico, R. (2013). Topical retinoids in oral lichen planus treatment: An overview. *Dermatology*, 226(1), 61–67.
- Piattelli, A., Carinci, F., Iezzi, G., Perrotti, V., Goteri, G., Fioroni, M., and Rubini, C. (2007). Oral lichen planus treated with 13-cis-retinoic acid (isoretinoids): Effects on the apoptotic process. *Clinical Oral Investigations*, 11(3), 283–288.
- Rai, B., Kharb, S., Jain, R., and Anand, S. C. (2008). Biomarkers of periodontitis in oral fluids. *Journal of oral science*, 50(1), 53–56.
- Rathnayake, N., Gustafsson, A., Norhammar, A., Kjellström, B., Klinge, B., Rydén, L., Tervahartiala, T., et al. (2015). Salivary Matrix Metalloproteinase-8 and -9 and Myeloperoxidase in Relation to Coronary Heart and Periodontal Diseases: A Subgroup Report from the PAROKRANK Study (Periodontitis and Its Relation to Coronary Artery Disease). *Plos One*, 10(7), e0126370.
- Reunanen N, Kähäri VM. Matrix Metalloproteinases in Cancer Cell Invasion. (2013) In: Madame Curie Bioscience Database [Internet]. Austin (TX): Landes Bioscience; 2013. Available from: <https://www.ncbi.nlm.nih.gov/books/NBK6598/>
- Scardina, G. a, Messina, P., Carini, F., and Maresi, E. (2006). A randomized trial assessing the effectiveness of different concentrations of isoretinoids in the management of lichen planus. *International journal of oral and maxillofacial surgery*, 35(1), 67–71.
- Shahzad, A., Shahzad, M., and Khurshid, K. (2006). Topical calciumipotriol in dermatology. *Journal of Pakistan Association of Dermatologists*, 104–107.
- Silosi, I., Cojocaru, M., Foia, L., Boldeanu, M. V., Petrescu, F., Surlin, P., and Biciusca, V. (2015). Significance of Circulating and Crevicular Matrix Metalloproteinase-9 in Rheumatoid Arthritis-Chronic Periodontitis Association. *Journal of Immunology Research*, 2015, 6.
- Stott-Miller, M., Houck, J. R., Lohavanichbutr, P., Méndez, E., Upton, M. P., Futran, N. D., Schwartz, S. M., et al. (2011). Tumor and salivary matrix metalloproteinase levels are strong diagnostic markers of oral squamous cell carcinoma. *Cancer Epidemiology Biomarkers and Prevention*, 20(12), 2628–2636.

- Tetè, S., Pappalardo, S., Rubini, C., Salini, L., Falco, A., and Perfetti, E. G. (1999). The role of apoptosis and bcl-2 protein in topical treatment of oral leukoplakia with isotretinoids. *Minerva stomatologica*, 48(9), 411–8.
- Thongprasom, K., Prapinjumrune, C. and Carrozzo, M. (2013) ‘Novel therapies for oral lichen planus’, *Journal of Oral Pathology and Medicine*, 42(10), pp. 721–727.
- Umehara Y, Trujillo-Paez JV, Yue H, Peng G, Nguyen HLT, Okumura K, Ogawa H, Niyonsaba F. (2023). Calcitriol, an Active Form of Vitamin D3, Mitigates Skin Barrier Dysfunction in Atopic Dermatitis NC/Nga Mice. *Int J Mol Sci*. 2023 May 27;24(11):9347. doi: 10.3390/ijms24119347. PMID: 37298299; PMCID: PMC10253123.
- Volz, T., Caroli, U., Lüdtke, H., Bräutigam, M., Kohler-Späth, H., Röcken, M., and Biedermann, T. (2008). Pimecrolimus cream 1% in erosive oral lichen planus - A prospective randomized double-blind vehicle-controlled study. *British Journal of Dermatology*, 159(4), 936–941.
- Warnakulasuriya S, Kujan O, Aguirre-Urizar JM, et al. (2021). Oral potentially malignant disorders: a consensus report from an international seminar on nomenclature and classification, convened by the WHO collaborating centre for oral cancer. *Oral Dis.*, 27(8):1862-1880.