

<https://doi.org/10.48047/AFJBS.5.2.2023.97-121>



African Journal of Biological Sciences



Open Access

Research Paper

Investigation the Effect of Monosodium Glutamate (MSG) on thyroid gland and sex hormone Levels in Male Rats

Noor Ali Zayed^{1*}, Noori Mohammed Luaib², Raghad Harbi Mahdi³

¹ Biology Department, College of Science, Mustansiriyah University, Baghdad, Iraq

² Biology Department, College of Science, Mustansiriyah University, Baghdad, Iraq.

³ Biology Department, College of Science, University of Baghdad, Baghdad, Iraq.

Article Info

Volume 5, Issue 2, April 2023

Received: 17 Feb 2023

Accepted : 08 March 2023

Published : 24 April 2023

doi: 10.48047/AFJBS.5.2.2023.97-121

Background

Monosodium glutamate (MSG) is a main flavor enhancer used as a food additive . MSG is one the commonest food additive. It has been used as taste enhancer since 1907 by a Japanese professor .

Method : this study uses 54 male rats were scattered into nine group, each groups had 6 rats , Group 1,2 and 3 (control group); the experimental groups (Group 4, 5, and 6) ; they rats respectively received intra-peritoneal dose (60mg/kg) of monosodium glutamate for (2, 4 and 8) weeks . and other the experimental groups (Group 7,8 and 9); the rats respectively received intra-peritoneal dose (30 mg/kg) of monosodium glutamate for (2,4 and 8) weeks .

Result: Long term exposure to MSG with different doses increased thyroid and testis weight , also increase in TSH and decrease in thyroid hormone (T3,T4) . as well as increased doses of MSG and treatment time caused decrease serum levels of sex hormone (testosterone , LH and FSH) serum levels . indication that MSG administration to male Wistar rats altered parameters.

Keywords: MSG; Thyroid gland , thyroid hormone , sex hormone , testosterone , LH , FSH ; Rats

© 2023 Noor Ali Zayed, This is an open access article under the CC BY license (<https://creativecommons.org/licenses/by/4.0/>), which permits unrestricted use, distribution, and reproduction in any medium, provided you give appropriate credit to the original author(s) and the source, provide a link to the Creative Commons license, and indicate if changes were made

1 Introduction

Monosodium glutamate (MSG), also termed sodium glutamate, is the sodium salt of naturally occurring glutamic acid. MSG is naturally created by microbial fermentation, organic synthesis, or vegetable protein hydrolysis and produced synthetically by an organic reaction on acrylate. At room temperature MSG naturally occurs as a white crystalline salt that is soluble in water and alcohol (Meister, 1979). MSG is used generally as a flavour enhancer because it balances, balances and rounds the total perception of other tastes (Loliger, 2000).

MSG is a common glutamic acid salt. It has 78% glutamic acid, 22% sodium salt and water (Samuels, 1999). Glutamate is one of the greatest public amino acids present in wildlife. It is the core constituent of tissue proteins and peptides. There are two main sources of glutamate; the body itself can form glutamate as it plays a critical role in human metabolism; the second is the protein-rich food products as fish, meat, milk and cheese or vegetable origins as mushroom and tomato (FIC, 1994). MSG is commonly used as a flavor enhancer in home as well as in food industry. Therefore, most of canned and fast food as chips, canned soups, prepared meals, marinated meats, bottled soy or oriental sauces, freezing foods and tinned tuna containing variable concentrations of MSG (Bojanić *et al.*, 2009). The thyroid is the larger endocrine glands of the body and it is a highly vascular structure that shape like a butterfly, it consists of two soft lateral large lobes which linked by a stretch of tissue known as "isthmus" (Wilson, 2002). The main primary function of the thyroid

gland is synthesis and secretion of thyroid hormones T3 and T4, that control important functions, such as basal metabolic rate (BMR), the promotion of protein synthesis and growth and regulation of energy metabolism (Thies, 2012). The Testes are primary male sex organs, the adult testis has two main roles, the production of spermatozoa and the secretion of testosterone which is needed for the expression of secondary sexual characteristics. These functions depend on stimulation by the pituitary gonadotrophins, follicle-stimulating hormone (FSH) and luteinizing hormone (LH), which are stimulated by hypothalamic gonadotrophin-releasing hormone (GnRH). Testosterone is secreted by the Leydig cells under LH stimulation is important for stimulating spermatogenesis. Though FSH has a role in the development of the immature testis, controversy persists as to whether FSH is essential for the maintenance of adult spermatogenesis. A better understanding of the hormonal requirements of adult spermatogenesis is needed for the development of rational treatments for human infertility and in designing contraceptive strategies.

Testosterone is a male androgen created by Leydig cells of the testes and by cells in the cortex of the adrenal gland (Urban, 1999). The lowered serum testosterone levels in MSG-treated rats in this study may have resulted from disruption of the hypothalamic-pituitary-testes regulatory axis that controls testosterone production by testicular Leydig cells.

2. Materials and methods

2.1 Animals

Adult Male Sprague- Dawley albino rats (Rattus norvegicus) , the age about 2-3 months, average body weight 200-225 g . and the animal were obtained from the national center for drug control and research (NCDCR) /ministry of health the animals then transferred to the animal house of the college of science \AL-Mustansyria University . the males rats were saved in clean separated plastic cages with metal network cover under climate controlled condition of the animal house with 22-25 temperature , 60% humidity, 12 hours light and darkness, and free access to food libitum and water .

2.2 experimental design

The present study were used 54 male rats randomly divided into three groups treated at different period 2 weeks ,1 months and 2 months

Each groups had six rats :

Group 1,2,3 (control groups) : received respectively intra peritoneal injection of distilled water for different period (2,4,8) weeks

Group 4,5,6 (experimental groups) : received respectively intra peritoneal injection dose (60 mg /kg) for different period (2,4,8) weeks

Group 7,8,9 (experimental groups) : received respectively intra peritoneal injection dose (30mg /kg) for different period (2 ,4,8) weeks

2.3 Preparation of Monosodium Glutamate solution

1. Group (1) injected with 30 mg/kg of Monosodium Glutamate (Low dose) in the intra peritoneal rout.

The solution prepared by dissolving 60 mg of Monosodium Glutamate in 10 ml of distilled water (Alalwani , 2014) .

2. Group (2) injected with 60 mg/kg of Monosodium Glutamate (High dose) in the intra peritoneal rout.

The solution was prepared by dissolving 120 mg of Monosodium Glutamate in 10 ml of distilled water .

2.4 Collection of Blood Samples

At The end of each experiment ,followed by weighing the animals, and they were completely anaesthetized by diethyl ether for several minutes and blood samples were gotten by heart puncture were collected in to heparinized and non-heparinized tubs used in hormonal , biochemical and hematological ,immunological and molecular examination . 4 ml of blood collected from each rat was used to obtain sera (0.5-1.0) ml separated by centrifugation 3000 rpm for 5 min, then they were kept in -20°C until analysis. The rats were separated and their organs, liver ,thyroid gland, liver, kidneys and testes were removed, then washed with normal physiological saline 0.9% (NaCl) to removed blood , blotted with filter paper ,the weighed and kept in the fixative solution neutral buffered 10% formalin .

2. 5 Thyroid hormone

2.5.1. T3 hormone

It was represented by enzyme –lined immunosorbent assay (ELISA) kit for quantitative determination of concentration of T3 according to mybiosource/USA

2.5. 2 T4 Hormone

It was represented by the enzyme–lined immunosorbent assay (ELISA) for quantitative determination of concentration of T4 according to mybiosource/USA

2.5.3 TSH Hormone

It was represented by the enzyme immunoassay tests (ELISA) for quantitative determination of concentration of TSH according to mybiosource /USA

2.6 Sex hormone

2.6.1 LH Hormone

It was represented by the enzyme –lined immunosorbent assay (ELISA) for quantitative determination of concentration of LH according to mybiosource /USA

2.6.2 FSH Hormone

It was represented by the enzyme–lined immunosorbent assay (ELISA) for quantitative determination of concentration of FSH according to mybiosource/ USA

2.6.3 Testosterone Hormone

It was represented by the enzyme –lined immunosorbent assay (ELISA) for quantitative determination of concentration of Testosterone according to mybiosource / USA

2.7 Statistical Analysis

The Statistical Analysis System- SAS (2012) program was used to effect of difference factors (concentration of MSG and period) in study parameters . Least significant difference –LSD test (ANOVA) was used to significant compare between means in this study.

2.8 Thyroid gland

2.8.1. Thyroid weight

The result showed MSG effects on thyroid weights as different dose as it demonstrated in figure (1) . the animal rats exposed to MSG for 2 weeks demonstrated high significant increase ($p \leq 0.05$) in thyroid weight of treated rats with different dose (30 and 60) mg/kg (0.205+0.01),(0.261+0.02) respectively compare to control groups (0.171+0.01)mg , as well as there was high significant increase ($p \leq 0.05$) in thyroid weight exposed to MSG for 4weeks with different dose (30 and 60) mg /kg (0.230+0.01),(0.368+0.01)mg respectively in comparison to control groups (0.176+0.01)mg .also when rats exposed to MSG for 8weeks showed high significant increase ($p \leq 0.05$) in thyroid weight (0.260+0.02),(0.538+0.01)mg respectively compare to control groups (0.178+0.01)gm .

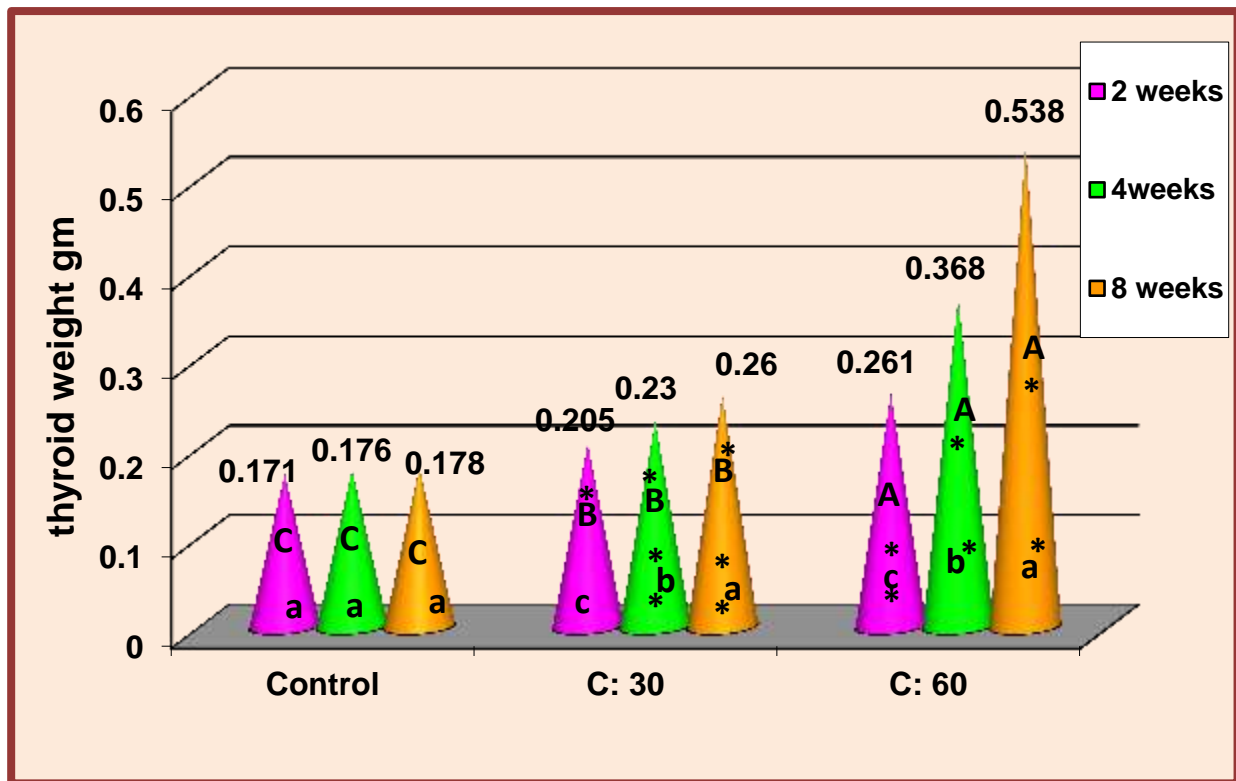


Fig. 1: Effect of different concentrations of MSG (30,60) gm/kg on thyroid weight of rats with different periods of time (2,4,8) weeks in comparison with control groups. * significant increase ($P \leq 0.05$).

(A,B,C) Represent the significant difference between groups with days as a fixed factor and concentrations as a variable factor. (a,b,c) represent the significant difference between groups with concentrations as a fixed factor and days as a variable factor

2.8.2 Thyroid functions

The statistical analysis of the current study for the effect of MSG on thyroid hormone functions included TSH, T3, T4 figure (2),(3)(4) reveals that :

The values of TSH figure (2) showed high significant increase ($p \leq 0.05$) at different dose of MSG (30 and 60) mg/kg for different duration (2,4 and 8) weeks (7.47+0.11), (11.97+0.41), (8.54+0.08), (17.38+0.40), (10.67+0.04), (23.48+0.52) respectively in comparison to control groups (6.30+0.08), (6.52+0.12), (6.61+0.10).

-high significant decrease ($p \leq 0.05$) in serum level of T3 (ng/ml) of different dose (30 and 60) mg/kg (2.08+0.02), (1.59+0.02) (ng/ml) respectively when exposed to MSG for 2 weeks in comparison to control groups (2.96+0.04) (ng/ml), also there was a high significant decrease ($p \leq 0.05$) in level of T3 for 4 weeks at both dose (30 and 60) mg/kg (2.18+0.04), (0.848+0.10) ng/ml respectively compare to control groups (2.70+0.03) ng/ml. also there was high significant decrease in serum level of T3 at dose (30 and 60) mg/kg in 4 weeks (1.89+0.03), (0.246+0.04) ng/ml in compare to control groups (2.17+0.04) ng/ml figure 3

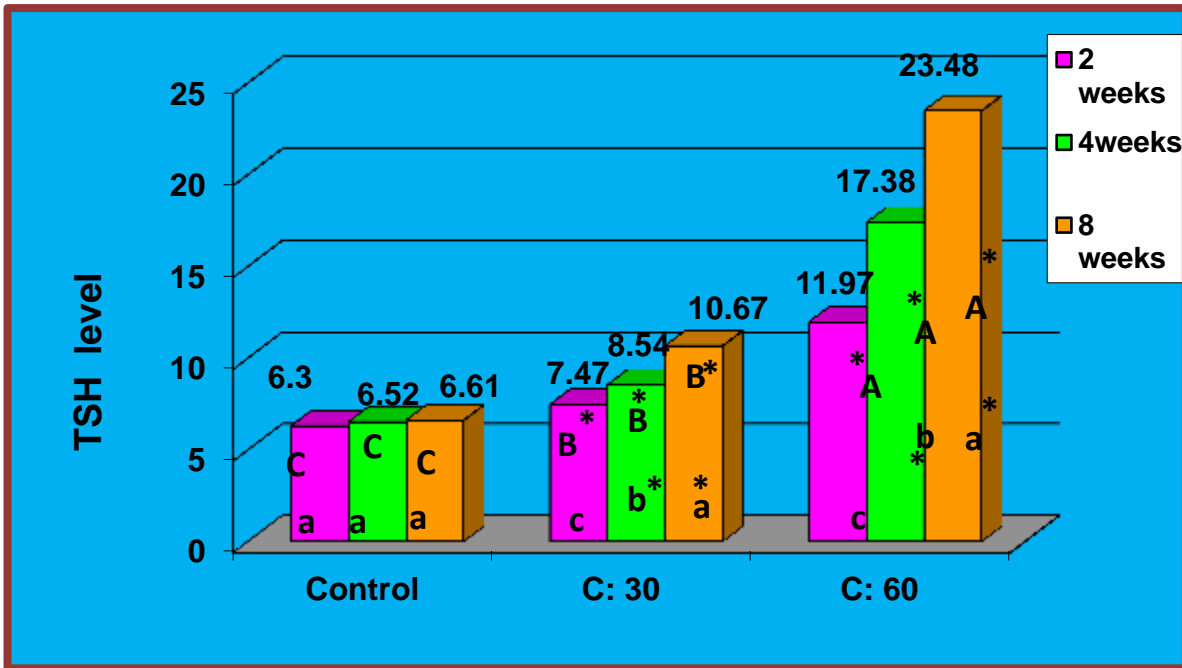


Fig. 2: Effect of different concentrations of MSG (30 ,60)gm/kg on T3levels of rats with different periods of time (2,4,8) weeks in comparison with control groups.

* high Significant increase ($P \leq 0.05$).

(A,B,C) Represent the significant difference between groups with days as a fixed factor and concentrations as a variable factor.

(a,b,c) represent the significant difference between groups with concentrations as a fixed factor and days as a variable factor

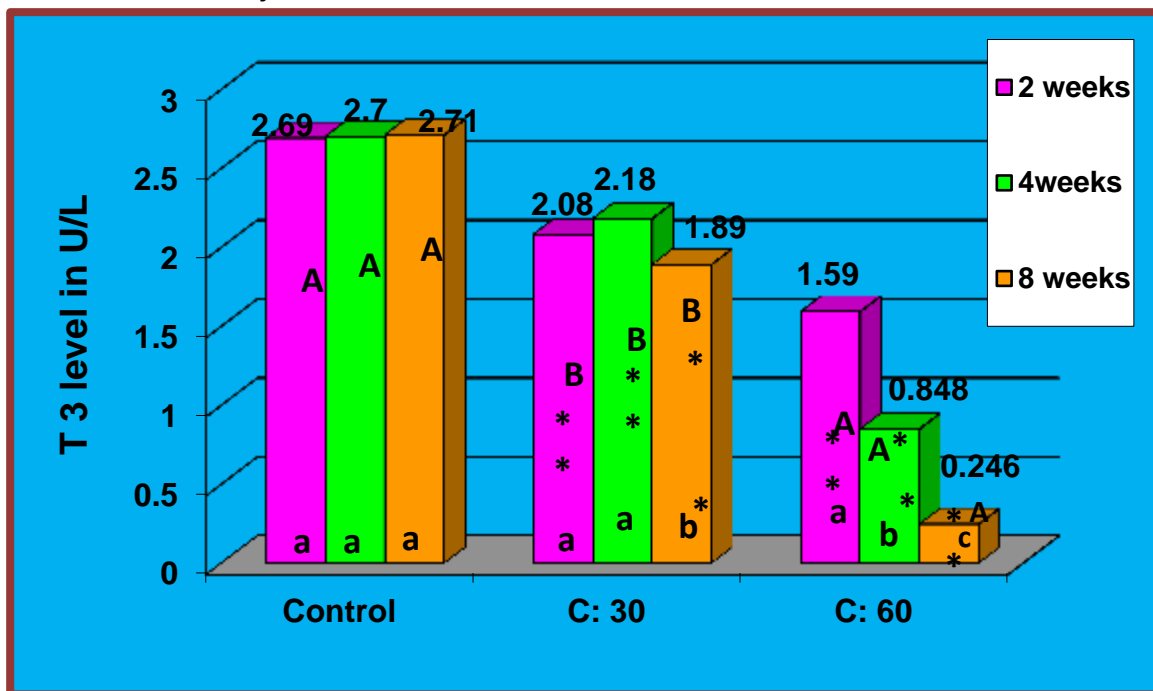


Fig. 3: Effect of different concentrations of MSG (30 ,60)gm/kg on T3levels of rats with different periods of time (2,4,8) weeks in comparison with control groups.

* Significant decrease ($P \leq 0.05$).

(A,B,C) Represent the significant difference between groups with days as a fixed factor and concentrations as a variable factor. (a,b,c) represent the significant difference between groups with concentrations as a fixed factor and days as a variable factor

-the values of serum T4 display a high significant decrease ($p \leq 0.05$) of both dose (30 and 60) mg/kg (55.73 ± 0.83), (32.04 ± 0.58) (mg/dl) respectively at 2 weeks in comparison to control groups (75.01 ± 1.13) (mg/dl). At 4 weeks showed high significant decrease in level of T4 in both dose (30 and 60) mg/kg (43.35 ± 0.63), (19.32 ± 0.34) (mg/dl) respectively compare to control groups (75.29 ± 1.04) (mg/dl). as well as the 8 weeks showed high significant decrease in level of T4 in both dose (30 and 60) mg/kg (34.23 ± 0.72), (7.26 ± 0.34) mg/dl in comparison to control groups (75.42 ± 0.94) mg/dl figure 4.

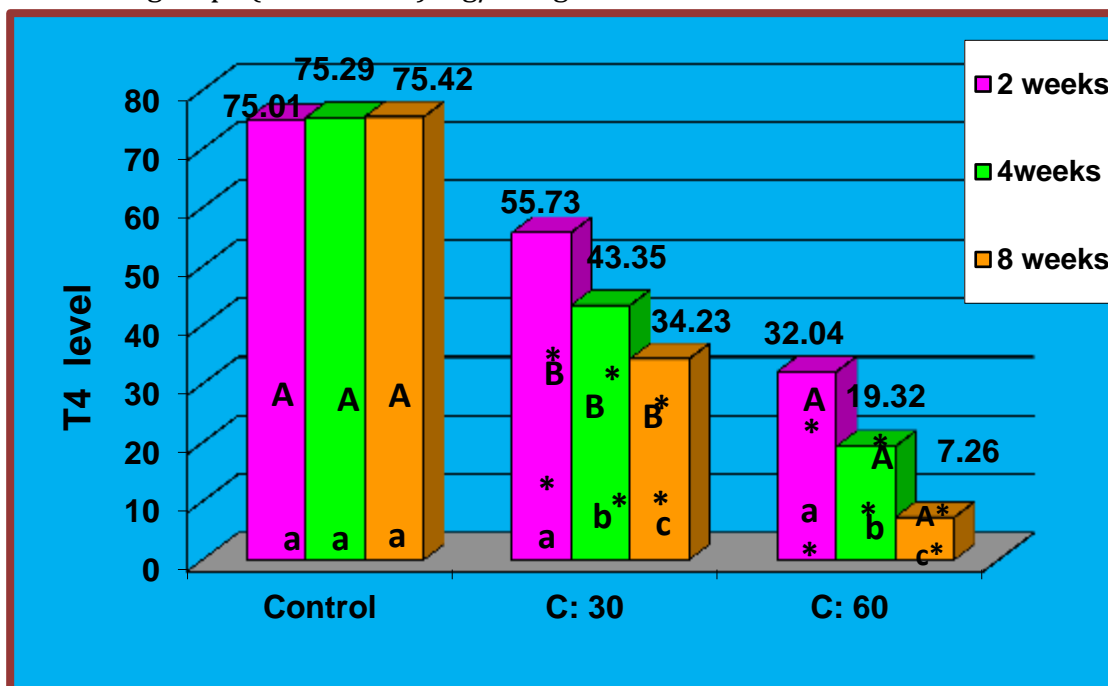


Fig. 4: Effect of different concentrations of MSG (30, 60) gm/kg on T4 levels of rats with different periods of time (2, 4, 8) weeks in comparison with control groups.

*high Significant decrease ($P \leq 0.05$).

(A,B,C) Represent the significant difference between groups with days as a fixed factor and concentrations as a variable factor. (a,b,c) represent the significant difference between groups with concentrations as a fixed factor and days as a variable factor

A study by Bakke *et al.*, (1978) which disagree with present study, they were used the animals (rats, mice) exposure to MSG (dose varying from 2.2 to 4 mg / kg of body wt.) showed, there were reduction in weight of thyroid, also disagree with present study by reduced in Serum level of (TSH) in the males, but agree with present study that showed decrease in Serum T₄ in females. Results of the present study are in agreement with previous reports of MSG causing of thyroid weight

The previous Studies were performed on male Wistar strain rats, injected with MSG, at 4 mg/g body weight, on days 2, 4, 6, 8 and 10 of life showed that experimental rat thyroids weight significant increase that agree with present study but were highest in the group of 12-month-old rats is agree to new study by decrease the serum T4 level. But is disagree with present study by observed an increase in the serum T3 Miskowiak & Partyka . (1993) , agree level (Waer & Edress . (2006). A previous study with present study by increase in body weight also is agree by decrease in serum level of T4 . but previous study disagree with current study by increase in serum level of T3 .

A previous study by Abd Allah . (2021) , showed when The rats were divided into 5 groups (6 rats in each group), control group (G1), MSG group (G2): treated with MSG (60 mg/k g b.wt./ day), MSG+ 0.5% Sp group (G3), MSG+ 1% Sp group (G4), and MSG+ 2% Sp group (G5). The experiment continued for 28 days. Thyroid gland was examined , showed a significant increase in thyroid-stimulating hormone (TSH) in rats treated with MSG , that agree with present study , and also showed significant decrease in Tri-iodothyronine (T3) and thyroxine (T4) hormone levels that also agree with current study . a current study dis- agree with a previous study by Helal et al., (2019) , when The Animals were divided into four groups; Group 1 (Control untreated group and Group (Mono sodium glutamate-treated group),who found that the MSG recorded a highly significant increase in T3 and T4 level ($p < 0.01$). the previous by Ali et al.,2012 and Sabr (2015) who suggested that loss of thyroid hormones, maybe caused by loss of thyroxin binding globulin along with T4 bound to (2015) , when The , it, thus stimulating TSH production. A study by Khalaf & Arafat rats were divided into four groups: group I control, group II, III and IV treated with MSG (0.25 g/kg, 3 g/kg, 6 g/kg daily for one month) respectively, showed The serum level of T3 and T4 was non-significantly increased in the low dose MSG treated group and significantly increased in high and toxic doses treated groups compared to the control one that dis -agree with present study .

a previous study by Helal et al .,(2017) , they were used thirty young male albino rats were divided into three groups : Group I: served as normal control group, Group II: rats orally administrated with the mixture which consists of sodium nitrite (NaNO_2 0.1 mg/kg b.wt./ day), annatto (0.065 mg/kg b.wt./day) and monosodium glutamate (MSG 15 mg/kg b.wt./day) and Group III: rats orally administrated with the previous mixture and then orally administrated with royal jelly (14.28 mg/kg b.wt./day soluble in maize oil). Were demonstrated a highly significant increase in the levels of both T3 and T4 was observed in rats received the mixture ((consists of sodium nitrite+ annatto+ monosodium glutamate) of food additive when compared to control rats. That disagree with present study .

2.8.3 Histological Changes of thyroid

- ❖ The main histological changes in all treated rats with MSG on thyroid tissues in different periods of time compared to control groups is shown as follows: thyroid sections showed different histological changes after treatment with MSG in the concentration of 30gm/kg of body weight for 4 days, included : a wide area of

thyroid follicle damage (necrosis) with rare follicles presence of lock like normal follicle containing colloid material ,figure (6) in comparison with the histological sections of thyroid from control groups of rats Figure (5) . in period 8 weeks , Figure (7) still there is the same damage of follicles with rare follicles containing colloid material and lined by columnar epithelial cells but no scalloping and non-functional in comparison with the histological sections of thyroid from control groups of rats Figure (5) . Histological changes after treatment with MSG in the concentration of 60 mg/kg of body weight figure (8) , for 4 weeks on thyroid sections showed: wide area of necrosis ,few follicles showing scalloping activity of colloid material in comparison with the histological sections of thyroid from control groups of rats Figure (5). In figure (9) ,The experimental group of 8 weeks showed , very wide area of damage (necrosis) and few follicles with colloid material but no scalloping (non- functioning)and lined by flat epithelial cells in comparison with the histological sections of thyroid from control groups of rats Figure (5).

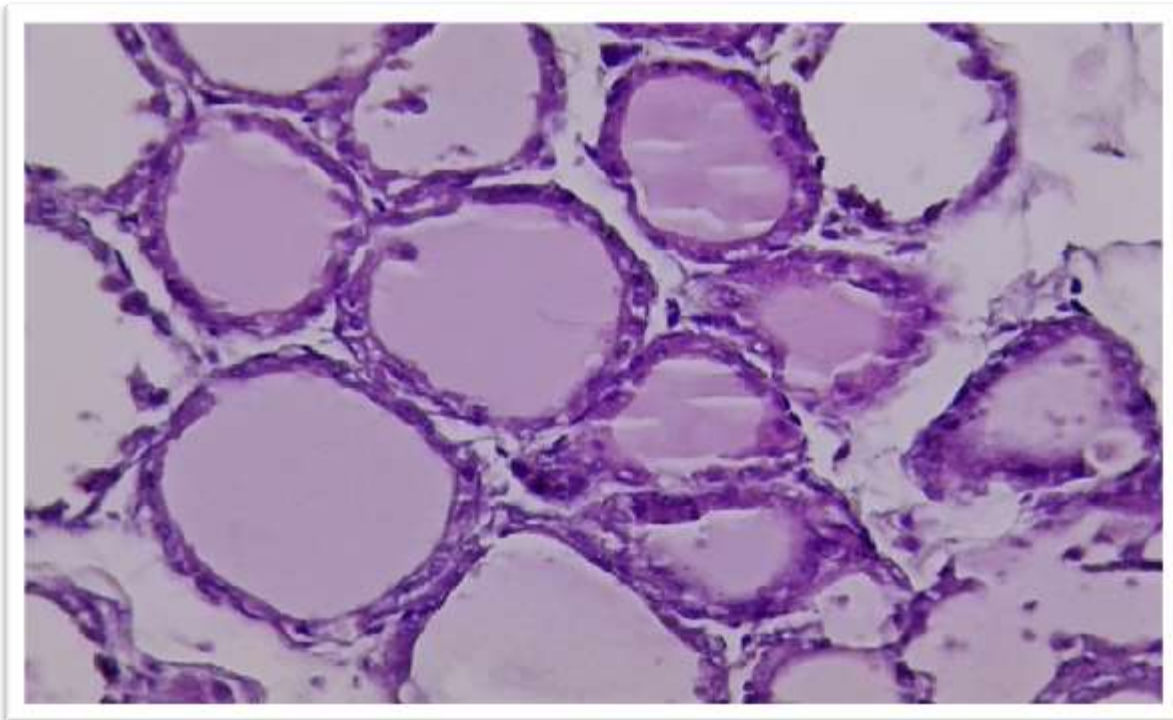


Figure (5) : Section of the normal structure of thyroid from rat control Groups with different size and shape showing : normal histological structure of thyroid follicles containing colloid material H XE (40x) .

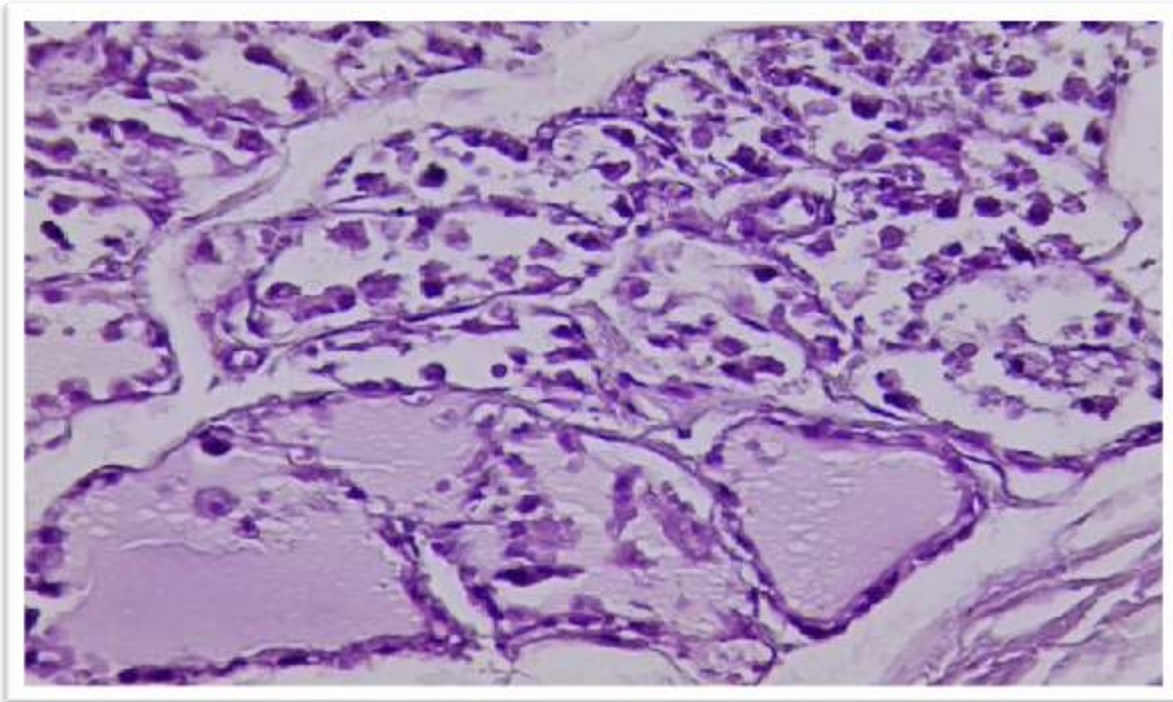


Figure (6) :Section of thyroid of rat group treated with 30 mg/kg of MSG for 4 weeks showing: wide area of thyroid follicle damage (necrosis) with rare follicles presence of lock like normal follicle containing colloid material .

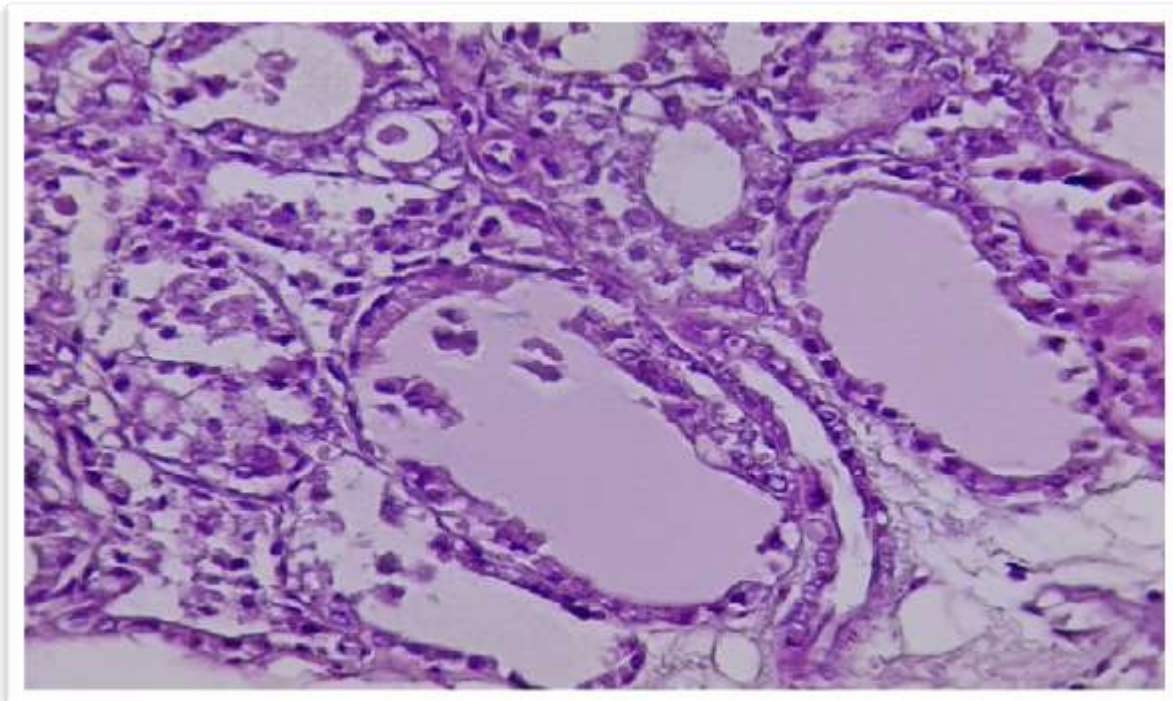


Figure (7) :Section of thyroid of rat group treated with 30 mg/kg of MSG for 8 weeks showing : still there is the same damage of follicles with rare follicles

containing colloid material and lined by columnar epithelial cells but no scalloping and non-functional

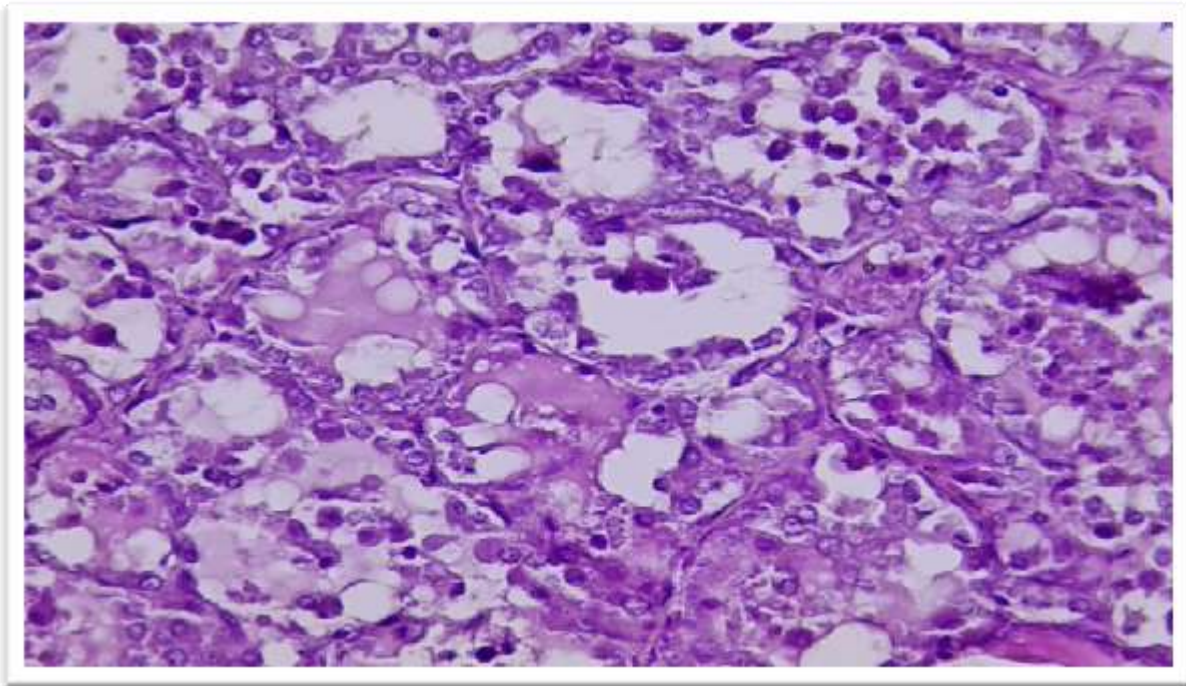
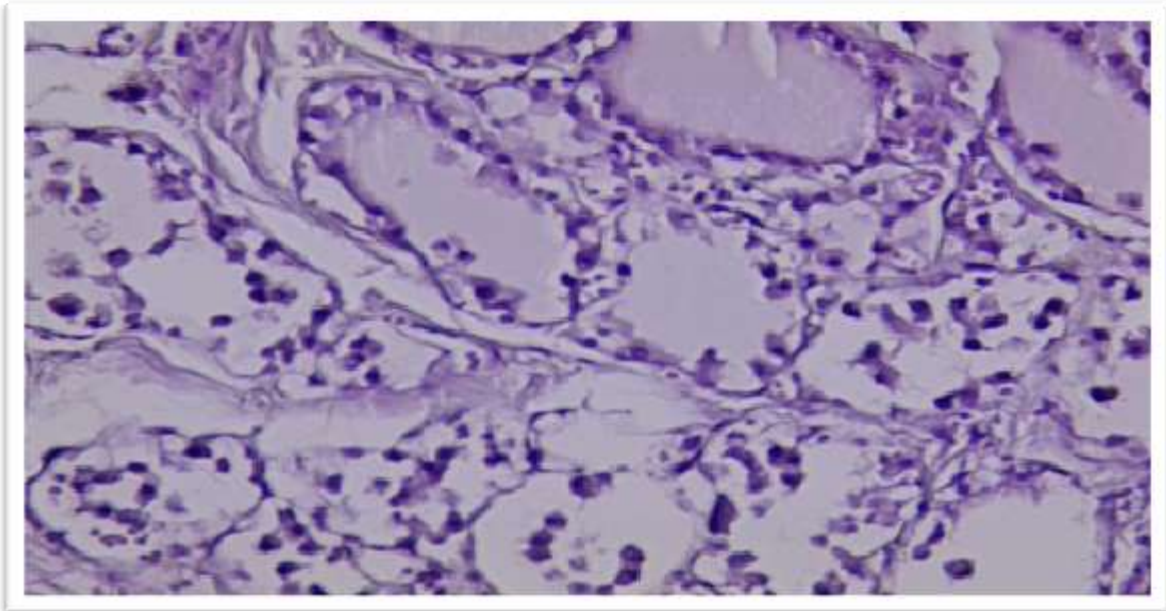


Figure (8): section of thyroid of rat groups treated with 60 mg/kg of MSG for 4 weeks showed wide area of necrosis ,few follicles showing scalloping activity of colloid material .



Figure(9) : section of thyroid of rat groups treated with 60 mg/kg of MSG for 8 weeks showed : very wide area of damage (necrosis) and few follicles with colloid material but no scalloping (non- functioning)and lined by flat epithelial cells .

The results showed that MSG at low doses is capable of creating changes in the thyroid tissue function and histology. and body weights which agree with present study. A study by Dhindsa *et al.*, (1981) observed large follicles bloated with colloid accumulation and lined by squamous cells in young female mice treated with MSG with different doses (2, 4 and 6 mg/g) for 7 seven days and the effects seen after 13 and 52 weeks.

A preceding reported observed large follicles bloated with colloid accumulation and lined by squamous cells in young female mice treated with MSG with different doses (2, 4 and 6 mg/g) for 7 seven days and the effects seen after 13 and 52 weeks (Miskowiak, and Partyka, 2000).

Thus, depending on the dose and type of treatment and species, MSG appear to show different effects on pituitary-thyroid axis. The present study supports the idea that high consumption of food additive (MSG) related to the nutritional deficiency of iodine might participate in the development of hypothyroidism and goiter, in addition thyroid hormone synthesis inhibition

2.9 Testis

2.9.1 Testis weight

The statistical analysis of this study around the weight of right and left testis showed in figure (10), (11). The weight of right testis showed a high significant increase ($p, 0.05$) at 2 weeks treated with different doses (30 and 60) mg/kg (1.24+0.02, 1.52+0.01) gm when compare with control groups (1.09+0.01 gm), also there was a high significant increase in right testis weight at 4 weeks when treated with doses (30 and 60) mg/kg (1.33+0.01, 1.56+0.02) gm compare with control groups (1.08+0.01 gm), the result at 8 weeks showed high significant increase at different doses (30 and 60) mg/kg (1.38+0.01, 1.85+0.02) gm in comparison with control groups (1.08+0.01 gm).

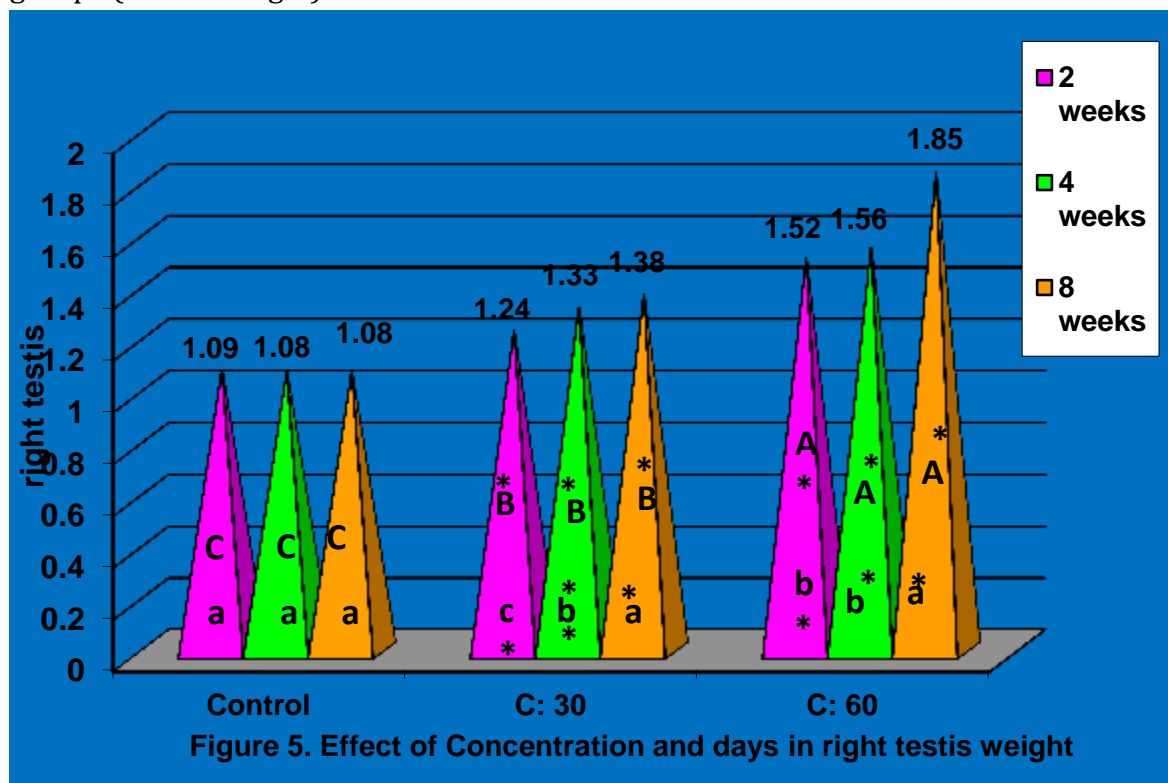


Fig. 10: Effect of different concentrations of MSG (30 ,60)gm/kg on right testis weight levels of rats with different periods of time (2,4,8) weeks in comparison with control groups.

*high Significant increase ($P \leq 0.05$).

(A,B,C) Represent the significant difference between groups with days as a fixed factor and concentrations as a variable factor. (a,b,c) represent the significant difference between groups with concentrations as a fixed factor and days as a variable factor

the weight of left testis at 2 weeks demonstrated high significant increase ($p < 0.05$) at doses (30 and 60) mg/kg (1.28 ± 0.01 , 1.49 ± 0.02) gm compared with control groups (1.11 ± 0.01 gm), as well as there was a high significant increase ($p < 0.05$) at 4 weeks (1.38 ± 0.01 , 1.52 ± 0.01) gm in comparison to control groups (1.11 ± 0.01 gm). while the results at 8 weeks showed high significant increase ($p < 0.05$) (1.45 ± 0.01 , 1.78 ± 0.01) gm when compare with control groups (0.93 ± 0.16 gm). showed in figure (11).

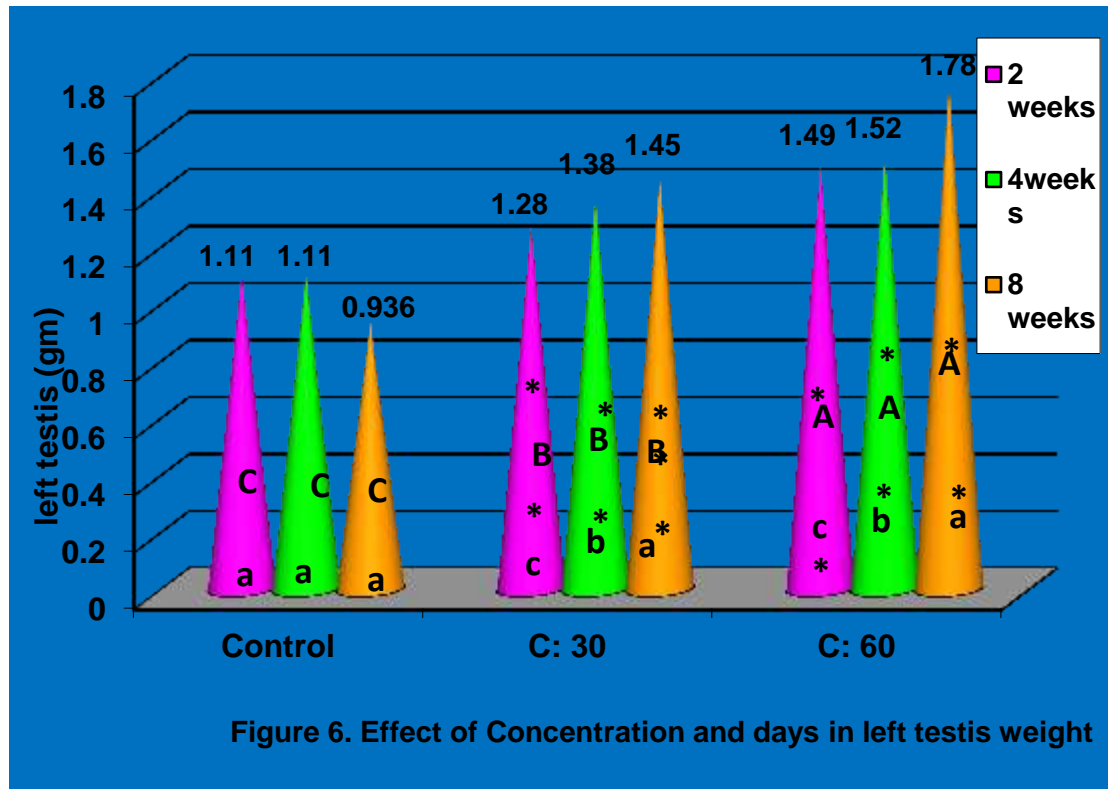


Fig. 11: Effect of different concentrations of MSG (30 ,60)gm/kg on left testis weight levels of rats with different periods of time (2,4,8) weeks in comparison with control groups.

*high Significant increase ($P \leq 0.05$).

(A,B,C) Represent the significant difference between groups with days as a fixed factor and concentrations as a variable factor. (a,b,c) represent the significant difference between groups with concentrations as a fixed factor and days as a variable factor.

2.9.2 Histological changes of testis

: The following diagram illustrates the primary histological alterations in testis tissue in all treated rats with MSG across various time periods when compared to control groups .Following four weeks of treatment with MSG at a dosage of 30 mg/kg of body weight, several histological alterations were seen in testis sections:Lock like normal appearance of maturation spermatogonia cells and presence of sperm . Normal lydig cells presence figure (12) in comparison with the histological sections of testis from control groups of rats Figure (11) .

In concentration 30 mg/kg and period 8 weeks showing immaturation of spermatogonia cells with few of abnormal presence of sperms inside the lumen figure (13) in comparison with the histological sections of testis from control groups of rats Figure (11) .

While testis section histological alterations following treatment with MSG at a dose of 60 mg/kg of body weight for 4 weeks revealed:

More immaturation of spermatogonia with presence of very few abnormal of sperm , with necrotic cell inside the lumen of seminiferous tubules figure (14) in comparison with the histological sections of testis from control groups of rats Figure (11) .

in period 8 weeks at concentration 60 mg/kg of testis section showed more immaturation of spermatogonia , no sperm presence more necrotic cells inside the lumen figure (15) in comparison with the histological sections of testis from control groups of rats Figure (11) .

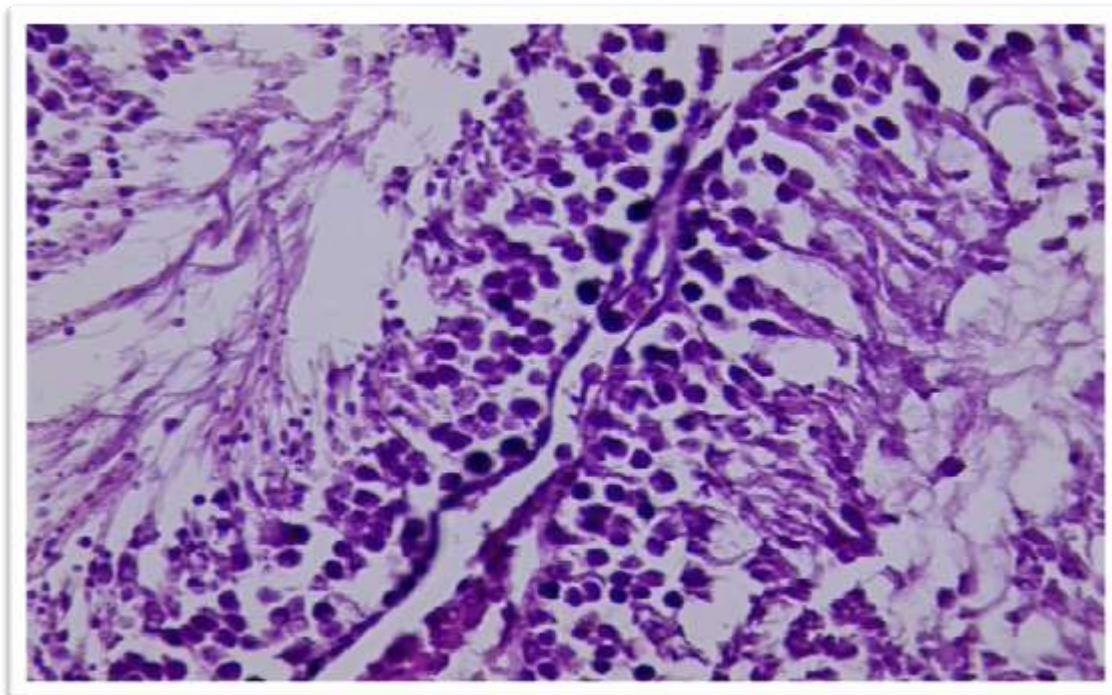


Figure (11) :Section of testis of control showing normal histological appearance of germ cell ,sertoli cell and normal maturation of spermatogonia cell with presence of numerous sperm inside the lumen with presence normal lydig cells HXE(40x).

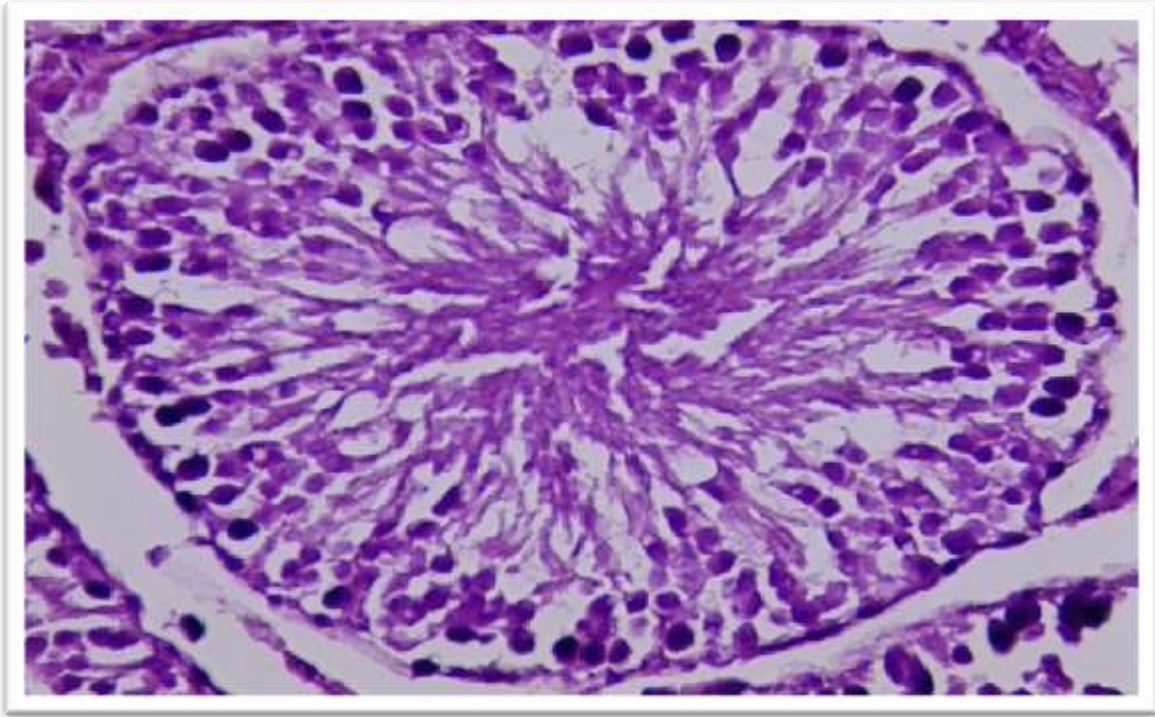


Figure (12) :Section of testis of rat group treated with 30 mg/kg of MSG for 4 weeks showing lock like normal appearance of maturation spermatogonia cells and present of sperm .normal lydig cells present HXE(40x).

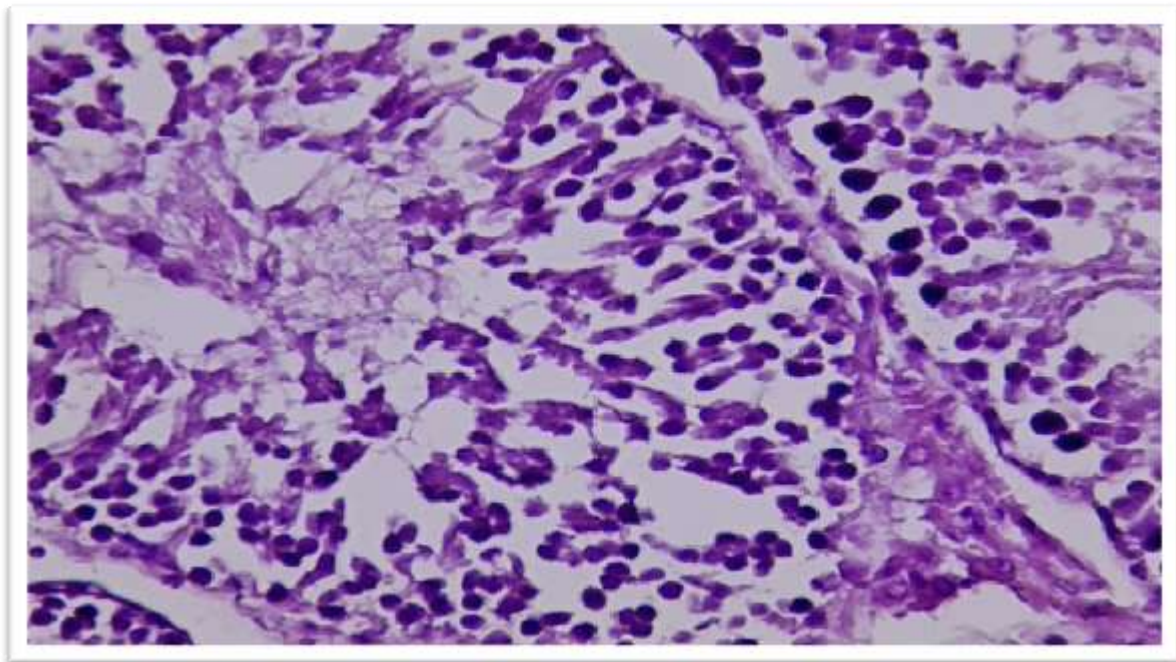


Figure (13) :Section of testis of rat group treated with 30 mg/kg of MSG for 8 weeks showing immaturation spermatogonia cells with few abnormal sperm presence inside the lumen seminiferous tubules HXE(40x).

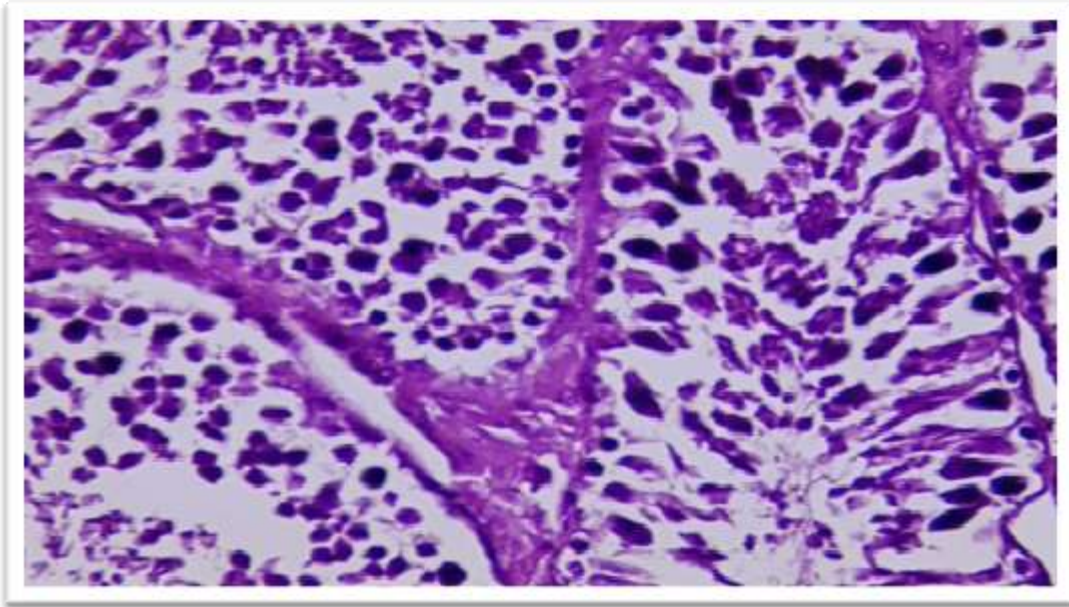


Figure (14) :Section of testis of rat group treated with 60 mg/kg of MSG for 4 weeks showing immaturation of spermatogonia cells with present of very few abnormal sperm with necrotic cell inside the lumen of seminiferous tubules HXE(40x).

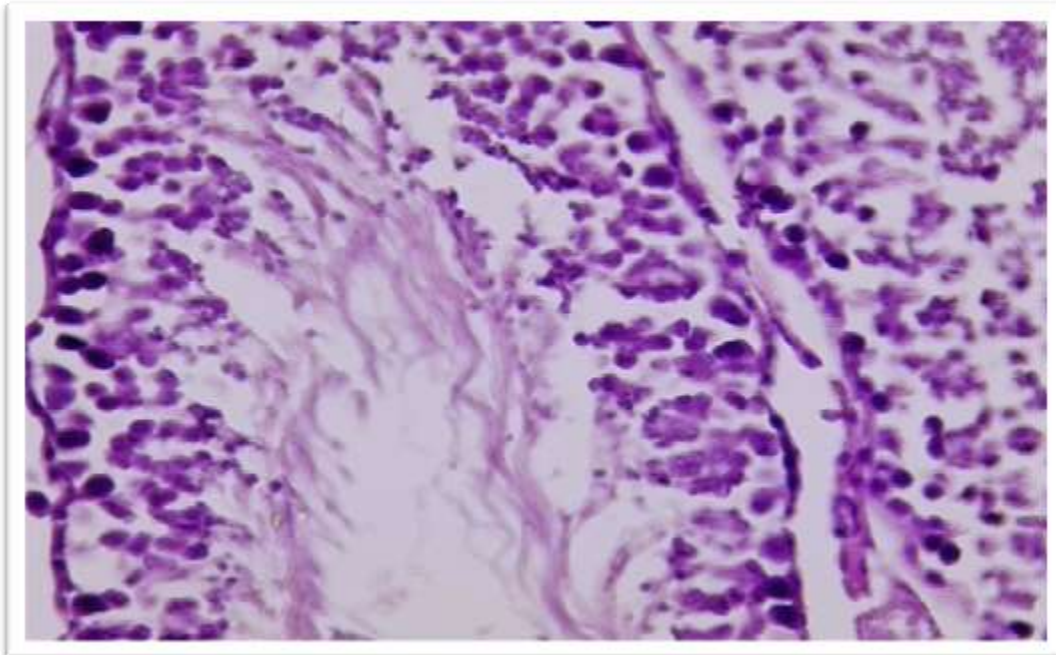


Figure (15) :Section of testis of rat group treated with 60 mg/kg of MSG for 8 weeks showing more immaturation of spermatogonia cells , no sperm presence ,more necrotic cells inside the lumen seminiferous tubules HXE(40x).

Male Sprague-Dawley rats received increasing doses of monosodium glutamate in a 40% aqueous solution every 48 hours for six weeks, according to a previous study using Sprague-Dawley rats to examine the effects of oral administration of various dosages of (MSG) on the morphology of the testes and cauda epididymal sperm

reserves of rats. According to the findings, the cauda epididymal sperm reserves of the rats receiving MSG were significantly lower than those of the control rats (Igwebuiké *et al.*, 2011).

When administered with MSG for 15 days in a short-term group (4 g/kg), and 30 days in a long-term group (4 g/kg), a study by Nayanatara *et al.*, (2008) revealed. The control group, which received the same amount of distilled water intraperitoneally, demonstrated lower sperm and testicular weight, which is consistent with the findings of the current study. MSG was administered orally to rats for 30 days at doses of 6, 17, and 60 mg/kg body weight by Hamza and AL-Harbi, (2014). They discovered that the histological changes in the testis were directly related to the MSG doses, and that MSG increased the production of lipid peroxidation in the testis. These findings suggest that MSG significantly increased testicular toxicity and decreased oxidative stress on testis tissues.

In accordance with the current study, Abd, (2017) administered 4 mg/g of MSG to mice for 7, 14, and 21 days. The results showed that the effect of (MSG) on the sperm abnormalities, was a significant decrease in the normal sperms of the mice compared to the control group. According to Kianifard's, (2016) study, testicles in male rats exposed to MSG at a level of 100,200mg/kg showed congestion of the blood vessels, increased thickness of the basement membrane of the seminiferous tubules, and a decrease in spermatocytes.

a study by Dong and Robbins, (2015). described histological changes, such as spermatogonia loss, interstitial loss or hyalination, leydig cell loss, atrophied seminiferous tubules, irregular seminiferous tubules, dilated blood vessels, loss of late spermatids, and decreased sperm morphology. In a prior study, male Swiss Albino mice were utilized, and the germinal epithelium and Leydig cells were impacted by subcutaneous administration of MSG at a concentration of 2 mg/g during the perinatal stage at the 2nd, 4th, 6th, 8th, and 10th days of life. In comparison to controls, there were considerably more primary spermatocytes in the pachytene stage and fewer spermatogenic cells in several of the tubules (Das and Ghosh, 2010). A recent study by Al alwani, (2014) showed when injection rats with MSG at dosed (30 and 60 mg/g) demonstrated alterations in testis tissue which included of hyaline material in the luminal of the seminiferous tubules, Many cells of the different types of spermatogenesis appeared necrotic with pyknotic nuclei.

The result of this study indicate that The testis are effected by two way ; Directly by the effect of monosodium glutamate by accumulation in testis tissue and caused damage to it. Indirect effect by the thyroid hormone, the decrease in the thyroid hormone by the effect of MSG, which caused decrease in metabolism in the body, then these decrease in thyroid hormone effect on testis, cause damage in the lydig cell which then cause decrease in testosterone concentration, so the number of sperm decrease because of the brimary function of testosterone is the production of sperm.

2.9.3 Sex hormone function

The statistical analysis of current study about the effects of MSG on testosterone function revealed in figure (16) :

* There was a high significant decrease ($p < 0.05$) in testosterone level at (30 and 60)mg/kg at 2 weeks (4.02+0.10, 1.96+0.11)ng/dl in comparison to control groups (4.78+0.08 ng/dl) .

Testosterone level exhibited high significant decrease ($p < 0.05$) at 4 weeks when treated with MSG with both doses (30 and 60)mg/kg (3.30+0.11,1.01+0.19) ng/dl compared with control groups (4.74+0.07 ng/dl) . A previous study by Bakke *et al.*, (1978) which disagree with present study , they were used the animals (rats, mice) exposure to MSG (dose varying from 2.2 to 4 mg / kg of body wt.) showed, there were reduction in weight of testes

Also there was high significant decrease in level of testosterone ($p < 0.05$)at 8weeks treated with (30 and 60)mg/kg of MSG (2.18 +0.10 , 0.10+ 0.01) ng/dl when compared to control groups (4.82+0.07 ng/dl) .

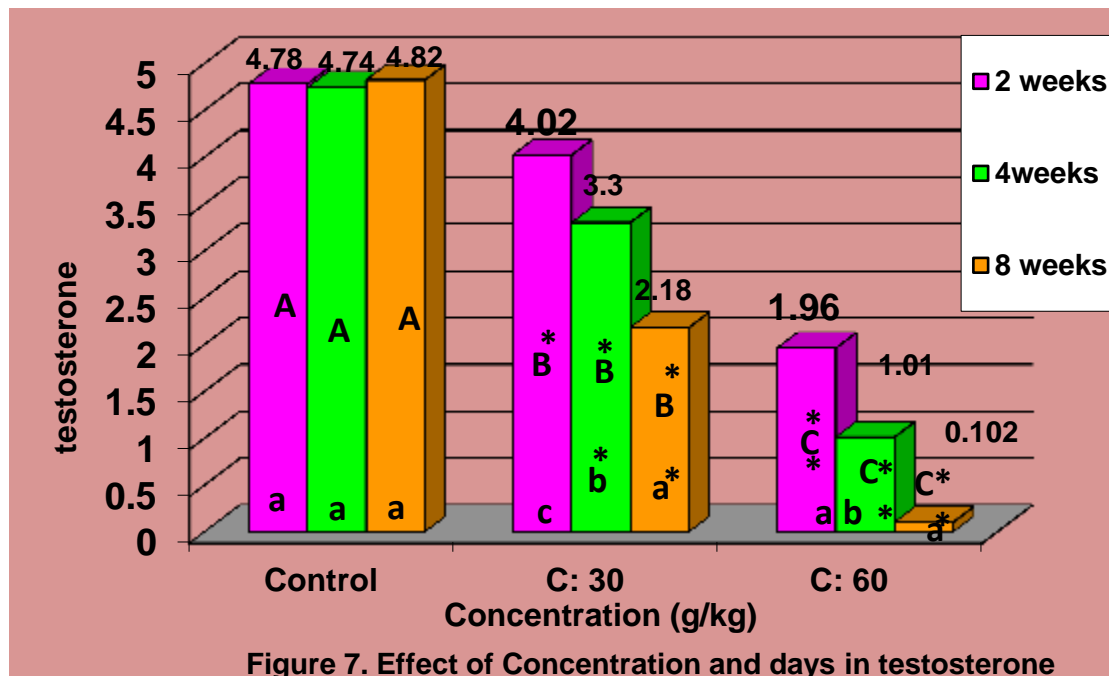


Figure 7. Effect of Concentration and days in testosterone

Fig. 16: Effect of different concentrations of MSG (30 ,60)gm/kg on testosterone levels of rats with different periods of time (2,4,8) weeks in comparison with control groups.

*high Significant decrease ($P \leq 0.05$).

(A,B,C) Represent the significant difference between groups with days as a fixed factor and concentrations as a variable factor. (a,b,c) represent the significant difference between groups with concentrations as a fixed factor and days as a variable factor

A study by Miskowiak *et al.*, (1993) showed that The double dose (4 mg/g) of MSG administered at the same time to newborn rats caused the decreased in the weight testes that disagree with this study.

a previous study by the were used animals, dosing from 0 to 4 g/kg, MSG administration duration of 10 – 56 days, and weight 75 – 200g. In MSG fed rats compared to controls:

showed the serum testosterone concentration was lower that agree with present study ,while showed decrease in testicular weights that disagree with present study .

A previous study by Bakke *et al .*, (1978) which dis- agree with present study , they were used the animals (rats, mice) exposure to MSG (dose varying from 2.2 to 4 mg / kg of body wt.) showed, there were reduction in weight of testes.

a previous study by the were used animals, dosing from 0 to 4 g/kg, MSG administration duration of 10 – 56 days, and weight 75 – 200g. In MSG fed rats compared to controls:

showed the serum testosterone concentration was lower that agree with present study ,while showed decrease in testicular weights that disagree with present study . our results deals with Al-Youssef and Al-Gayyar who showed that sodium nitrite resulted in significant reduction in serum testosterone concentration (Alyossef and Al-Gayyar, 2015). A studies focused on the role of thyroid hormone in regulating spermatogenesis in adult testis (Luaibi, 2017) .

The Result of this study indicate that the reduction in serum testosterone levels may result from disruption of the hypothalamic-pituitary-testes regulatory axis that controls testosterone production by testicular Leydig cells .

LH level

Statistical analysis about the effects of MSG on LH level exhibited in figure (17):

*High significant decrease ($p < 0.05$) in LH level at period 2 weeks treated with different doses (30 and 60)mg/kg (10.19+0.20 ,5.79+0.13) when compared with control groups (16.17+0.20)

* Level of LH revealed high significant decrease ($p < 0.05$) at 4 weeks when treated with MSG at doses (30 and 60) mg/kg (6.87+0.15, 4.37+0.29) compared with control groups (16.97+0.28) .

As well as there was a high significant decrease in LH level at period 8 weeks treated with different doses of MSG (30 and 60) mg/kg (5.07+0.14 , 2.80+0.25) in comparison to control groups (17.09+0.26) .

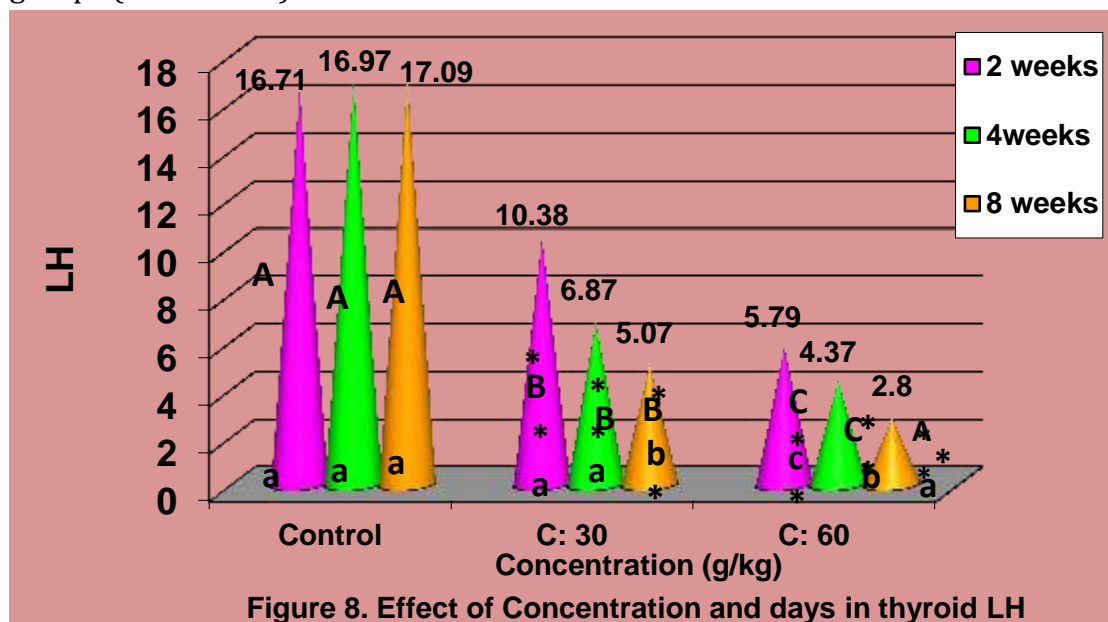


Fig. 17: Effect of different concentrations of MSG (30 ,60)gm/kg on LH levels of rats with different periods of time (2,4,8) weeks in comparison with control groups.

*high Significant decrease ($P \leq 0.05$).

(A,B,C) Represent the significant difference between groups with days as a fixed factor and concentrations as a variable factor. (a,b,c) represent the significant difference between groups with concentrations as a fixed factor and days as a variable factor

FSH level

The data shown in figure (18) demonstrated the effects of MSG on FSH level :

There was high significant decrease ($p < 0.05$) in level of FSH at period 2 weeks at treated with different doses of MSG (30 and 60)mg/kg (52.19+1.28 , 31.03 +0.26) compared with control groups (66.10 +1.13) . also the results showed high significant decrease at 4 weeks when treated with MSG (30 and 60) mg/kg (42.81+0.81 , 25.31+1.12) when related to control groups (66.46+ 0.93) .while at period 8 weeks showed high significant decrease ($p < 0.05$) (36.15+0.29 , 18.52+0.83) related to control groups (66.12+0.95) .

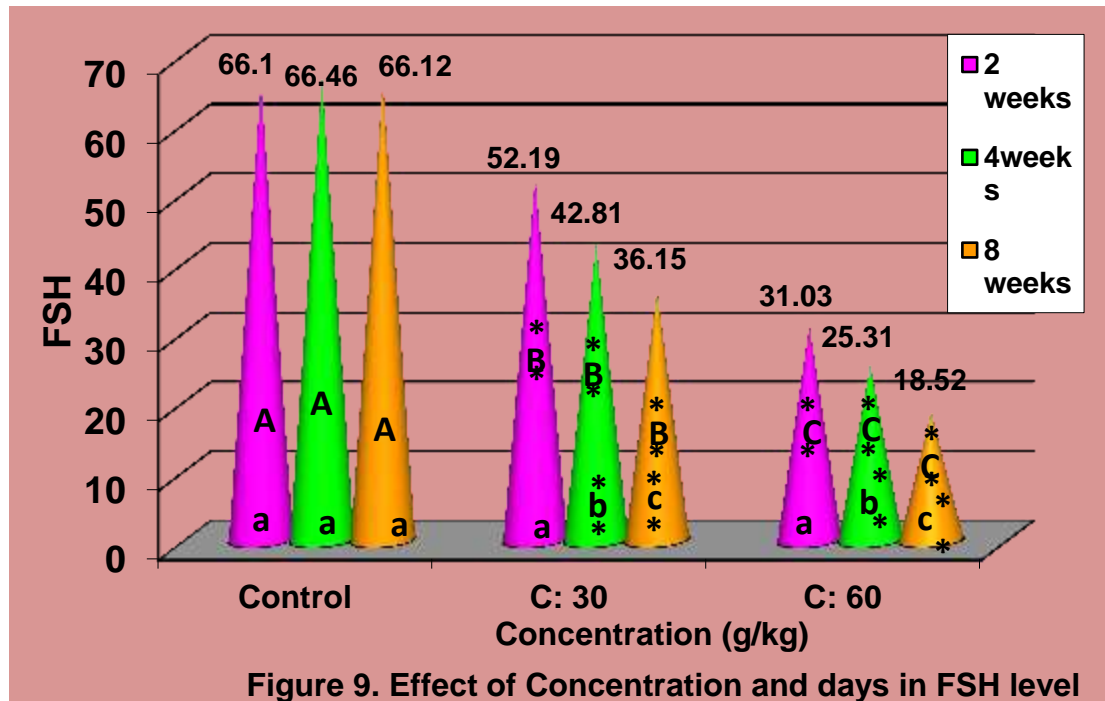


Fig. 18: Effect of different concentrations of MSG (30 ,60)gm/kg on FSH levels of rats with different periods of time (2,4,8) weeks in comparison with control groups.

*high Significant decrease ($P \leq 0.05$).

(A,B,C) Represent the significant difference between groups with days as a fixed factor and concentrations as a variable factor. (a,b,c) represent the significant difference between groups with concentrations as a fixed factor and days as a variable factor

Result

A previous study by Bakke *et al.* , (1978) which disagree with present study , they were used the animals (rats, mice) exposure to MSG (dose varying from 2.2 to 4 mg /

kg of body wt.) showed, there were reduction in weight of testes, FSH did not appear to be abnormal, LH may have been increased in the males.

a study by Miskowiak *et al.*, (1993) The double dose (4 mg/g) of MSG administered at the same time to newborn rats caused the decreased in the weight testes that disagree with this study and lowered testosterone level in 4 months which deal with present study but unchanged serum LH and FSH levels. The study by (Okoye *et al.*, 2016), is agree with present study, they were uses Sixteen male New Zealand mixed-breed of rabbits (*Oryctolagus species*), They were divided into four groups each of four rabbits. Group (A) control, received only distilled water though Groups B, C and D, the treated groups received 0.25 g/kg, 0.5 g/kg and 1 g/kg body weight of (MSG) from a 40% MSG stock solution, the Results showed that when compared to the control group (Group A) on Day 56 of (MSG) decrease in serum levels of both LH and testosterone were in Group D that received 1 g/kg body weight of (MSG). a previous study showed when administrated MSG for Eighty-four rats, randomly distributed in to 7 groups of 12 rats each, low doses (0.25, 0.50 or 1.00 g/kg body weight) of MSG were administered orally or subcutaneously at 48-h intervals for six weeks. Serum LH, testosterone showed that the mean serum of LH and testosterone levels were significantly lower than those of the control which agree with present study, Ochiogu *et al.*, (2015).

A Previous study by Igwebuike *et al.*, (2011), they were oral administration of varied doses of (MSG) using Sprague-Dawley rats, showed Increasing doses (1 mg/g, 2 mg/g, and 4 mg/g body mass) of a 40% aqueous solution of MSG were administered to the male Sprague-Dawley rats every 48 hours for 6 weeks, The results showed a significant reduction in serum testosterone of the rats that received (MSG) relation to the control rats which agree with present study.

A study by Ochiogu *et al.*, (2015) they were used thirty-two goats (28 males and four females) were. The 28 males were randomly divided in to seven of four goats each. were given MSG orally at doses of 0.25, 0.50 and 1 g/kg body weight respectively for 28 day the mean serum LH and, testosterone levels of the treated groups were significantly decrease than those of the control group.

the report by Redding *et al.*, (1971) that there were used Neonatal female and male rats of the Sprague-Dawley strain were injected subcutaneously with a daily dose of MSG (2.2 and 4.2 mg/g body wt.) beginning on the 2nd day of life. The rats were autopsied at 40 and 110 days of age, they was a noticeable decrease luteinizing hormone (LH) content of the anterior pituitaries of male and female rats at 40 days of age that treatment with monosodium glutamate, that agree with present study. The previous study reported deal with this study, that a High significant decrease of plasma levels of LH (mIU/ml) in MSG treated groups (Mohamed *et al.*, 2017). (Tafelski and Lamperti., 1977) was reported that The levels of FSH seen in the plasma treated with MSG was lower than in control groups that agree with present study.

luteinizing hormone, known as interstitial cell stimulating hormone (ICSH) is responsible for the stimulation of testosterone production by Leydig cells (McLachlan *et al.*, 1996). So the Decrease in pituitary content of this hormone have adverse

effects on testosterone synthesizing of the Leydig cells. This might be the reason for the decrease in serum testosterone levels in the rat treated with MSG in the present study.

Conclusion

The study included 54 male rats divided into three groups treated at different periods: 2 weeks, 1 month and 2 months. The results showed an increase in Thyroid and Testis weight and the result of the hormonal study showed the existence of a significant decrease ($P \leq 0.05$) in the mean levels of T₃, T₄, FSH, LH and Testosterone and an increase in TSH serum level of treated Rats groups compared with controls.

References

- Bojanić, V., Bojanić, Z., Najman, S., Savić, T., Jakovljević, V., Najman, S., & Jančić, S. (2009). Diltiazem prevention of toxic effects of monosodium glutamate on ovaries in rats. *Gen Physiol Biophys*, 28, 149-154.
- Das, R. S., & Ghosh, S. K. (2010). Long-term effects of monosodium glutamate on spermatogenesis following neonatal exposure in albino mice-A histological study. *Nepal Med Coll J*, 12(3), 149-153.
- Igwebuike, U. M., Ochiogu, I. S., Ihedinihu, B. C., Ikokide, J. E., & Idika, I. K. (2011). The effects of oral administration of monosodium glutamate (msg) on the testicular morphology and cauda epididymal sperm reserves of young and adult male rats. *Veterinarski Arhiv*, 81(4), 525-534.
- Khalaf, H. A., & Arafat, E. A. (2015). Effect of different doses of monosodium glutamate on the thyroid follicular cells of adult male albino rats: a histological study. *International journal of clinical and experimental pathology*, 8(12), 15498.
- Kianifard, D., Shoar, S. M. M., Karkan, M. F., & Aly, A. (2021). Effects of monosodium glutamate on testicular structural and functional alterations induced by quinine therapy in rat: An experimental study. *International Journal of Reproductive BioMedicine*, 19(2), 167.
- McLachlan, R. I., Wreford, N. G., O'donnell, L., De Kretser, D. M., & Robertson, D. M. (1996). The endocrine regulation of spermatogenesis: independent roles for testosterone and FSH. *Journal of endocrinology*, 148(1), 1-9.
- Nayanatara, A. K., Vinodini, N. A., Damodar, G., Ahemed, B., Ramaswamy, C. R., Shabarianth, M., & Ramesh, B. M. (2008). Role of ascorbic acid in monosodium glutamate mediated effect on testicular weight, sperm morphology and sperm count, in rat testis. *J Chin clin med*, 3(1), 1-5.
- Ochiogu, I. S., Ogwu, D., Uchendu, C. N., Okoye, C. N., Ihedioha, J. I., & Mbegbu, E. C. (2015). Serum luteinising hormone, testosterone and total cholesterol levels, libido and testicular histomorphology of male West African Dwarf goats orally or subcutaneously treated with monosodium L-glutamate. *Veterinarni Medicina*, 60(5).
- Redding, T. W., Schally, A. V., Arimura, A., & Wakabayashi, I. (1971). Effect of monosodium glutamate on some endocrine functions. *Neuroendocrinology*, 8(3-4), 245-255.

. Luaibi, N. M. (2017). Evaluation of Possible Toxic Effects of *Thymus vulgaris* leave Extract on Thyroid Function and Fertility in Male Rats. *Journal of Global Pharma Technology [Internet]*, (0).

Abd Allah, A. L. (2021). Prophylactic Effect of *Spirulina* Versus Monosodium Glutamate Induced Thyroid Disorders in Experimental Rats. *Egyptian Journal of Nutrition and Health*, 16(1), 45-59..

Abd, R. N. (2017). Effect of MSG as a food additive on organo-somatic indicator and sperms abnormalities in adult male mice. *Scientific Journal of Medical Research*, Vol. 1. No. 02.

Abdulazeez, M., Hussein, A. A., Hamdi, A. Q., & Mustafa, M. A. (2020). Estimate the Complications That Resulting from Delayed Management of Dental Trauma in Tikrit City. *Journal of Cardiovascular Disease Research*, 11(2), 80-82.

Alalwani, A. (2014). Monosodium glutamate induced testicular lesions in rats (histological study) Author links open overlay panel. *Middle East Fertility Society Journal*, Volume 19, Issue 4, Pages 274-280.

Ali, A., Jassim, A.F., Muhsin, S.N., & Mustafa, M.A. (2020). Study of Lycium Shawii Phenolic Compounds in Treatment of Hyperlipidemia. *Journal of cardiovascular disease research*, 11, 196-199.

Bakke, J. L., Lawrence, N., Bennett, J., Robinson, S., & Bowers, C. Y. (1978). Late endocrine effects of ad ministering monosodium glutamate to neonatal rats. *Neuroendocrinology*, 26(4), 220-228.

cil Foundation) Review of monosodium gluta-

Das, R. S., & Ghosh, S. K. (2010). Long-term effects of monosodium glutamate on spermatogenesis following neonatal exposure in albino mice-A histological study. *Nepal Med Coll J*, 12(3), 149-153.

Dhindsa, K. S., Omran, R. G., & Bhup, R. (1981). Histological changes in the thyroid gland induced by monosodium glutamate in mice. *Cells Tissues Organs*, 109(2), 97-102.

Dong, H. V., & Robbins, W. A. (2015). Ingestion of monosodium glutamate (MSG) in adult male rats reduces sperm count, testosterone, and disrupts testicular histology. *Nutrition Bytes*, 19(1).

Fadhil, K. B., Majeed, M. A. A., & Mustafa, M. A. (2019). Electronic study of fresh enzyme complexes of antifungal drugs-P450 and *Aspergillus kojic* acid biosynthesis. W: w saccharose flavus: fructose as a substratum. *Annals of Tropical Medicine and Health*, 22, 65-72.

FIC (the International Food Information Coun-

FIC (the International Food Information Council Foundation) Review of monosodium glutamate, examining the myths: 1994 .

Govindarajan, S., Mustafa, M. A., Kiyosov, S., Duong, N. D., Raju, M. N., & Gola, K. K. (2023). An optimization based feature extraction and machine learning techniques for named entity identification. *Optik*, 272, 170348.

Hama Hasan, T. A., Erzaiq, Z. S., Khalaf, T. M., & Mustafa, M. A. (2020). Effect of *Equisetum Arvense* Phenolic Extract in Treatment of *Entamoeba Histolytica* Infection. *Systematic Reviews in Pharmacy*, 11(11).

- Hama Hasan, T. A., Erzaiq, Z. S., Khalaf, T. M., & Mustafa, M. A. (2020). Effect of Equisetum Arvense Phenolic Extract in Treatment of Entamoeba Histolytica Infection. *Systematic Reviews in Pharmacy*, 11(11).
- Hamza, R. Z. and Al-Harbi, M. S. (2014). Monosodium glutamate induced testicular toxicity and the possible ameliorative role of vitamin E or selenium in male rats. *Toxicology reports*, 1, 1037-1045.
- Hassan, J. A., & Rasheed, M. K. (2022, November). Synthesis and characterization of some benzimidazole derivatives from 4-methyl ortho-phenylene diamine and evaluating their effectiveness against bacteria and fungi. In AIP Conference Proceedings (Vol. 2394, No. 1). AIP Publishing.
- Helal, E. G., Barayan, A. W., Abdelaziz, M. A., & El-Shenawe, N. S. (2019). Adverse effects of mono sodium glutamate, sodium benzoate and chlorophyllins on some physiological parameters in male albino rats. *The Egyptian Journal of Hospital Medicine*, 74(8), 1857-1864.
- Ibrahim, H. M., Jumaah, L. F., Khalaf, S. A., & Mustafa, M. A. (2021). KNOWLEDGE AND PRACTICE OF BREASTFEEDING AND WEANING IN MOTHERS LIVES SAMARRA CITY, IRAQ. *Biochemical & Cellular Archives*, 21.
- Karupusamy, S., Mustafa, M. A., Jos, B. M., Dahiya, P., Bhardwaj, R., Kanani, P., & Kumar, A. (2023). Torque control-based induction motor speed control using Anticipating Power Impulse Technique. *The International Journal of Advanced Manufacturing Technology*, 1-9.
- Loliger J (2000): Function and importance of glutamate for savory food. *Journal of Nutrition* 130, 915–920
- Löliger, J. (2000). Function and importance of glutamate for savory foods. *The Journal of nutrition*, 130(4), 915S-920S.
- mate, examining the myths: 1994
- Meister A (1979): Biochemistry of glutamate: glutamine and glutathione. In: Filer LJ, Garattini S, Kare MR, Reynolds WA, Wurtman RJ (eds.): *Glutamic Acid: Advances in Biochemistry*. Raven Press, New York. 69–84
- Meister, A. (1979). Biochemistry of glutamate: glutamine and glutathione. *Glutamic acid: Advances in biochemistry and physiology*, 69-84.
- Miskowiak, B., & Partyka, M. (1993). Effects of neonatal treatment with MSG (monosodium glutamate) on hypothalamo-pituitary-thyroid axis in adult male rats. *Histology and histopathology*.
- Mustafa, H. A., Majid, H. H., Abdulqader, A. T., Mustafa, M. A., & Salih, A. A. (2019). Study On Some Physiological, Biochemical And Hormonal Parameters Of Seminal Fluid Of Infertile Men. *Biochem. Cell. Arch*, 19(Supplement 1), 1943-1947.
- Nijris, O. N., Khaleel, Z. I., Hamady, S. Y., & Mustafa, M. A. (2020). The effectiveness of Aqueous Extract of Grape Seeds *Vitis vinifera* as an antibiotic for some microorganisms and its Protective Role Histology for Liver, Kidney in Mice. *Indian Journal of Forensic Medicine & Toxicology*, 14(2), 1838-1845.
- Nijris, O. N., Khaleel, Z. I., Hamady, S. Y., & Mustafa, M. A. (2020). The effectiveness of Aqueous Extract of Grape Seeds *Vitis vinifera* as an antibiotic for some

microorganisms and its Protective Role Histology for Liver, Kidney in Mice. Indian Journal of Forensic Medicine & Toxicology, 14(2), 1838-1845.

Ochiogu, I., Ogwu, D., Uchendu, C., Okoye, C., Ihedioha, J., & Mbegbu, E. (2015). Effects of monosodium-L-glutamate administration on serum levels of reproductive hormones and cholesterol, epididymal sperm reserves and testicular histomorphology of male albino rats. *Acta Veterinaria Hungarica*, 63(1), 125-139.

Okoye, C. N., Ochiogu, I. S., & Onah, C. E. (2016). The effects of monosodium L-glutamate administration on the reproduction and serum biochemistry of adult male rabbits. *Veterinarni Medicina*, 61(3).

Samuels, A. (1999). The toxicity/safety of processed free glutamic acid (MSG): a study in suppression of information. *Accountability in Research*, 6(4), 259-310.

Sudha, I., Mustafa, M. A., Suguna, R., Karupusamy, S., Ammisetty, V., Shavkatovich, S. N., ... & Kanani, P. (2023). Pulse jamming attack detection using swarm intelligence in wireless sensor networks. *Optik*, 272, 170251.

Tafelski, T. J. and Lamperti, A. A. (1977). The effects of a single injection of monosodium glutamate on the reproductive neuroendocrine axis of the female hamster. *Biology of reproduction*, 17(3), 404-411.

Thies, R.T. (2012). *Physiology: An Illustrated Review*, Thieme Medical Publishers, Inc. New York.

URBAN, R. J. (1999). Effects of testosterone and growth hormone on muscle function. *Journal of Labor a tory and Clinical Medicine* .

Wilson, L. (2002). Endocrine Physiology. Update in Anaesthesia Journal for Anaesthetists in Developing Countries, 14 .

Cite this article as: Noor Ali Zayed (2023).

Investigation the Effect of Monosodium Glutamate (MSG) on thyroid gland and sex hormone Levels in Male Rats, African Journal of Biological Sciences. 5(2), 97-121. doi: 10.48047/AFJBS.5.2.2023.97-121