



African Journal of Biological Sciences



Navigating Odontogenic Keratocyst in Paediatrics.

B. Saravana Kumar, Yesha Desai*, Praveen Kumar

B. Saravana Kumar: Professor, Department of Oral and Maxillofacial Surgery, Sree Balaji Dental College and Hospital, Bharath Institute of Higher Education and Research, Chennai.

Yesha Desai*, Post graduate, Department of Oral and Maxillofacial Surgery, Sree Balaji Dental College and Hospital, Bharath Institute of Higher Education and Research, Chennai.

Praveen Kumar, Post graduate, Department of Oral and Maxillofacial Surgery, Sree Balaji Dental College and Hospital, Bharath Institute of Higher Education and Research, Chennai.

Yesha Desai*:

Department of Oral and Maxillofacial Surgery, Sree Balaji Dental College and Hospital, Velachery Main Rd, Narayanapuram, Pallikaranai, Chennai, Tamil Nadu 600100

Mobile no: 8369976359

Emailid: desaiyesha436@gmail.com

Abstract:

Managing odontogenic keratocysts (OKCs) in children poses a challenge due to their rarity and potential recurrence. Often resembling other cystic lesions, such as radicular or dentigerous cysts, accurate diagnosis is essential. Typically, direct enucleation is performed, with biopsy confirming the OKC diagnosis. However, OKCs are known for their aggressiveness and high recurrence rates, warranting consideration of adjunctive treatments like chemical or electrochemical cauterization. Yet, caution is crucial to avoid damaging vital structures and tooth buds, complicating treatment decisions. Instead of immediate adjunctive therapy, regular follow-up is emphasized to monitor for recurrence. This case underscores the need for heightened awareness among dental professionals regarding OKC management in children. By promoting early detection and appropriate intervention, optimal outcomes can be achieved, ensuring the best possible care for pediatric patients with OKCs.

Key-words: Enucleation, Odontogenic keratocyst, Pediatric, Recurrence,

Article History

Volume 6, Issue 5, 2024

Received: 15 May 2024

Accepted: 22 May 2024

doi:10.33472/AFJBS.6.5.2024.7176-7184

Introduction: Odontogenic cysts are common lesions and constitute a significant portion of pathology service biopsies. This diverse group presents with varying manifestations, ranging from innocuous incidental findings to aggressive, destructive lesions with potential for malignant transformation. One such notorious entity is the odontogenic keratocyst (OKC) ¹.

An odontogenic keratocyst is a benign but locally aggressive cystic lesion that originates from the remnants of dental tissue. It most commonly occurs in the jawbones, particularly the mandible, and can cause expansion and destruction of surrounding bone if left untreated.

This case reports a 13-year-old boy with OKC. While OKCs can occur at any age, they are relatively rare in children under the age of 15 which amplifies the uniqueness of this case report². However, when they do occur in adolescents, they may exhibit more aggressive behaviour compared to those in adults. Thus, management of OKC in pediatric patients is paramount given their inherent propensity for aggressiveness and high rates of recurrence. Diligent assessment of therapeutic modalities and consistent monitoring are imperative to optimize clinical outcomes and mitigate the potential for disease relapse.

Case History: A 13-year-old patient reported with the chief complaint of spacing and proclined anteriors and wanted an orthodontic treatment for the same. Following the routine protocols, an OPG was taken along with lateral cephalogram. On radiographic examination of the OPG (Figure 1) an incidental finding of radiolucency was seen in respect to lower right first and partially erupted second molar. The radiolucency was unicystic with a well-defined sclerotic border in respect to lower right second molar.

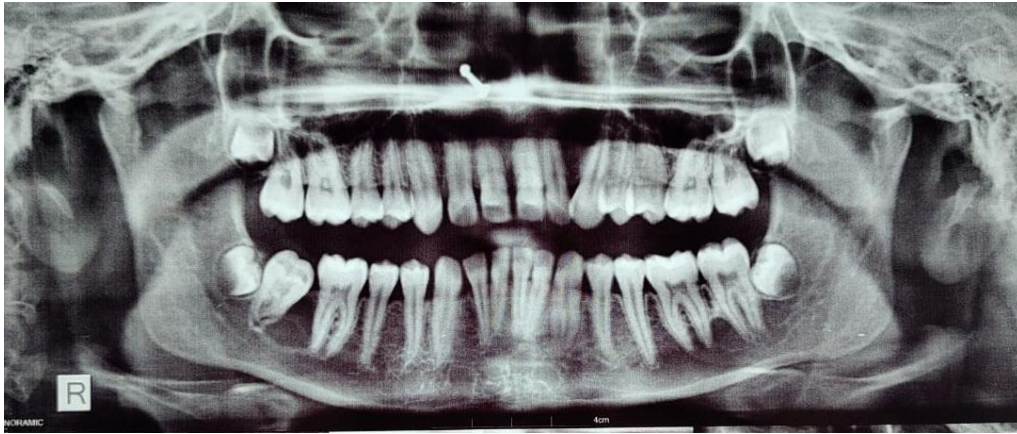

Figure 1

The patient was referred to the department of Oral and Maxillofacial Surgery. To get a better understanding and the extent of the lesion a CBCT was taken. CBCT (Figure 2) showed a well circumscribed, roughly ovoid shaped, unilocular, homogeneous radiolucent lesion greater than 1cm in diameter with a thin radiopaque corticated border associated with partially erupted tooth 47. In relation to partially erupted tooth 47, the radiolucent lesion expanded laterally from the crown, partially surrounding it. It was also found attached further apically to the root than at the cemento-enamel junction. The lingual cortical plate was extremely thinned out, showing expansion and was not intact at places in relation to 47 region (Figure 3).

Extension of the lesion (Figure 3)

- a. Inferiorly 8.1 mm from the lower border of the mandible
- b. Superiorly from the crest of the alveolar bone and the crest of the alveolar bone was not intact between 46,47 region.

c. mesiodistally the lesion was found to extend from the distal root of 46 till 47 regions. No evidence of root resorption was seen in relation to the teeth 46, 47. No evidence of displacement of the adjacent tooth 46. The developing tooth 48 was found to impinge the distal side of the root of 47. Radiographically the provisional diagnosis was odontogenic cyst in relation to the partially erupted tooth 47 suggestive of dentigerous cyst. And the provisional diagnosis included were odontogenic keratocyst and unicystic ameloblastoma.

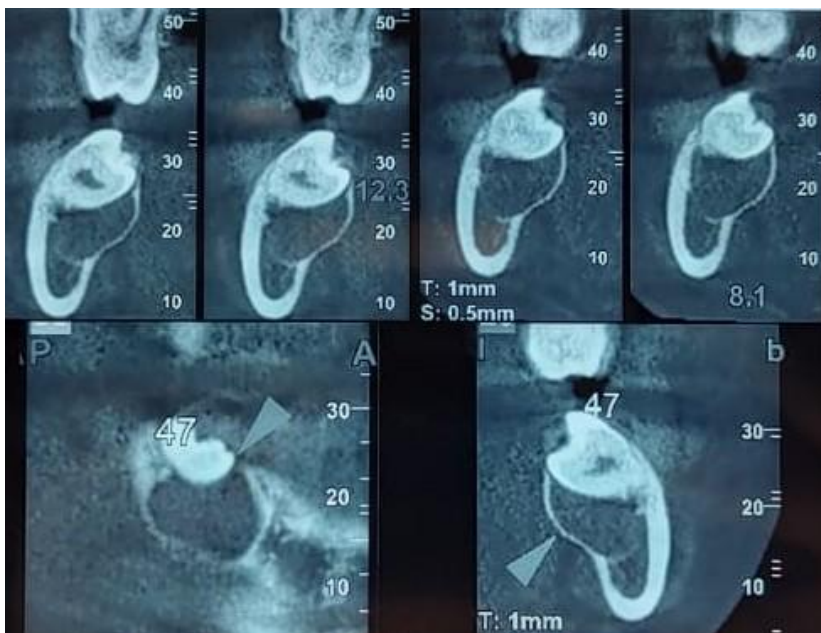


Figure 2

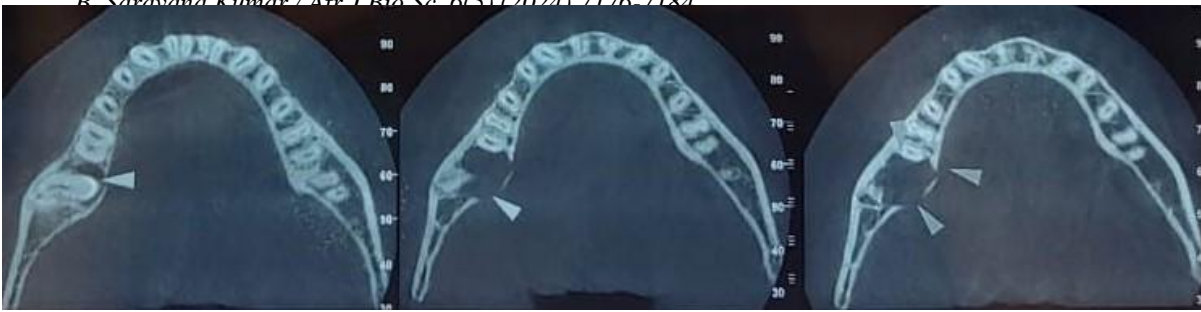


Figure 3

Treatment plan was formulated for enucleation of the lesion. Inferior alveolar nerve block and long buccal block was given using 2 percent lignocaine with 1:80000 adrenaline. A modified wards incision was placed which was extended till mesial papilla of the 46. Mucoperiosteal flap was reflected. Buccal bone guttering was done. 46 was elevated and the cyst lining was found attached to the distal surface of 46. Cyst was carefully curetted out with a scooping motion and 46 was extracted along with the cyst (Figure 4). This was followed by extraction of 47 and 48 (Figure 5). Metrogyl wash was given followed by saline wash and closure was done using 3-0 silk. A post op OPG was taken (Figure 6). Specimen was sent for biopsy and the report came back as odontogenic keratocyst.

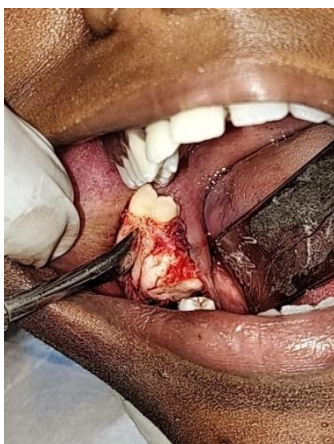

Figure 4

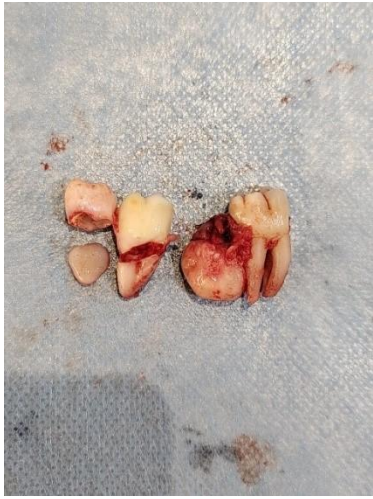

Figure 5

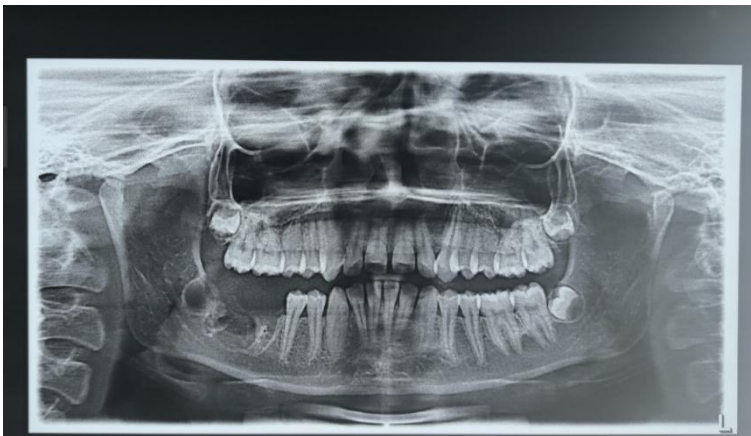

Figure 6

Discussion: The term odontogenic keratocyst (OKC) has a rich historical background, initially referred to as cholesteatoma by Hauer and Kostecka in the 1920s³ before Philipsen⁴ introduced the term OKC in 1956. Subsequent classifications by Philipsen, Pindborg, and Hansen broadened the definition to encompass any jaw cyst demonstrating keratin formation. Despite its distinct histological features, OKCs can present similar clinical and radiographic characteristics to other jaw cysts, leading to ongoing debates about their true nature. Furthermore, recent discussions have focused on the potential genetic contributions to OKCs, adding complexity to their understanding and highlighting the need for further research into their pathogenesis and management strategies⁵.

OKC have a male predilection of 1:1.14 and mostly commonly occurs in mandible which is concurrent with our patient⁶.

According to Rojas et al. the OKC appeared more frequently in third decade of like unlike our patient who was diagnosed with OKC due to incidental radiographic finding⁷.

According to Winters et al. the cyst is usually seen as unilocular or multilocular radiolucency as an incidental finding in the orthomopantomogram which is also seen in our case report⁸.

Vijay et al. emphasized the importance of preservation of vital structures in children like inferior alveolar nerve, tooth buds to help reduce post operative complications. Thus, enucleation followed by with or without application of carnoys solution was suggested as less invasive treatment modality. Thus, the same was followed in our patient as well to reduce complications. Regular follow-up is preferred over chemical or electrochemical cauterization for monitoring odontogenic keratocysts in children due to reduced risk of harming vital structures, avoidance of complications like tissue necrosis, infection, impaired wound healing.

The differential diagnosis in this case included dentigerous cyst, odontogenic keratocyst, and unicystic ameloblastoma, reflecting the overlapping clinical and radiographic features among these entities. While dentigerous cysts are more common and typically associated with impacted teeth, the possibility of odontogenic keratocyst and unicystic ameloblastoma necessitated careful consideration due to their potential for aggressive behaviour. In summary, choosing regular follow-up to monitor for recurrence provides a safer, non-invasive, and comprehensive approach to managing OKC in pediatric patients. By prioritizing patient safety, minimizing the risk of complications, and ensuring early detection of recurrence, clinicians can effectively manage this challenging condition while prioritizing the well-being of their pediatric patients.

References:

1. Nayak MT, Singh A, Singhvi A, Sharma R. Odontogenic keratocyst: What is in the name? *J Nat Sci Biol Med.* 2013 Jul;4(2):282-5.
2. Silva LP, Rolim LS, Silva LA, Pinto LP, Souza LB. The recurrence of odontogenic keratocysts in pediatric patients is associated with clinical findings of Gorlin-Goltz Syndrome. *Med Oral Patol Oral Cir Bucal.* 2020 Jan 1;25(1):e56-e60.
3. Hauer A. Ein CholesteatomimlinkenUnterkieferuntereinemretiniertenWeisheitszahn. *Zeitschrift fur Stomatologie.* 1926; 24: 40–59.
4. Philipsen HP, Reichart PA. Classification of odontogenic tumours. A historical review. *J Oral Pathol Med.* 2006; 35:525-9.
5. Badariramakrishna B, Archana Tangadu, Amit Byatnal, Aditi Amit Byatnal, Shrinivas C. Koppal. “Odontogenic Keratocyst: A Case Report with Review”. *Journal of Evidence based Medicine and Healthcare*; Volume 1, Issue 9, October 31, 2014; Page: 1192-1196.
6. Alaa Ayman Mohamed, Abdualhameed Abbas Babiker, Mazin Salah Khalfallah, Yousif Idris Eltohami, "Odontogenic Keratocysts: Presentation and Surgical Outcome in a Sample of Sudanese Patients", *International Journal of Dentistry*, vol. 2023, 6 pages, 2023.
7. L. V. Rojas, C. A. Claudio, C. J. V. Huamán, and G. V. Rojas, “Diagnóstico y tratamientoconservador del queratoquisteodontogénico,” *Odontoestomatologia*, vol. 24, no. 39, pp. 1–9, 2022.
8. R. Winters, M. Garip, J. Meeus, R. Coropciuc, and C. Politis, “Safety and efficacy of adjunctive therapy in the treatment of odontogenic keratocyst: a systematic review,” *British Journal of Oral and Maxillofacial Surgery*, vol. 61, no. 5, pp. 331–336, 2023.

9. Kumar V. Conservative surgical approach to aggressive benign odontogenic neoplasm: a report of three cases. *J. Korean Assoc. Oral Maxillofac. Surg.* 2015;41(1):37–42.