

<https://doi.org/10.48047/AFJBS.6.2.2024.2921-2937>



African Journal of Biological Sciences

Journal homepage: <http://www.afjbs.com>



Research Paper

Open Access

Principles of Management of Fractures of the Zygomaticomaxillary Complex

Amr Ahmed Magdy El-Sayed ¹, Mohamed Salah Awad ¹, Ahmed Mohamed Aly ¹, Fouad Mohamed Ghareeb ²

¹ Plastic and Reconstructive Surgery Department, Faculty of Medicine, Zagazig University

² Plastic and Reconstructive Surgery Department, Faculty of Medicine, Menoufiya University

Corresponding author: Amr Ahmed Magdy El-Sayed

Email: amrmagdy201021@gmail.com, amrmagdy@zu.edu.eg

Article History

Volume 6, Issue 2, Apr-Aug 2024

Received: 5 August 2024

Accepted: 15 August 2024

Published: 15 August 2024

[doi:10.48047/AFJBS.6.2.2024.2921-2937](https://doi.org/10.48047/AFJBS.6.2.2024.2921-2937)

Abstract: Background: The zygomaticomaxillary complex (ZMC) refers to the skeletal unit formed by the zygomatic bone and maxilla. These two bones are referred to as a complex, because of the structural and functional relationship between them; they articulate with each other over a wider area, and any traumatic impact on one bone generally influences the other. This duo complex also constitutes a major part of the orbit, spanning the infra-orbital rim, lateral wall, and floor. Hence the ZMC is also termed orbitozygomaticomaxillary complex. Because of its multiple articulations, various names are commonly used to describe ZMC fractures such as “tripod, tetrapod, or pentapod” fractures. Fractures of the ZMC commonly result in severe cosmetic and functional deficits because of the prominent anatomical position of the zygoma and its proximity to adjacent vital structures such as the globe. Precise reduction and fixation of these fractures is challenging due to their complex anatomic form, multiple articulations, and deformation in multiple planes. The scope of this chapter encompasses the bio dynamics of ZMC fractures, clinical implications, and guidelines for successful management. Surgical outcome of ZMC fractures is greatly influenced by two important factors: (1) choosing the right indications for intervention and (2) ideal time for surgery. Not all fractures of the ZMC require surgical intervention. The decision to intervene should be based on signs and symptoms and presence of functional impairment.

Keywords: Fractures, Zygomaticomaxillary Complex, Management

Introduction

The zygomaticomaxillary complex (ZMC) refers to the skeletal unit formed by the zygomatic bone and maxilla. These two bones are referred to as a complex, because of the structural and functional relationship between them; they articulate with each other over a wider area, and any traumatic impact on one bone generally influences the other. This duo complex also constitutes a major part of the orbit, spanning the infra-orbital rim, lateral wall, and floor **(1)**.

Hence the ZMC is also termed orbitozygomaticomaxillary complex. Because of its multiple articulations, various names are commonly used to describe ZMC fractures such as “tripod, tetrapod, or pentapod” fractures. The term zygoma denotes a “yoke or bar,” in Greek. Quite aptly, the zygoma extends as a prominent, sturdy bar across the face, contributing to its transverse width and anteroposterior projection. The clinical significance of this bony complex is attributed to its role in defining facial esthetics and globe function **(2)**.

The zygoma articulates with four bones; superiorly frontal, medially maxilla, laterally temporal bone, and posteriorly sphenoid, through five processes namely, the zygomaticotemporal (ZT), zygomaticomaxillary (ZM), infra-orbital (IOR), fronto-zygomatic (FZ), and sphenozygomatic (SZ) or zygomaticosphenoid (ZS). These processes are clinically significant in establishing the three-dimensional structural integrity of the upper lateral face **(1)**.

Fractures of the ZMC have been traditionally called the “tripod or trimalar fractures” because it involved separation at the three processes of the zygoma—the FZ, IOR, and the ZM processes. The terminology was later modified to “quadripod or quadramalar fracture” to include separation at the fourth point of articulation, the ZT process. However, the importance of SZ articulation along the lateral wall of the orbit has been recognized lately, and, hence, ZMC fracture is currently called a pentapod fracture to emphasize the necessity of restoring the five articulations during fracture management **(1)**.

Relations

Zygoma and orbit: ZMC forms the lateral and inferior part of the orbit, protecting as well as supporting the globe and associated soft tissues. The Whitnall’s tubercle present on the zygoma (inferior to the FZ suture) provides attachment to the suspensory ligament of Lockwood that maintains the horizontal axis of the globe **(3)**.

A fracture line located above the Whitnall’s tubercle leads to inferior displacement of zygoma as well as the lateral attachment of Lockwood ligament resulting in antimongoloid slant to the eye. Thus ZMC fractures greatly influence the structure and function of the orbit. Further, the contents of the orbit including the globe, extraocular muscles, and orbital fat are intimately related to the zygoma and may be affected in fractures of the ZMC or its surgical manipulation **(3)**.

Zygomatic Arch

The arch is the key parameter for re-establishing the sagittal projection as well as transverse width of the face. An arch which is bent outward or inward gets shortened. This leads to retrodisplacement of zygoma resulting in altered facial width. It is important to remember that in spite of being referred to as an arch; it does not have an exaggerated curvature. Therefore, overzealous contouring during reduction of zygomatic arch fractures can result in compromised esthetics. The arch is encased by a thick periosteal and fascial envelope which counteracts the displacing forces of the masseter. However, when the periosteal envelope is damaged due to high-velocity injuries, the fracture segments show more displacement **(4)**.

Imaging for ZMC Fractures

Radiological assessment is essential for accurate diagnosis and assessment of severity of the fracture.

- *Plain radiographs:* Conventional radiographs continue to remain the mainstay of imaging at some centers. Conventional radiographs may also be useful in the postoperative phase, to assess fracture reduction. However conventional radiographs are limited by superimposition of structures. The commonly used views include the waters view (37° occipitomental) which provides good visualization of the fractured zygoma and helps in comparing with the contralateral side. Tracing the McGrigor-Campbell lines or the Dolan’s lines are useful in identification of fractures on the Water’s view **(5)**.

Radiographic Appearance in ZMC Fracture

- Disruption of the Dolan’s lines
- Orbital line
- Zygomatic line
- Maxillary line
- Loss of elephant trunk appearance

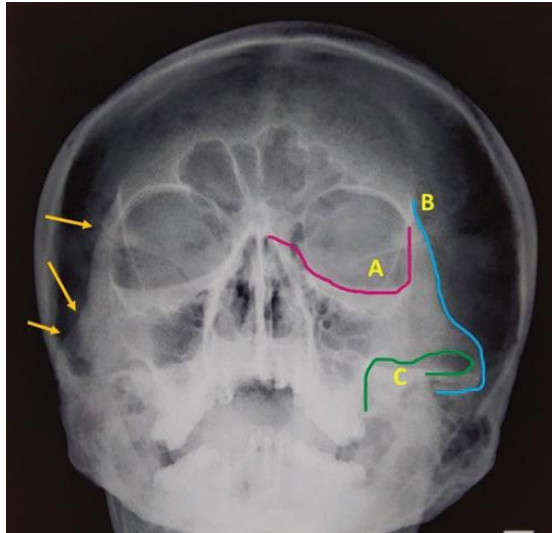


Fig. 1 Waters view with Dolan's lines. (A) Orbital line, (B) Zygomatic line and (C) Maxillary line. The yellow arrows indicate fracture separations noted on the right ZMC (5).

The submentovertex/jug handle view

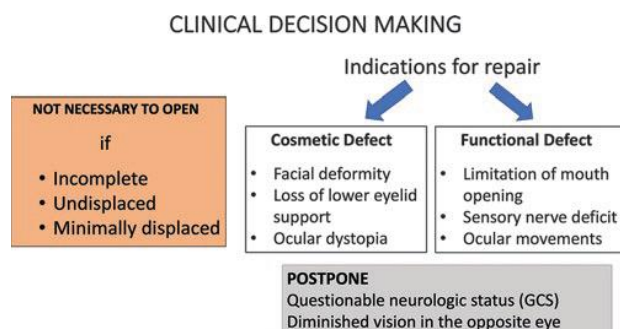


Fig. 2 Indications and contraindications for intervention

1. It is not necessary to intervene surgically if the fracture is incomplete, undisplaced, or minimally displaced with no compromise in esthetics or function. But such patients must be advised to follow soft, non-chewy diet for 2–6 weeks and monitored to identify displacement (6).

2. Indications for surgery include (1) presence of cosmetic defects in the form of facial deformity, loss of lower eyelid support, or ocular dystopia; (2) functional deficits such as limitation of mouth opening, sensory nerve deficit, and impaired ocular movements; and (3) ZMC fracture associated with oculocardiac reflex (OCR) in children.

3. Postponement of surgical intervention is considered when the general neurologic status of the patient is questionable.

4. Surgical intervention is relatively contraindicated when the involved side has the only seeing eye. In a patient willing for surgery, “potential loss of vision” has to be included in the informed consent (6).

Timing of Intervention

ZMC fractures are not emergencies, and treatment can be delayed, if necessary.

- When the decision is “no immediate intervention,” surgery may be postponed for up to 2 weeks, following which a reassessment may be made.

- When the indications are questionable, for example, presence of severe edema or fractures with minimal displacement, it is advisable to wait for the edema to subside so that the deformity may be assessed better (7).
- When the indications are definite, immediate intervention provides better outcomes due to minimal soft tissue scarring and easier reduction of fractures.

Surgical Objectives

Management of ZMC fractures is aimed at achieving the surgical objectives highlighted below:

- Restoration of facial esthetics
- Restoration of premorbid ocular function
- Correction or prevention of enophthalmos/ exophthalmos
- Restoration of premorbid antral function
- Restoration of mandibular range of motion

Mouth opening of 40 mm, excursion – 4–6 mm (7).

Need for Prophylactic Antibiotics

ZMC fractures may be categorized into three classes based on their propensity to develop postsurgical infection: clean fractures (isolated arch fractures), clean-contaminated (ZMC fractures compound into the antrum), and dirty (fracture which is open to exterior). While type three fractures require regular antibiotic prophylaxis, types 1 and 2 show minimal rates of infection and may either need “no” antibiotic prophylaxis or a modified single-day postsurgical regimen (7).

Preoperative Planning

ZMC fractures show high propensity for over or under reductions due to lack of objective intra-operative measures to assess reduction. This may be overcome with accurate pre-operative planning which helps in realizing surgical objectives in a predictable manner (8).

Preoperative planning includes three vital steps:

- CT evaluation
- Model surgery
- Soft tissue analysis

CT Evaluation

Proper CT evaluation is absolutely essential for choosing the ideal treatment; CT plays a very important role in differentiating en/exophthalmos due to ZMC fractures from those due to orbital fractures. This helps in arriving at a decision regarding internal orbit reconstruction (8).

Table 1. Relative vs. Absolute En/Exophthalmos (8).

	Enophthalmos in ZMC Relative	Enophthalmos in ZMC + orbit fracture Absolute
Etiology	Change in globe position due to displaced zygoma	Change in globe position due to fracture of orbital floor
Surgical management	Restoration of orbital rims by reduction and fixation of ZMC fracture alone	Restoration of orbital rims by reduction and fixation of ZMC fracture as well as reconstruction of orbital floor

Model Surgery

The process begins with obtaining CT scans of the patient with minimum slice thickness of 0.6 mm. This is followed by two different sequences of workflow which are described below.

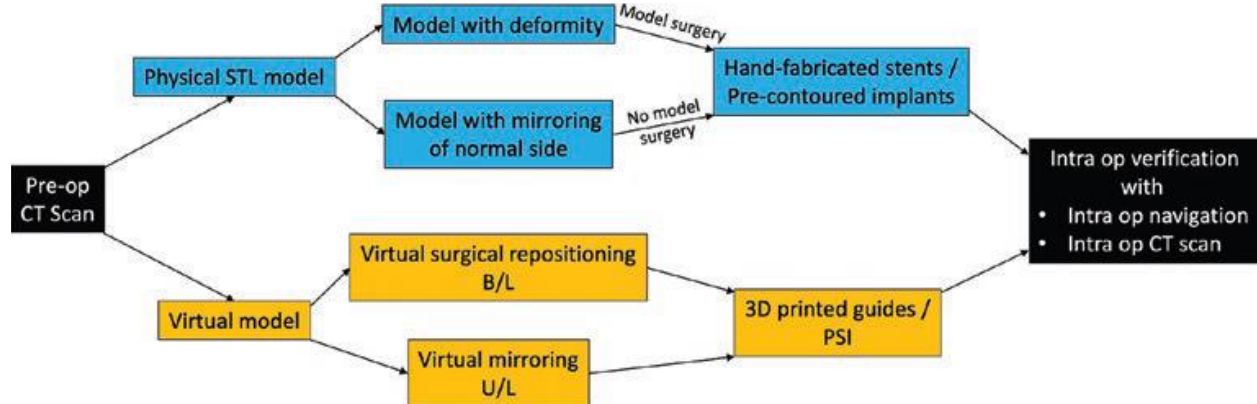


Fig. 3 Flow chart for preoperative planning in ZMC fractures (8).

(A) Planning Using Physical Models

The first step involves generation of a physical stereolithographic model (STL) from the CT scan of the patient. There are two methods by which this can be done.

1. **STL model with the actual deformity:** This model presents the post-traumatic deformity, as observed clinically. A routine model surgery is then performed, by which the displaced fragments are cut and repositioned to obtain optimal anatomical form.

The repositioned fragments are stabilized temporarily with wax. The fixation devices (miniplates) are then pre-contoured over the model. Such pre-contoured implants are used to guide intra-operative fracture reduction as well as fixation. (8).

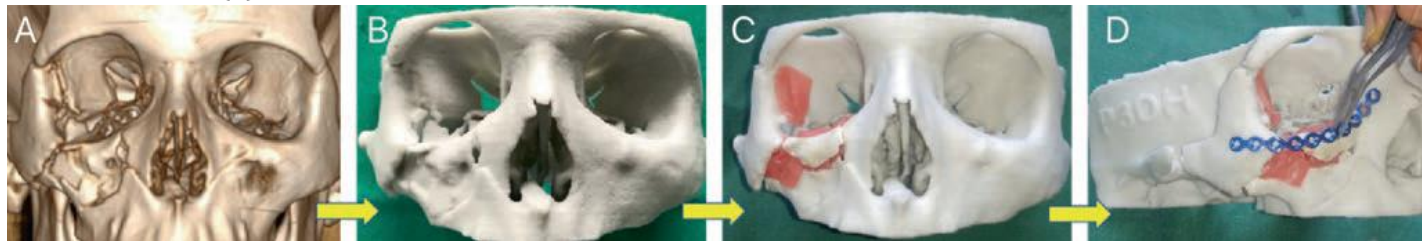


Fig. 4 Model surgery for pre-contouring of implants. (a) CT image demonstrating fractured ZMC of right side. (b) STL model demonstrating deformity. (c) Repositioning of fracture fragments to anatomical position. (d) Pre-contouring of implants (8).

2. **STL model after mirroring:** CT scan is used to generate a virtual model wherein the normal side is mirrored onto the fractured side. The virtual model is used to print a physical model which demonstrates the skull which is bilaterally symmetrical, mimicking ideal reduction status. Similar to the earlier method, implants for fixation are pre-contoured over this model to help achieve optimal results intra-operatively. (8).

(B) Planning Using Virtual Models

This method utilizes the complete spectrum of computer-assisted surgical planning. A CT scan is obtained to create a virtual model on which the entire surgical sequence of reduction is performed and on which the stents for intraoperative guidance are designed. Intra-operative stents are printed from these virtual designs. There is no physical “handheld” model here (9).

- In the case of a unilateral ZMC fracture, the normal side is mirrored to the fractured side to obtain bilateral symmetry. Computer Assisted Surgery (CAS) technology is then utilized to design “guidance stents” on the mirrored side. These stents can be utilized intra-operatively to (1) verify ideal reduction position in primary trauma or (2) design the osteotomy and repositioning, in secondary corrections. Another important

advancement in recent years is the design and printing of “patient specific implants” (PSI) using virtual planning (9).

Soft Tissue Analysis

Li et al. have described a technique for 3D simulation and prediction of soft tissue—outcome analysis in ZMC fractures. This process enables prediction of postoperative soft tissue changes in patients with ZMC fractures who are indicated for primary/secondary surgical interventions. The planning involves utilization of CT data and 3D stereophotography for the analysis. The technique may also be utilized for evaluation of postsurgical results (10)

Reduction of ZMC Fractures

Reduction of zygoma is unique in two aspects:

1. Unlike the other facial bones, “reduction alone” may be the sole treatment in many cases of ZMC fractures.
2. The surgical approach for reduction may be different from that for fixation. Fracture reduction may be done either by direct or indirect method, and the approaches may be extraoral or intraoral (1).

Direct vs. Indirect Method

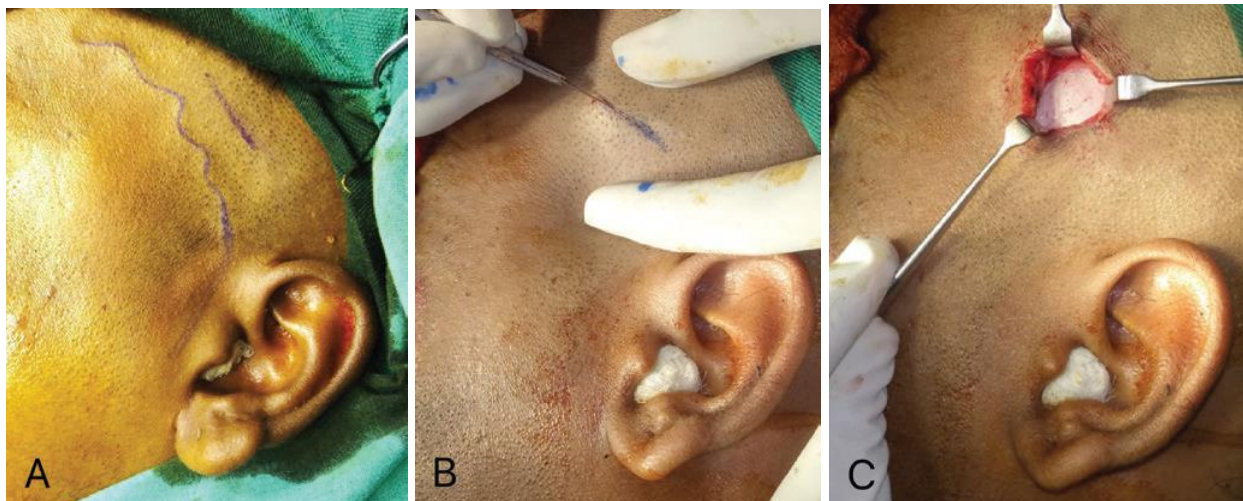
The indirect method is a blind technique where fracture is reduced without exposure of the fracture site (e.g., Gillies reduction), while direct method involves reduction of the fracture under direct visualization (e.g., coronal approach to reduce arch fracture). The differences between the two methods are shown in

However, indirect method is more commonly practiced. Open method is resorted to when the ZMC fracture is (1) severely displaced, (2) complex or comminuted, (3) when stable reduction is doubtful, and (4) there is a need for internal orbit reconstruction. However, no “single technique” is superior, and sometimes, a combination of techniques is more effective (1).

Extraoral Techniques

The extraoral reduction techniques may be either percutaneous, temporal, or endoscopic (1).

- **Temporal approach**, commonly called the Gillie’s is the most popular method of ZMC reduction. This approach is favored because the incision is placed within the hairline which does not leave a visible scar. It also offers a very predictable force during reduction and may be used for reduction of both the arch as well as the zygoma. The technique is based on the anatomical basis that the plane between the temporalis fascia and the temporalis muscle offers direct access to the zygomatic arch and zygoma. The only contraindication to this approach is the presence of concomitant temporal bone fracture. The incision is placed at a level 2 cm above the helix of the ear, paralleling the anterior branch of the superficial temporal artery, well within the hairline. Dissection is carried down through the skin, subcutaneous tissue, and galea aponeurotica (temporoparietal fascia—TPF) to reach the temporalis fascia (11).



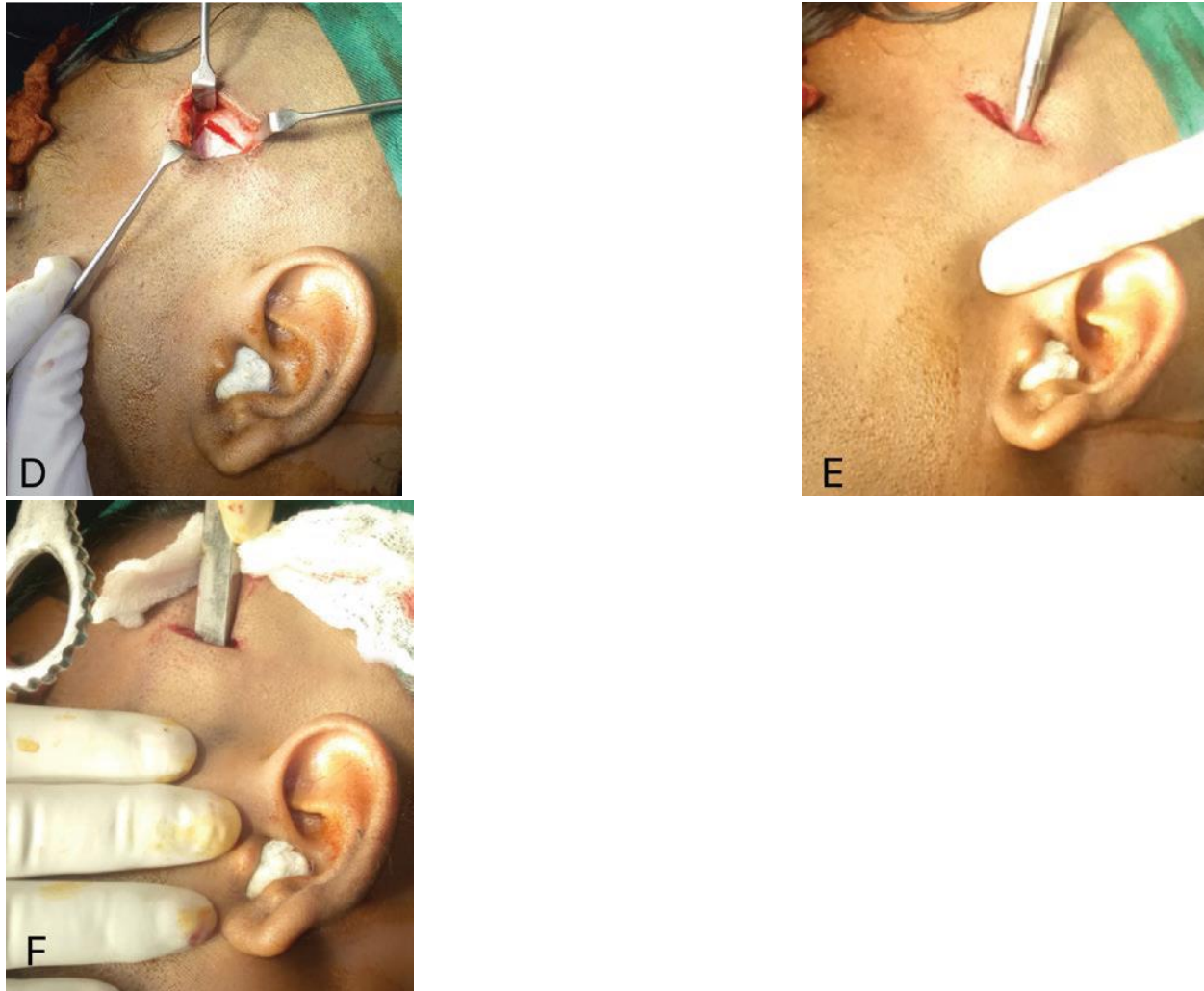


Fig. 5 Gillies temporal approach. (a) Marking of incision parallel to frontal branch of superficial temporal artery. (b) Placement of incision. (c) Exposure of deep temporal fascia. (d) Incision through deep temporal fascia exposing temporalis muscle. (e) Developing plane of elevation with periosteal elevator. (f) Placement of Rowe's zygomatic elevator for elevation (11).

An incision is made through the temporalis fascia to reveal the underlying temporalis muscle. A Howarth's elevator is inserted between the temporalis fascia and the muscle, to create a plane for the zygomatic elevator. Two types of zygomatic elevators, namely, the Bristow's and Rowe's are commonly used; the Bristow's has a single flat and elongated working tip attached to a handle and is used like a spatula for elevation, while the Rowe's elevator has an additional arm attached to the working tip which serves two purposes: (1) to provide the necessary countertraction during elevation so that it relieves the fulcrum off the temporal bone and (2) to evaluate the approximate depth of insertion of the working tip when inserted into the tissue. The zygomatic elevator is positioned in the plane created, directed inferiorly to reach the deeper surface of the zygoma and carefully elevated, while an ironing motion is used to smoothen the collapsed arch form. Care is taken not to lever the elevator against the skull (12).

Clinical Tip

1. It is good practice to keep a roll of gauze under the zygomatic elevator to prevent injury to the temporal bone.
2. Instead of extensive shaving of the temporal hair for a Gille's approach, a small patch (1cm by 3cm) of shaving/close trimming of hair can be done for better cosmesis.

- **Percutaneous methods** make use of a minimal facial skin incision, usually right over the zygoma or the lateral brow (Dingman's method) through which instruments may be inserted to manipulate and elevate the displaced zygoma **(13)**.

– *Poswillo's* approach. This involves a stab incision made at the point of intersection of two imaginary lines—a horizontal from the base of the nose and a vertical from lateral canthus. The incision is oriented along the skin crease, just enough for a Poswillo hook to be engaged underneath the body of the zygoma. And the impacted zygoma is pulled upward or outward. Skin incision is closed with a single suture. Reduction through a zygoma approach may also be performed by using a Carroll-Girard screw /universal bone reduction screw **(13)**.

– *Dingman's lateral brow approach* (1964) This technique is performed through a standard lateral brow approach where the fracture is visualized by a direct approach to the bone after incising through the skin, subcutaneous tissue, and periosteum. An elevator is then passed laterally and posterior to the orbital rim into the temporal fossa. The temporal aponeurosis (attachment of the deep temporal fascia to the lateral orbital rim) is incised, and the elevator is passed beneath it to lift the arch or the body of the zygoma in an upward, forward, and outward fashion. The original description by Dingman utilized trans-osseous wiring for stabilization of the front-zygomatic suture **(13)**.

However current methods incorporate the use of miniplate osteosynthesis through this approach.

Intraoral Techniques

The greatest advantage of intraoral techniques is “no skin incision.” Commonly followed methods are:

- *Balasubramaniam's/Keen's approach* (upper buccal sulcus approach)

This approach uses a vestibular incision behind the zygomatic buttress. A Howarth's periosteal elevator is inserted in a supraperiosteal plane to engage the infratemporal surface of the zygoma. Reduction is achieved with an upward, forward, and outwardly directed force. When greater force is needed to elevate as in impacted zygomas or delayed presentation, a Bristow's/Rowe's zygomatic elevator or the arm of an upper anterior forceps may be used. The technique offers more mechanical advantage than the extraoral method; less force is needed to elevate, because the force is directed entirely at the center of the zygomatic body, which is considered more effective **(14)**.

- *Quinn's procedure* (lateral coronoid approach) employs an incision over the anterior border of the ramus. An elevator is inserted in a supraperiosteal plane, lateral to the coronoid process and paralleling the temporalis tendon to reach the medial surface of the zygomatic arch. Elevation of the arch may be done in an ironing fashion.

Both the above-mentioned intraoral techniques are supraperiosteal methods **(11)**.

Reduction of Zygomatic Arch

Elevation of the depressed arch is usually performed in an indirect manner, using the Gillie's technique. However numerous techniques have been advocated in literature.

These include the “roller-coaster” lateral brow technique and methods using percutaneous towel clip, traction suture, Foley's catheter, K wire, and Dingman elevator to reconstitute the arch anatomy **(15)**.

Intra-operative Assessment of Reduction

The intra-operative assessment of reduction is a critical step in zygoma management, especially in closed reduction. The methods commonly used are (1) clinical assessment, (2) imaging, and (3) use of prefabricated guides/stents.

1. **Clinical assessment** is usually done by eyeballing, comparing with the normal side or palpation of the rims for steps. However, the adequacy of reduction may be difficult to assess intra-operatively because of edema as well as patient position. Audible click during manipulation is also indicative of reduction. Surgical exposure of multiple suture sites is the other method to confirm reduction but is less favored because of surgical morbidity **(15)**.

However, exposure at all sites of articulation is not required; two sites are considered perfect indicators of accurate reduction.

Indicators of Accurate Reduction of ZMC

Reduction along the vertical axis—SZ suture

Reduction along the horizontal axis—ZM suture

2. **Intra-operative imaging** such as C-arm, CT, O arm, or endoscopes are valuable guides in confirming reduction of ZMC fractures. However, use of intra-op imaging other than endoscopes mandates use of lead aprons by operating room personnel to prevent radiation exposure **(16)**.

3. **Prefabricated guides/ stents** are valid tools which ensure accuracy of reduction, intra-operatively.

Precautions During and After Reduction

Manipulation of zygoma during reduction has been known to cause certain complications such as bleeding from infra-orbital vessels. Use of controlled force during indirect reduction greatly reduces such complications. It is prudent to watch out for stimulation of Oculocardiac reflex (OCR). OCR may also be prevented by administering regional blocks before elevation **(4)**. Once the reduction is completed and found satisfactory, the fracture fragments need to be maintained in the reduced state. A Zimmer splint (preformed aluminum splint with foam on the undersurface) may be adapted to the reduced arch and secured with sutures. It is maintained in situ for 2–3 weeks.

Finally, it is mandatory to do a force duction test (FDT) after elevation of zygoma **(4)**.

FDT Is Mandatory After Reduction of ZMC Fractures

During reduction of ZMC fractures, as the fractured bones get realigned to normal anatomical position, entrapment of surrounding soft tissue or muscles may occur between the fragments.

This may lead to post-surgical diplopia, necessitating a surgical revisit.

Fixation and Stabilization of ZMC Fractures

Need for Fixation

Fixation needs of ZMC fractures depend on the post-reduction stability. Classification of fracture patterns by Rowe and Williams provides guidance on assessment of fracture stability after reduction. Any fracture classified as stable after reduction does not require fixation, while those considered unstable, mandate fixation. However, a practical method would be to apply moderate digital pressure on the malar eminence after reduction. Displacement secondary to this maneuver requires fixation. The algorithm proposed by Rodrigo and Belini et al. is also a practical guide to manage ZMC fractures which are not associated with orbital component. For ZMC fractures with orbital involvement, Ellis and Perez advocate guidelines for orbital reconstruction based on CT evaluation **(17)**.

Most of the studies indicate increase of fixation points from 1 to 2, 3, and 4 points based on the status of intraoperative stability after reduction. Involvement of orbit leading to changes in intra-orbital volume requires orbital reconstruction **(17)**.

Fixation Principles

The current dictum is “any zygoma which when fractured and displaced must be fixed”. The objectives are to achieve a 3D reconstruction (transverse width, vertical height, and anteroposterior projection) and establish the buttresses.

Attention needs to be given to the order of restoration. The results of various biomechanical experiments indicate that the vertical buttress needs to be fixed first, to restore the facial height. Then, the anteroposterior projection may be achieved by restoring the arch **(18)**.

Ideal Sequence of Fixation

1. Vertical buttress—to restore facial height
2. Zygomatic arch—to restore anteroposterior projection

Surgical Access to Fixation

Surgical approaches for ZMC fixation are chosen based on the fracture pattern and fixation needs. A single or multiple incision may be used for the surgical exposure of ZMC fractures (18).

The incisions may be broadly classified as:

- Cutaneous (upper eyelid, lateral brow, subciliary, subtarsal, infra-orbital, preauricular, and coronal incisions)
- Conjunctival (transconjunctival with canthotomy/ transcaruncular)
- Mucosal (intraoral vestibular).

The list of incisions and the exposure achieved

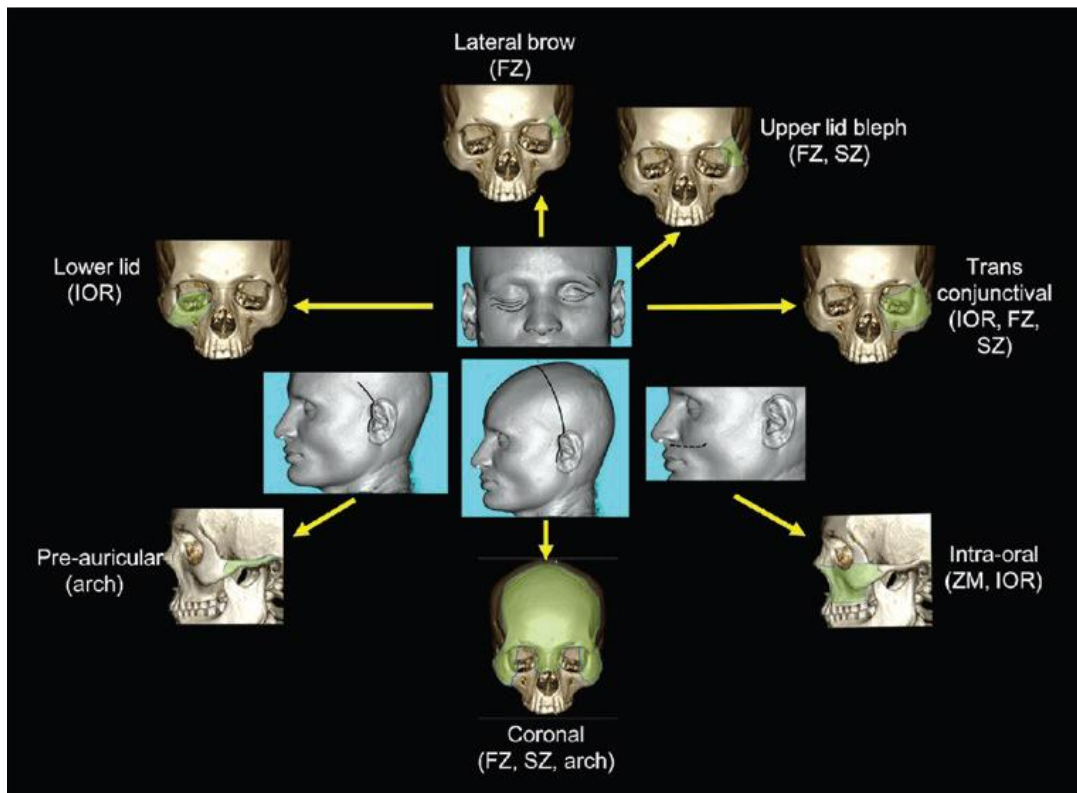


Fig. 6 Incisions to access ZMC fractures (18).

The following is a description of the various incisions used to access the fixation points in ZMC fractures. It is important to take adequate measures for globe protection while placing any periorbital incisions. The commonly followed methods include either a temporary tarsorrhaphy or a corneal shield. The tarsorrhaphy also offers the additional advantage of being used as a retraction suture during surgery (19).

Supraorbital/Lateral Brow Incision

The lateral brow incision is otherwise called as “in the brow” incision and offers a fast and direct access to the fronto-zygomatic suture and lateral part of the supraorbital rim. The extensions for the incision must be well within the eyebrow which provides an ideal camouflage. However, this incision may not be ideal in people who are cosmetically inclined to maintain a higher eyebrow. Absence of any important neurovascular structures in this area makes this incision easy to perform, even by beginners (7).

After infiltration of LA solution containing vasoconstrictor, a 2 cm long incision is placed along the curve of the superolateral part of the orbital rim. Care is taken to incline the blade parallel to the hair so that the shafts are not transected.

Failure to do so may cause linear alopecia along the incision line, which may be unaesthetic. Incision is carried through the skin, subcutaneous tissue, and the orbicularis oculi muscle. The flap is undermined in the supraperiosteal plane to permit ease of retraction. A periosteal incision is then placed above the fronto-zygomatic suture for reduction and fixation (7).

When additional exposure is needed on the medial aspect, the incision is extended up to the supraorbital nerve. For additional inferior extension, a gradual 90° turn into the crow's feet wrinkle which is restricted to the skin only, is utilized to provide a much wider access.

This extension must remain 6 mm superior to the lateral canthus. Inferior limit of the incision along the lateral orbital rim should not cross the RSTL (resting skin tension lines) to avoid unaesthetic scars.

Closure is performed in layers with approximation of the periosteum and subcutaneous tissues (8).

Upper Eyelid Blepharoplasty Incision

The upper lid blepharoplasty incision is otherwise called as the *supratarsal fold* or *upper eyelid crease* incision. It offers the most esthetically favorable approach to the fronto-zygomatic suture region. The incision is made along the eyelid crease, 10 mm above the free margin of the eyelid. As the incision extends laterally, it should be at least 6 mm above the lateral canthus. When eyelid anatomy is distorted with edema or hematoma, the contralateral lid crease measurements are used to mark the incision (8).

The incision is placed through the skin and muscle and is raised as a skin-muscle flap for good viability of the overlying skin. The plane of dissection is below the orbicularis oculi in a superior and lateral fashion to reach the periosteum. The periosteum is sharply incised to expose the bone underneath. Further dissection along the bony margins is strictly subperiosteal; any violation of the periosteum may cause herniation of the lacrimal gland which is present in the superolateral concavity of the orbit. Closure of the incision is done in layers, starting with periosteum, followed by the orbicularis oculi, and the skin (8).

Subciliary Incision (20).

The subciliary incision is a commonly used transcutaneous approach which offers good exposure of the infra-orbital rim along with the entire orbital floor. This may be a very useful approach in the management of ZMC fractures which involve the orbital floor also.

The skin incision is placed along the entire length of the lower eyelid, 2 mm below the level of the eye lashes to conceal the future scar. The incision must not be extended more than 2 cm lateral to the lateral canthal ligament. This prevents any inadvertent damage to the temporal branch of the facial nerve which is present about 3 cm lateral to the lateral canthal ligament.

Once the skin is incised, the dissection may proceed in three different ways :

(i) **"Skin-alone" flap technique** where the plane of dissection is along the *subcutaneous plane between the skin of the eyelid and the orbicularis oculi*. On reaching the facial surface of the infra-orbital rim, the orbicularis muscle along with the periosteum is incised to reach the rim. The periosteal incision is generally placed at least 3–4 mm below the level of the infra-orbital rim.

(ii) **"Skin-muscle" technique:** the incision is carried down from the skin into the pre-tarsal fibers of the orbicularis oculi, and the flap is dissected along the *plane deep to the muscle but superficial to the tarsal plate*. The dissection is then carried out superficial to the orbital septum till the rim is reached. Exposure of the rim is performed after sharp dissection of the periosteum just below the level of the rim

(iii) **"Step" approach** is performed in two different levels and is considered the best approach as it prevents most of the complications which are associated with the two former approaches. The incision is first placed through the skin, and the plane of dissection is carried in the *subcutaneous plane, maintaining the pre-tarsal fibers of the orbicularis oculi*. As the lower end of the tarsal plate is reached, the orbicularis oculi muscle is divided, and the plane is changed to include the muscle along with the skin as a "skin-muscle" flap.

The development of a skin-alone flap at the marginal level and a “skin-muscle” flap at the subtarsal level creates a **step** in the plane of dissection. The dissection then proceeds caudally toward the infra-orbital rim in a submuscular plane superficial to the orbital septum. On reaching the rim, the periosteum is incised sharply about 3–4 mm below the level of the rim on the facial aspect **(20)**.

The incision of the periosteum at this level not only helps preserve the attachment of the orbital septum along the rim margin but also lies above the level of the infra-orbital foramen which is seen about 7–8 mm below the level of the rim. Dissection of the periosteum can be performed along the entire length of the infra-orbital rim, anterior maxilla, and the zygoma to provide excellent exposure.

Advantages of the stepped approach include (1) minimal chances of buttonholing or darkening of the skin due to vascular compromise (2) lesser incidence of ectropion and entropion (3) reduced scarring at the eyelid margins due to preservation of the pre-tarsal orbicularis oculi fibers **(20)**.

The differences between the three variants of subciliary incision are highlighted in.

Extended Lateral Exposure with the Subciliary Approach.

After placing a standard subciliary incision, supraperiosteal dissection is performed along the lateral orbital rim in the cephalic direction till the FZ suture or a few millimeters beyond. This releases the skin flap and makes it amenable to easy retraction to reach the FZ region. The periosteum is then divided in the center of the lateral orbital rim along its length. In most cases the lateral canthal ligament may be stripped in a subperiosteal fashion to facilitate comfortable access to the FZ suture. This approach may be used to avoid an additional incision for exposure of the FZ suture **(21)**.

Subtarsal Approach

Subtarsal or **mid-lid incision** was also described by Converse. The incision is marked 5–7 mm below the inferior lid margin corresponding to the lower border of the tarsal plate, along the subtarsal crease. The lateral extension of the incision may be extended up to 2 cm beyond the lateral canthal ligament similar to the subciliary incision, along one of the resting skin tension lines. The incision is made through the skin and subcutaneous tissue. The *pre-septal fibers of the orbicularis oculi are also divided at the same level*, and the plane of dissection is maintained superficial to the orbital septum **(21)**.

The dissection is carried out caudally to reach the infraorbital rim, and the periosteum is divided below the level of the rim on the anterior surface of the maxilla and zygoma.

The subtarsal approach is favored more than the subciliary due to its easier technique and lesser incidence of complications **(22)**.

An important consideration following lower eyelid approaches is the application of the “frost suture” (temporary lower eyelid suspension suture), to prevent postoperative ectropion. Frost suture also permits visualization of the globe in the postoperative phase, when required **(22)**.

Nevertheless, lower rim incisions are often associated with postoperative ectropion and scleral show. While scleral show/lid traction refers to abnormal exposure of sclera (1 mm or more) with contact between bulbar conjunctiva and the lid, ectropion refers to eyelid eversion with no contact between bulbar conjunctiva and lid. Ectropion requires correction for cosmetic reasons as well as functional problems arising from keratinization of exposed conjunctiva **(23)**.

Treatment varies from conservative modalities to surgical procedures.

Measures to Correct Ectropion and Scleral Show

- *Conservative measures* Corneal protection measures; artificial tears, ointment, temporary tarsorrhaphy
- *Surgical procedures* Release of cicatrization, sutures, skin/mucosal grafts, cartilage grafts, rotation flaps

Infra-orbital Incision

This is performed as an incision which simultaneously divides the skin, orbicularis muscle, and periosteum, along infra-orbital rim. Though the infra-orbital incision offers the most direct approach to the infra-orbital rim and orbital floor, it is seldom preferred in contemporary surgery due to the unsightly postoperative scar and prolonged edema of the lower lid region due to disruption of lymphatic drainage **(23)**.

Transconjunctival Incision

Transconjunctival incision has gained popularity because it completely negates the unesthetic scarring associated with skin incisions. This incision offers good access to the infra-orbital rim and SZ regions with either a pre-septal or retroseptal approach. The modified transconjunctival incision with a cutaneous Y extension when combine with lateral canthotomy offers excellent exposure to the IOR, SZ, as well as the FZ region. The complications of transconjunctival incisions include entropion, in-curling of lashes (trichiasis), or growth of the eyelashes in two layers (distichiasis). Malposed lateral canthus has also been observed following improper repositioning of the lateral canthus after canthotomy **(24)**.

Vestibular Incision

The vestibular incision is the most frequently used approach to access the ZM buttress. The popularity is due to its application for reduction of ZMC fracture as well as fixation at the ZM buttress. It is used the vestibular approach to also fix the zygomatic arch fractures which override at the zygomaticotemporal suture, with transbuccal instrumentation (transoral arch fixation technique) **(24)**.

Preauricular incision is useful for open reduction and fixation of arch fractures. After the routine skin incision, adopting the deep subfascial approach provides better protection to the facial nerve as compared to the other commonly used approaches, namely, the subfascial and suprafascial procedures. demonstrates the use of preauricular incision with deep subfascial dissection to expose a malunited zygomatic arch fracture **(24)**.

Coronal Incision

Tessier introduced the use of coronal incision to access the superior and lateral orbits bilaterally along with naso-orbito-ethmoid complex in congenital facial reconstruction. The approach can be extended with a preauricular incision to include the exposure of the zygomatic body and the arches bilaterally. This incision also facilitates the temporal approach to the SZ suture. Disadvantages of the approach include the extensive length of incision, dissection, temporal hollowing, scar alopecia, risk of injury to the supraorbital nerve, and temporal branch of the facial nerve **(23)**.

Fixation Methods

Fixation methods for ZMC fractures have evolved through the ages.

Three basic fixation methods are available for ZMC fractures;

1. Temporary support
2. Indirect fixation and
3. Direct fixation **(1)**.

The trend has gradually shifted from nonrigid fixation methods such as trans-osseous wiring, external pin fixation, and K wires to functionally rigid fixation methods including miniplates and compressive screws. However, some of the nonrigid fixation modalities are still applicable in certain clinical situations. A brief description of all fixation methods is provided below along with their indications and limitations **(1)**.

- **Trans-osseous wiring** using stainless steel wires is rarely used in current practice due to its nonrigid mode of fixation that compromises post-reduction stability. The advantages include minimal periosteal stripping and lesser hardware as compared to use of miniplates and screws.

- **Antral packing** with gauze or balloon/Foley's catheter is used in special scenarios where the ZMC is comminuted. But it is an inaccurate technique with high relapse potential and increased possibility of infection. The oral layer is closed, once the desired level of packing is achieved. The other end which is free is pulled out through the nostril and taped to the cheek. This is later used to retrieve the pack once the healing phase is complete.

–The *inflatable balloon* is positioned within the sinus cavity in a similar manner and verified through the vestibular approach. The balloon is then inflated with about 20cc of saline till adequate support is obtained for the reduced fragments. The vestibular approach is then closed meticulously without damaging the balloon. The balloon is left in situ for the fracture to heal. Removal is accomplished by deflating the balloon and pulling it out through the antrostomy port **(1)**.

- **Kirchner or K wires and Steinmann pins** are still popular in some units as they serve as tools of reduction as well as fixation. But these techniques are associated with cutaneous scars and poor patient compliance due to the transcutaneous presence of pins:

- (A) **Trans-zygomatic (25)**.
- (B) **Naso-zygomatic**
- (C) **Zygomatico-palatal**
- (D) **Fronto-zygomatic fixation**
- (E) **Cranio-zygomatic fixation**

- **Lag screws** have been found to be an effective alternative at the FZ region because of the additional stability offered by interfragmentary compression. But this technique requires adequate bone stock for fixation.

- **Micro screws:** Micro screws are 2 mm screws which are used to fix sagittal zygomatic fractures by using the lag screw technique. These screws also reduce hardware **(21)**.

- **Miniplates:** The principal method of fixation is miniplate osteosynthesis. Miniplates are chosen based on rigidity requirements, anatomical site involved, presence of bone deficits, and biological considerations pertaining to protection of adjacent vital structures **(21)**.

Shape of plates: The plates are chosen according to the contour of the bone that needs to be fixed; L plate for the ZM suture and a curved plate for the IOR.

Presence of bone loss: Comminuted fractures or bone loss may result in sagging of overlying soft tissues, especially in the ZM buttress region. This may be negated by using a broad mesh that bridges defects.

Biological considerations: Care must be taken to protect the roots, infra-orbital nerve and eye during fixation. In regions where the skin is thin, low-profile plates are preferred, 2 mm system for the ZM buttresses and 1.5 mm at the FZ, IOR, arch, and SZ suture **(21)**.

Stability requirements: For ideal stability, screws of 6 mm length with a minimum of two screws on either side of fracture are essential. The only exception being the SZ suture where one screw on either side of the fracture line is adequate.

- **Fixation points:** The number of fixation points is directly proportional to the requirements of stability. Five different possibilities exist:

–One-point fixation refers to fixation at either the FZ or ZM suture. This has been found to be adequate in resisting post-reduction instability in simple tripod fractures while reducing hardware and surgical exposure **(26)**.

Comparative studies have shown that one-point fixation at the ZM buttress has been found to be more advantageous due to many reasons: (1) absence of external scarring; (2) ease of surgical access; (3) unlike the FZ region, adequate soft tissue cover is present; and there are no issues of plate palpability; (4) easier to remove the plate, when needed; and most importantly (5) ZM buttress is a better indicator of zygoma alignment than the FZ region due to the wider area of articulation **(26)**.

However, FZ may be used in fractures with comminuted ZM buttress **(26)**.

–Two-point fixation indicates fixation at ZM and FZ/ IOR

-Three-point fixation/tripoding includes fixation at the FZ, IOR, and the ZM. A recent meta-analysis indicates that three-point fixation is the most effective in ensuring absolute clinical stability against displacing forces after reduction

-Four-point fixation/tetrapoding involves fixation at the FZ, IOR, arch, and the ZM. This may be indicated in panfacial fractures requiring fixation of the arch to restore the anteroposterior projection of the face.

-Five-point fixation/pentapoding is used to manage severely comminuted or dislocated ZMC fractures wherein the SZ suture is also fixed, in addition to the other four sites of fixation. The SZ fixation may be performed either through a temporal or an intra-orbital approach.

-ZMC fractures requiring orbital reconstruction: irrespective of the type of fixation, when ZMC fracture is associated with orbit, the orbital rims are fixed first (26).

This is important because it is safer and easier to gauge the depth of orbital dissection from the restored infra-orbital rim and also to facilitate floor reconstruction. Also, the size of the orbital defect is better assessed when the rims are aligned.

• Bio-resorbable plates

Though titanium miniplates are more commonly used to fix ZMC fractures, substantial clinical success has been obtained with use of bio-resorbable plates. They offer comparable post-reduction stability along with the added advantages of preventing thermal sensitivity and avoiding the need for second surgery to remove plates. Limitations associated with bio-resorbable plates are its technique sensitivity and increased operating time (27).

Fixation of Zygomatic Arch

The ORIF of arch fracture is indicated when the fragments are unstable after closed reduction and in cases where re-establishment of sagittal projection of face is needed (27).

Fixation may be performed by one of the three methods, based on the fracture pattern: (1) a miniplate for an arch demonstrating a single fracture line, (2) a spanning adaptation plate when the arch is multi-fragmented, and (3) a micro screw for an outfractured root or sagittal fracture of the arch. Kim et al. proposed plating on the superior surface of the upper border as an alternate line of arch fixation which negated the drawbacks associated with the conventional fixation (28).

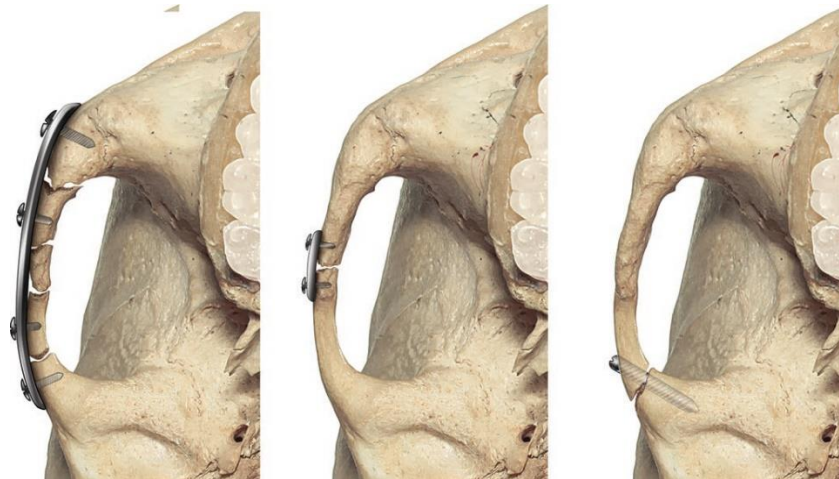

Fig. 7 Different fixation options for zygomatic arch fractures. (a) Adaptation plate. (b) Miniplate. (c) Compressive screw (28).

Soft Tissue Resuspension

Accurate reduction and fixation of ZMC fractures frequently necessitates the use of multiple incisions on the midface which deglove the entire periosteum-muscle-fat complex of the midface and zygoma. Failure to re-approximate the dissected tissues may lead to undesirable changes in the soft tissue projection and form.

The various changes that may be a sequel to wide subperiosteal dissection of the midface include (1) cheek ptosis, (2) descent of the lower eyelid skin and infraorbital hollowness, (3) loss of malar prominence due to inferior displacement of the malar fat pad, and (4) exaggeration of the nasolabial fold **(28)**.

Over the years many authors have documented these undesirable changes and proposed soft tissue resuspension methods to minimize them. This can be achieved by various methods (1) re-approximating the incised periosteum using absorbable sutures, (2) by suspending the periosteum using heavy absorbable or nonabsorbable sutures to a drill hole placed in a superiorly positioned bony landmark such as the orbital rim, (3) resuspension of lateral facial and temporal soft tissues to the deep temporal fascia in the temporal region and (4) prophylactic endoscopic midface lift **(28)**.

Postoperative Care

Following reduction of ZMC fractures, with or without fixation, the following measures are taken to maintain postsurgical stability and prevent soft tissue complications:

- Soft diet: Patients managed with conservative methods are advised soft diet for a period of 2 weeks.
- Protection of surgical site: The reduced zygoma or the arch must be protected with a tape labelled “do not touch” to provide cognitive input to the patient and people around.
- Frost suture: This temporary suspension suture is maintained for 3–5 days in any patient undergoing an inferior eyelid approach for the prevention of ectropion.
- Post-op sinus regimen: A sinus regimen including prophylactic antibiotics for sinus coverage and decongestants is advocated by some authors.
- Periodic assessment of vision: Periodic ophthalmic examination for the first 2 postoperative weeks is mandatory, in an awake patient. In an unconscious patient, it is achieved by swinging flashlight test or VEP (visual evoked potential).
- Anti-edema measures: Head end elevation must be maintained to prevent facial edema.
- Anti-empysema measures, such as avoiding nose blowing.
- Protection of eye with ophthalmic ointments.
- Physiotherapy to prevent postoperative trismus:

Postoperative trismus is a common phenomenon following ORIF of ZMC fractures due to hematoma, reflex muscle spasms, and fibrosis. Measures such as physiotherapy, forced mouth opening using gag, and kinesio logic tapes may be used to improve mouth opening.

- Eye movement exercises are encouraged to facilitate resolution of edema and expedite restitution of movements **(6)**.

References

1. Panneerselvam E, Ravi P, and Sasikala B. (2021): Fractures of the Zygomaticomaxillary Complex. *Oral and Maxillofacial Surgery for the Clinician*; 1151- 99.
2. Prabhu SS, Chung SA, Rudolph MA, Hemal K, Brown PJ and Runyan CM. (2021): Automated 3D Analysis of Zygomaticomaxillary Fracture Rotation and Displacement. *Plastic and Reconstructive Surgery Global Open*, 9(10).
3. Akramovna RN. (2023): Peculiarities in treatment of the trauma of the zygomatico-orbital complex. *Confrencea*, 4(04), 475- 81.
4. Yusupov S, Boymuradov S, Bobamuratova D, Shukhratova M, Marupov I, Akramova DT and Muradova DA, (2022): diagnostic aspects of zygomatico-orbital complex fractures with the use of modern digital technologies. In *Proceedings of the 6th International Conference on Future Networks & Distributed Systems*; 399-403.
5. Gadkari N, Bawane S, Chopra R, Bhate K and Kulkarni D. (2019): Comparative evaluation of 2-point vs 3-point fixation in the treatment of zygomaticomaxillary complex fractures—a systematic review. *Journal of Cranio-Maxillofacial Surgery*, 47(10), 1542-1550.
6. Shokri T, Sokoya M, Cohn JE, Bahrami A, Inman J and Ducic Y. (2020): Single-Point Fixation for Noncomminuted Zygomaticomaxillary Complex Fractures—A 20-Year Experience. *Journal of Oral and Maxillofacial Surgery*, 78(5), 778- 81.
7. Arun S, Nayak SS, Chithra A and Roy S. (2023): Outcomes of Non-surgical Management of Zygomaticomaxillary Complex Fractures. *Journal of Maxillofacial and Oral Surgery*, 1-7.
8. Zhang X, Han CY, Dai MJ, Chen JL, Zheng XH, Long J, Tang W, Tian WD, Liu L. (2018): Application of computer-assisted surgery techniques in the management of zygomatic complex fractures. *Chin JTraumatol*; 21(5): 281–6.

9. Widodo DW, Dewi DJ, Ranakusuma RW and Irawati Y. (2021): Evaluation of 3 and 2-point internal fixation in the management of zygomaticomaxillary complex fractures: Case report. *Annals of Medicine and Surgery*, 67, 1025- 39.
10. Li P, Zhou ZW, Ren JY, Zhang Y, Tian WD and Tang W. (2016): Accuracy of three-dimensional facial soft tissue simulation in posttraumatic zygoma reconstruction. *Int J Oral Maxillofac Surg*; 45(12): 1665–70.
11. Cuddy K, Dierks EJ, Cheng A, Patel A, Amundson M and Bell RB. (2021): Management of zygomaticomaxillary complex fractures utilizing intraoperative 3-dimensional imaging: The ZYGOMAS Protocol. *Journal of Oral and Maxillofacial Surgery*, 79(1), 177-182.
12. Wang HD and Dillon J. (2021): Contemporary management of zygomaticomaxillary complex fractures. In *Seminars in Plastic Surgery*; 35(4), 256-62). 333 Seventh Avenue, 18th Floor, New York, NY 10001, USA: Thieme Medical Publishers, Inc.
13. van Hout WMMT, de Kort WWB, Ten Harkel TC, Van Cann EM and Rosenberg AJWP. (2022): Zygomaticomaxillary complex fracture repair with intraoperative CBCT imaging. A prospective cohort study. *Journal of Cranio-Maxillofacial Surgery*, 50(1), 54-60.
14. Peretti N and MacLeod S (2017): Zygomaticomaxillary complex fractures: diagnosis and treatment. *Current opinion in otolaryngology & head and neck surgery*; 25(4), 314-19.
15. Goli R, Rao V, Crozier J and Woo AS, (2022): refining operative indications for zygomaticomaxillary complex fracture repair. *Plastic and Reconstructive Surgery–Global Open*, 10(4S), 86- 7.
16. Menon A, Karikal A and Shetty V. (2018): Does C-arm guidance improve reduction of zygomatic arch fractures? A randomized controlled trial. *J Oral Maxillofac Surg*. 2018;76(11):2376–86.
17. Marinho RO and Freire-Maia B (2013): Management of fractures of the zygomaticomaxillary complex. *Oral Maxillofac Surg Clin North Am*; 25: 617–36.
18. Cornelius C, Gellrich N, Hillerup S, Kusumoto K, Schubert W, (2019): Midface - indication - zygoma, zygomatic complex fracture—AO Surgery Reference [Internet]. [www2.aofoundation.org](https://www2.aofoundation.org/wps/portal/surgery?bone=CMF&segment=Midface&classification=92Zygoma,%20Zygomatic%20complex%20fracture&showPage=indication). 2019[cited 18 June 2019]. Available from: <https://www2.aofoundation.org/wps/portal/surgery?bone=CMF&segment=Midface&classification=92Zygoma,%20Zygomatic%20complex%20fracture&showPage=indication>
19. Yamsani B, Gaddipati R, Vura N, Ramiseti S and Yamsani, R. (2016): Zygomaticomaxillary complex fractures: a review of 101 cases. *Journal of maxillofacial and oral surgery*, 15, 417- 24.
20. Mittal G, Garg R, Sharma S, Rathi VC, Ranjan R and Khare G. (2019): Efficacy of two-point fixation in the management of zygomatic complex fractures—A prospective clinical study. *National Journal of Maxillofacial Surgery*, 10(2), 223.
21. Jazayeri HE, Khavanin N, Jason WY, Lopez J, Shamliyan T, Peacock ZS and Dorafshar AH. (2019): Fixation points in the treatment of traumatic zygomaticomaxillary complex fractures: a systematic review and meta-analysis. *Journal of Oral and Maxillofacial Surgery*, 77(10), 2064- 73.
22. Arjmand H, Billig A, Clement A, Hopfgartner A, Whyne CM and Fialkov JA. (2023): Is three-point fixation needed to mechanically stabilize zygomaticomaxillary complex fractures? *Journal of Plastic, Reconstructive & Aesthetic Surgery*, 84, 47-53.
23. Al-Moraissi EA, Elsharkawy AT, Al-Tairi NH, Farhan AH, Abotaleb BM, Al-Sharaee YA, Olufunmilayo OF and Alzubaidi A. (2018): What surgical approach has the lowest risk of the lower lid complications in the treatment of orbital floor and periorbital fractures? A frequentist network meta-analysis. *J Craniomaxillofac Surg*; 46: 2164–75.
24. Sharma R, Singh S and Patrikar S. (2018): Retroseptal transconjunctival approach for fractures of the zygomaticomaxillary complex: a retrospective study. *Br J Oral Maxillofac Surg*; 56(1): 29–33.
25. Chu SG, Lee JS, Lee JW, Yang JD, Chung HY, Cho BC, Choi KY. (2019): Comparisons among four types of absorbable plates used for internal fixation of zygomaticomaxillary complex fractures. *J Craniomaxillofac Surg*; 47(3): 383–8.
26. Luck JD, Lopez J, Faateh M, Macmillan A, Yang R, Davidson EH, Nam AJ, Grant MP, Tufaro AP, Redett RJ, Manson PN and Dorafshar AH. (2018): Pediatric zygomaticomaxillary complex fracture repair: location and number of fixation sites in growing children. *Plast Reconstr Surg*; 142: 51–60.
27. Ribeiro AL, de Souza Rodrigues TM, de Melo A-JS and Pinheiro JD. (2015): Interfragmentary screw fixation of the zygomatic arch in complex midface and zygomaticomaxillary fractures. *J Oral Maxillofac Surg*; 73(3): 494–8.
28. Kim H, Yoon J and Lee BI. (2019): Radiological morphometric analysis of the zygomatic arch: Application of osteosynthesis on the upper arch border for rigid fixation. *J Plast Reconstr Aesthet Surg*; 72(5): 831–41.