



African Journal of Biological Sciences



Research Paper

Open Access

Orthodontic Treatment with Maximum Efficiency Self-Ligating System

Stefanus Siswoyo, Maria Purbiati

Orthodontic Specialist Dentist Education Program, Faculty of Dentistry, University of Indonesia

Corresponding author (*): Maria Purbiati

Email: maria.purbiati@ui.ac.id

Article Info

Volume 6, Issue 8, April 2024

Received: 12 Feb 2024

Accepted: 23 March 2024

Published: 08 April 2024

Abstract

This case report aims to describe a young female patient with a class I skeletal pattern with crowding and deep over bite who was treated using a passive self-ligating bracket without extraction. This study focuses on the management of a case that begins with the determination of the patient and is accompanied by the establishment of a diagnosis based on various supporting data. After that, a treatment plan was formulated and then implemented to obtain treatment results and then comprehensively discussed based on existing theories. After 15 months of treatment, the patient's main complaint has been corrected, namely, there is no crowding in the lower anterior region and the teeth are well arranged. There were also improvements in overjet, overbite, molar and canine relationships. These results were supported by the balanced position of the incisors, normal interincisal angles, competent lips, and the ability to achieve a good anterior seal at the end of treatment. Long-term retention is recommended to improve the prognosis and stability of the treatment outcome.

Key words: High blood pressure, Prevalence, Quinshul Community

© 2024 Maria Purbiati, this is an open access article under the CC BY license (<https://creativecommons.org/licenses/by/4.0/>), which permits unrestricted use, distribution, and reproduction in any medium, provided you give appropriate credit to the original author(s) and the source, provide a link to the Creative Commons license, and indicate if changes were made

Introduction

Fixed orthodontic appliances have evolved from non-straight wire appliance to straight wire appliance and from conventional to self-ligating. Treatment with self-ligating brackets in certain cases can provide relatively shorter and more efficient treatment times.¹ More efficient is defined as the state of successfully obtaining good treatment results with an increase in assessed factors such as less control frequency, shorter control duration, more comfort, technically easier practical procedures, reduced need for extraction, and reduced discomfort. Self-ligating brackets are also known to provide lower friction with the ability of full arch wire engagement, lighter force use, faster mechanics with the ability to reduce protrusion of the maxillary and mandibular incisors and a significant increase in the transverse dimension of the dental arch while providing a lip bumper effect that is useful in treating malocclusion cases from aligning and leveling to finishing.² A meta-analysis showed the efficacy of self-ligating systems in reducing mandibular incisor protrusion by 1.5⁰ than conventional allowing faster finishing.³ Understanding the orthodontic appliance used and the combination of diagnosis and treatment plan with proper mechanics along with patient compliance will make treatment more efficient and effective.⁴

Malocclusion is a condition that deviates from normal occlusion or a condition that deviates from the normal relationship of one tooth to another. Clinical features of malocclusion include crowding, deep bite, crossbite, protrusiveness and many more. The most common clinical features are crowding and deep bite.⁵ Crowding or crowded teeth are defined as a difference in the relationship between the size of the teeth and the size of the jaw, causing the position of the teeth to overlap. Crowded teeth can be on the lingual, palatal, labial or buccal sides and can rotate on their axis. The prevalence of crowding is 20,6 to 33%. The prevalence of crowding in mandibular permanent incisors is 81,7%.²

Deep bite is a condition that describes an excessive overbite measured vertically between the maxillary and mandibular incisal edges in centric occlusion. It has a prevalence that varies from 11% to 26,1% in the adult population and 36,6% to 76% of orthodontic patients experience deep bite.⁶ In general, deep bite can be caused by dentoalveolar, skeletal or combined factors. Deep bite caused by dentoalveolar factors is associated with undereruption of posterior teeth or overeruption of anterior teeth. Clinical characteristics are characterized by short anterior facial height, flat mandibular plane angle, less than normal gonion angle, large overjet, incisor supraclusion, molar infraclusion, and deep curve of spee.⁷

This case report aims to describe a young female patient with a class I skeletal pattern with crowding and deep over bite who was treated with a passive self-ligating bracket without extraction.

Materials and Methods

This study focuses on the management of a case that begins with the determination of the patient and is accompanied by the determination of the diagnosis. The diagnosis is based on several examination results including general history taking, clinical examination, intraoral examination, functional examination, radiographic examination, lateral cephalometric radiograph analysis, and space requirement analysis. After the diagnosis is determined, problem formulation is carried out along with the treatment objectives. After that, the treatment plan was formulated and then implemented to obtain the treatment results and then discussed comprehensively based on existing theories.

Results and Discussion

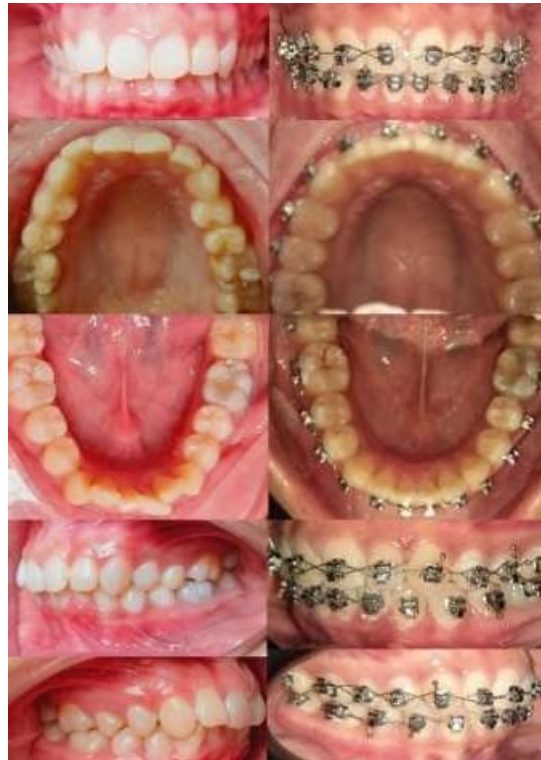After 15 months of treatment, the patient's main complaint was corrected, namely, there was no crowding in the lower anterior region and the teeth were well aligned. There were also improvements in overjet, overbite, molar and canine relationships. Extraoral photos before and after orthodontic treatment from the frontal and lateral planes can be seen in the figure below.

Figure 1. Extraoral photos before and after treatment



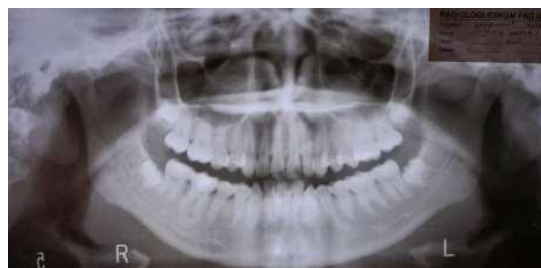There was a 2 mm improvement in overjet with an initial overjet of +4 mm and a final overjet of +2 mm. There was a 3 mm overbite improvement with an initial overbite of +5 mm and a final overbite of + 2mm. The upper and lower dental arch midlines were in line with the facial midline. Inclination and angulation of the teeth are normal with the right and left canine relationship being class I, the molar relationship can be maintained to remain class I. Functional examination obtained canine guidance articulation on right and left lateral movement.

Figure 2. Intraoral photographs before and after treatment

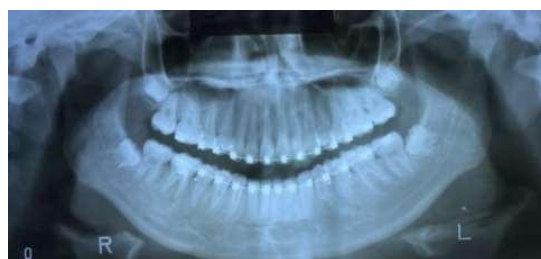

The panoramic radiographs before and after treatment can be seen in Figure 3. The lateral cephalometric radiographs before and after orthodontic treatment can be seen in Figure 4. Evaluation of the results of the panoramic radiograph examination before and after treatment obtained relatively parallel tooth roots.

Figure 3. Panoramic radiographs of the patient before and after treatment

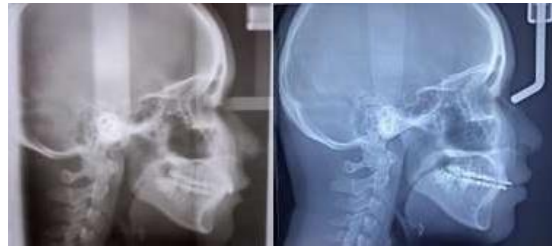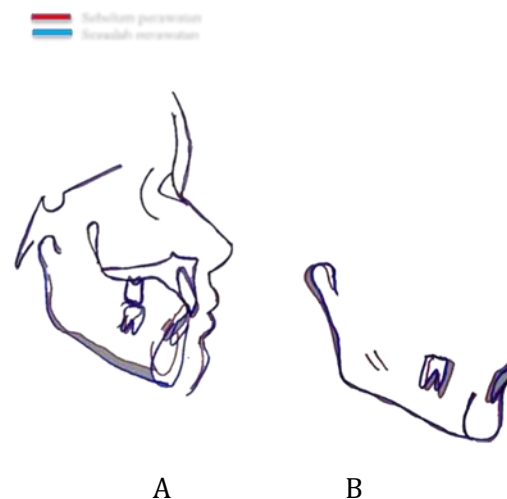


Sebelum



Sesudah

Superimposition of lateral cephalometric radiographs can be seen in Figure 5. Analysis of lateral cephalometry before and after orthodontic treatment will be explained further. Cephalometric radiograph evaluation showed a change in inclination of the incisors and improvement in overjet and overbite.

Figure 4. Lateral cephalometric radiographs of the patient before and after treatment**Figure 5.** Superimposition of lateral cephalometric radiographs. (A) At the base of the cranium; (B) maxilla and mandible (black color shows pre-treatment cephalometry and blue color shows post-treatment cephalometry).

Meanwhile, the results of the lateral cephalometric analysis before and after treatment showed a class I skeletal pattern with a class II tendency with the relationship of the maxilla and mandible to the orthognathic craniate base and the mandible to the orthognathic maxilla. The position of the chin to the mandible is retrusive. Chin to retrusive profile. Hyperdivergent vertical growth of the mid and lower face.

Discussion

A female patient of 15 years and 5 months came to the orthodontic clinic of RSKGM FKG UI with a chief complaint of crowded mandibular front teeth and discomfort. The patient's facial type was dolico-facial, symmetrical, balanced with a convex facial profile. When the patient smiled, 60% of the maxillary anterior tooth surface was visible with a symmetrical buccal corridor. The patient's intra oral examination showed a class II $\frac{1}{2}$ unit right and left canine relationship and a class III $\frac{1}{4}$ unit right and left molar relationship. The patient's overjet was calculated to be +4 mm and there was a deep over bite with an overbite of +5 mm (58%) with a deep curve of spee. Intra oral examination also showed mild crowding in the upper jaw and moderate crowding in the lower jaw. The results of pont analysis showed mild constriction in the maxillary and mandibular arches in the premolar and molar regions with mild protraction in the maxilla. The results of cephalometric analysis showed a class I skeletal pattern with a class II tendency with the relationship of the maxilla and mandible to the orthognathic cranium base and the mandible to the orthognathic maxilla. The position of the chin to the mandible is retrusive. Position of mandible against retrusive profile. Hyperdivergent vertical growth of the mid and lower face. Indication of expansion in all regions.

The patient was treated using passive self-ligating brackets that were placed on the upper and lower jaw. The position of the bracket is one of the important factors in supporting the treatment results. In general, the bracket is placed in the center of the anatomy of the clinical crown of the tooth and parallel to the long axis of the tooth which is commonly called a long axis clinical crown or facial axis clinical crown. In this case, especially the deep bite case, it is recommended to modify the bracket placement to the incisal third to get an intrusion effect from the start of treatment. Placing the bracket more to the incisal is expected to help open the bite in deep bite cases.⁸

Modification of bracket placement to the incisal direction from the center point of the LACC can be done to achieve certain planned or desired goals. Modifying the bracket placement can change

the torque expression on the teeth when they are expressed. It can also cause changes in the level of stress that the periodontal tissues will receive.⁹

The initial aligning and leveling phase or phase I (initial light round wire) aims at aligning and leveling all teeth, correcting anterior rotation, correcting posterior rotation, and initiating arch formation with light force. This phase starts with CuNiTi .014 wire in the upper jaw and CuNiTi .013 in the lower jaw. This was done because the degree of crowding was greater in the lower jaw. The use of CuNiTi wires in this case was based on the consideration of the Cu element in NiTi alloy which can improve shape memory characteristics, thermal stability, and fatigue endurance as well as regulate the transition in the temperature range. This effect can accelerate tooth movement. The use of smaller wires in the lower jaw is intended to provide a lighter force due to the greater degree of crowding. The expected force is often called the threshold force. It also aims for good arch development with enough force to stimulate cellular activity without inhibiting vascularization to the periodontium.^{10, 11}

When aligning and leveling reached the third control in the sixth month of treatment, it appeared that the teeth in the lower jaw were aligned and leveled. This is in accordance with research on self-ligating systems that are able to show the ability to break down crowding faster in the first four to five months from the start of treatment than conventional systems.³

Wire size changes continued until reaching the high-tech edgewise phase. This phase aims to complete leveling and aligning, correct any remaining rotation, control the mesiodistal angulation of the tooth root, initiate torque control and continue the development of the dental arch shape. This phase begins when the wires in the upper and lower jaws are .014x.025 CuNiTi.¹² The choice of torque prescription is important in this case. Dental inclination control plays a role in aesthetics, function, stability and oral health. In a bracket system, tooth inclination is represented by a line perpendicular to the occlusal plane and tangent to the bracket. A positive torque value is assigned if the gingival portion of the tangent line is located lingual or palatal to the incisal portion, while a negative value is assigned for the opposite. Every four degrees of lingual torque of the crown causes one degree of convergence of the tooth root. Therefore, torque control of the anterior teeth not only affects the overbite, but also affects the space requirements of the teeth.¹³

As tooth inclination is known to affect tooth harmony and interdigitation, torque control is also a critical factor in maintaining the stability of treatment results. Self-ligating systems provide full and secure wire engagement and large wire sizes are predicted to express torque more efficiently.^{14, 15}

What needs to be considered in this patient is the presence of a deep curve of spee. A deep curve of spee is a major contributor to deep bite as in this patient. This may be due to over eruption of the mandibular incisors as a form of adaptation to gain occlusion contact with the maxillary incisors.¹⁶

To correct this problem, a modification of anterior bracket placement to the incisors of the mandibular anterior teeth was performed and a turbo anterior bite was used. The anterior bracket placement was more incisal to obtain a favorable intrusion effect in this case. This patient was also fitted with an anterior bite turbo from the beginning of treatment. This aims to correct the patient's deep bite condition. This is supported by the theory that the use of anterior bite plates is effective for deep bite correction. This tool will cause posterior disocclusion which can stimulate the eruption of posterior teeth as well as anterior intrusion. This mechanic will also cause relative intrusion of the incisors due to the vertical growth of the condyles which helps compensate for the increase in vertical dimension caused by molar extrusion. It is this combination of tooth movements that causes the curve of spee to normalize.^{17, 18} For every 1 mm of posterior tooth extrusion, the overbite will decrease by 1,5 mm anteriorly leading to an increase in lower facial height that benefits the patient.⁷

The curve of the spee should be leveled as it is important in biomechanical functions such as mastication, muscle balance, normal occlusion lock, and normal functional movement of the mandible. Some studies have shown that leveling every 1 mm will increase mandibular length by 0,8mm.¹⁹

The use of anterior bite turbo from the beginning in this case is very beneficial because it makes no contact between the maxillary incisor edge and the mandibular anterior bracket, so that the aligning and leveling phases can be carried out simultaneously in the upper and lower jaws. In this case, crowding is greater in the mandible.

Full engagement of the arch wire from the self-ligating bracket since the initial arch wire allows for proclination of the incisors. This proclination will also reduce the anterior deep bite and overjet.²⁰

The proclination of the lower incisors is very unstable as it will tend to return to its pre-treatment position. To overcome this problem, the selection of low torque on the mandibular anterior bracket can minimize these side effects. Choosing the right torque self-ligating bracket will maximize treatment results and make treatment efficient and effective. The selection of torque prescription on the anterior bracket is strongly influenced by the magnitude and plan of the tooth inclination change of the treatment result.²¹

In addition, according to the treatment protocol using Damon on the physiological and biological principles of tooth movement, it is stated that the use of light force from the arch wire will not exceed the strength of the muscles, especially the lip muscles so that the lip muscles will limit the anterior movement of the teeth and the tongue will help the posterior expansion. This effect is commonly referred to as the lip bumper effect. Therefore, the treatment philosophy with Damon in cases without extraction is very likely to allow posterior expansion by keeping the anteroposterior position of the incisors in position or minimizing the side effects that occur.²²

In the treatment of this patient, the use of early light elastic was given from the beginning of treatment. Intermaxillary elastics can be used from the beginning of treatment on self-ligating brackets to assist and direct tooth movement. In small arch wires, the elastic force used must be smaller as well because of the low friction in this type. The use of these elastics is a minimum of 16 hours a day. The force and duration of elastic wear should increase as the size of the arch wire increases.²³

The results of post-treatment cephalometric evaluation showed changes in vertical parameters but still within normal limits. The skeletal pattern in the vertical direction of this patient is within normal limits and tends to be short. The addition of lower facial height is still possible in this case so that in the final result there is a relatively small increase in the vertical height of the lower face and is still within normal limits. This can occur due to posterior tooth extrusion. This condition is favorable for the patient because there is an increase in the height of the lower face which previously had a tendency to be short. Cephalometric evaluation also shows changes in dental parameters, especially in the lower jaw which is proclined but still relatively normal. This proclination occurs due to the leveling and aligning process so that the mandibular incisors can contact the cingula of the maxillary incisors to form an occlusal stop and the interincisal angle is reduced.²¹

Another factor that can affect the stability of the treatment outcome is the position of the mandibular incisor. The mandibular incisor should be positioned as upright as possible on its basal bone. Labial tipping of the mandibular incisor should be avoided to minimize the risk of root resorption and bone dehiscence. The post-treatment cephalometric evaluation showed that the patient's mandibular incisors were on the basal bone and had a relatively normal inclination.¹⁸ The final treatment results also showed that the lower incisor edge was 0-2 mm in front of the centroid of the upper incisor root, which is important for stability in deep bite cases.²⁴

In this case, class II elastics on large rigid stainless-steel wires were used. This is highly recommended to maintain the vertical dimension of the maxillary arch and is important in correcting the canine relation, eliminating crowding, and flattening the curve of spee without overloading the mandibular incisors. Patients are advised to use elastics for at least 16-18 hours a day.¹⁰

The use of class II elastics with turbo bite and reverse curve in some cases is the treatment of choice for deep over bite cases. These mechanics can extrude the molars, intrude and procline the incisors, and facilitate mandibular growth. Clockwise rotation of the occlusal and mandibular planes can occur resulting in an increase in lower facial height. Such effects may be beneficial in hypodivergent cases.²⁵

Evaluation of the condition of the dental arch and the relationship between the upper and lower jaw is important in the finishing phase. The treatment will continue with finishing and detailing using arch wire SS .019x.025 with additional settling elastic. The use of this wire will maintain the archform, complete the torque control, correct the anteroposterior, buccolingual, and vertical relationships.⁸ The clinical features of the dental arch conditions that need to be considered are no residual space, no rotation, no discrepancy of the contact point and marginal ridge, and good inclination and angulation of the teeth. The relationship between the upper and lower jaw that needs to be evaluated includes: overbite, overjet, interdigitation, molar relationship, canine relationship, and articulation movement. The orthodontist must ensure that the patient has a

good static and functional occlusion before declaring orthodontic treatment complete.⁶ In the retention phase for this case, especially deep bite and crowding, a retainer was planned. Long-term retention is recommended to improve prognosis and stability of treatment outcome. To prevent potential relapse, the use of long-term retainers, namely fixed retainers in combination with vacuum retainers, was planned.

Conclusion

The use of self-ligating brackets in treating malocclusion patients has its advantages especially the low friction and fully engaged arch wire which is important during fixed orthodontic treatment. The use of turbo bite, early light elastic, and torque selection for anterior teeth are very important factors in treatment with self-ligating systems. This provides the possibility of reducing treatment time accompanied by proper diagnosis and treatment plan. The selection of anterior bracket torque is useful in determining a good inclination in the final treatment result to support the aesthetics and stability of the treatment result.

The installation of anterior bite turbo for disocclusion in this deep bite case is an advantage in deep bite treatment because it can create a disocclusion that is important in orthodontic treatment while allowing the posterior teeth to extrude and the relative intrusion of the anterior teeth.

Post-treatment evaluation showed improvement in several parameters with reduced overjet and overbite, The stability of these results was supported by balanced incisor position, normal interincisal angles, competent lips, and the ability to achieve a good anterior seal at the end of treatment. Long-term retention is recommended to improve the prognosis and stability of the treatment outcome.

References

1. SH, B., KD, K. & SJ, H. *Introduction to Damon system In new trend in orthodontics*. (Shinhung International Inc, 2008).
2. Harradine, N. W. T. Self-ligating brackets: where are we now? *J. Orthod.* **30**, 262–273 (2003).
3. Chen, S. S.-H., Greenlee, G. M., Kim, J.-E., Smith, C. L. & Huang, G. J. Systematic review of self-ligating brackets. *Am. J. Orthod. Dentofac. Orthop. Off. Publ. Am. Assoc. Orthod. its Const. Soc. Am. Board Orthod.* **137**, 726.e1-726.e18; discussion 726-7 (2010).
4. Moresca, R. Orthodontic treatment time: can it be shortened? *Dental Press J. Orthod.* **23**, 90–105 (2018).
5. Finn, S. *Clinical pedodontic*. (WB Saunders Co, 2003).
6. Rasul, G., Khan, A. & Qiam, F. The Role Of Vertical Parameters In The Development Of Lower Incisor Crowding Amongst Patients. *Pakistan Oral Dent. J.* **32**, 244–247 (2012).
7. Bhateja, N. K., Fida, M. & Shaikh, A. Deep Bite Malocclusion: Exploration Of The Skeletal And Dental Factors. *J. Ayub Med. Coll. Abbottabad* **28**, 449–454 (2016).
8. Birnie, D. The Damon Passive Self-Ligating Appliance System. *Semin. Orthod.* **14**, 19–35 (2008).
9. Sardarian, A., Danaei, S. M., Shahidi, S., Boushehri, S. G. & Geramy, A. The effect of vertical bracket positioning on torque and the resultant stress in the periodontal ligament--a finite element study. *Prog. Orthod.* **15**, 50 (2014).
10. Damon, D. *Damon system, the workbook*. (Ormco, 2003).
11. Keerthana, P. & Chitra, P. Alleviation of Lower Anterior Crowding with Super- Elastic and Heat-Activated NiTi Wires: A Prospective Clinical Trial. *Turkish J. Orthod.* **34**, 127–135 (2021).
12. de Gauw, J. H., Silveira, G. S. & Mucha, J. N. Bracket Placement According to Malocclusion. *Int. J. Orthod. Milwaukee.* **26**, 61–62 (2015).
13. Andrews, L. F. The six keys to normal occlusion. *Am. J. Orthod.* **62**, 296–309 (1972).
14. Harradine, N. W. Self-ligating brackets and treatment efficiency. *Clin. Orthod. Res.* **4**, 220–227 (2001).
15. Mezomo, M., de Lima, E. S., de Menezes, L. M., Weissheimer, A. & Allgayer, S. Maxillary canine retraction with self-ligating and conventional brackets. *Angle Orthod.* **81**, 292–297 (2011).
16. Wilna Maiyestinoval, Nazruddin & Erliera. Perawatan Ortodonti Dengan Menggunakan Sistem Damon: Orthodontic Treatment With Damon System. *Dentika Dent. J.* **16**, 96–101 (2011).

17. M, C. & A, D. *Handbook of Orthodontics*. (Elsevier, 2016).
18. Ghafari, J., Macari, A. & Haddad, R. Deep bite: Treatment options and challenges. *Semin. Orthod.* **19**, 253–266 (2013).
19. Dhiman, S. Curve of Spee - from orthodontic perspective. *Indian J. Dent.* **6**, 199–202 (2015).
20. AG, S. & J, A. *Contemporary treatment mechanic using the straight wire appliance*. In: Graber LW, Vanarsdall R, Vig K, editors. *Orthodontics: current principles and techniques*. (Elsevier Mosby, 2012).
21. Savoldi, F. *et al.* Clinical effects of different prescriptions on the inclination of maxillary and mandibular incisors by using passive self-ligating brackets. *Korean J. Orthod.* **52**, 387–398 (2022).
22. Williams, M. & Stone, E. CBCT Assessment of Dental and Skeletal Changes Using the Damon versus Conventional (MBT) System. *Dentistry* **5**, (2015).
23. Tocolini, D. G., Topolski, F., Moro, A. & Correr, G. M. The T-Control Philosophy and Prescription for Passive Self-Ligating Brackets. *J. Clin. Orthod.* **55**, 159–169 (2021).
24. Houston, W. J. Incisor edge-centroid relationships and overbite depth. *Eur. J. Orthod.* **11**, 139–143 (1989).
25. Badri, M. K. Effective and Efficient Correction of Severe Skeletal Class II Division 1 Malocclusion with Intermaxillary Elastics. *Case reports in dentistry* vol. 2021 6663563 at <https://doi.org/10.1155/2021/6663563> (2021)