


<https://doi.org/10.48047/AFJBS.6.8.2024.559-573>



## African Journal of Biological Sciences



Research Paper

Open Access

### A CROSS SECTIONAL STUDY OF CORNEAL ENDOTHELIAL CHANGES IN PATIENTS WITH SENILE CATARACT WITH OR WITHOUT PSEUDOEXFOLIATION

<sup>1</sup>Dr Mothukuri Venumadhav, <sup>2</sup>Dr Mahitha kanugula, <sup>3\*</sup>Dr Gopi Krishna Chetti, <sup>4</sup>Dr Yerasi Kranthi

<sup>1</sup>Associate professor : Department of ophthalmology, Government Medical College (Singareni Institute of Medical Sciences), Ramagundam.

<sup>2</sup>Senior resident: Department of ophthalmology, Government Medical College, (Singareni Institute of Medical Sciences), Ramagundam

<sup>3\*</sup>Assistant Professor: Department Of Ophthalmology: Government Medical College, (Singareni Institute of Medical Sciences), Ramagundam

<sup>4</sup>Senior Resident: Department Of Ophthalmology : Shanthiram Medical College, Nandyal, Andhra Pradesh

**\*Corresponding author**

Dr Gopi Krishna Chetti ,

Assistant Professor, Department Of Ophthalmology, Government Medical College, (Singareni Institute of Medical Sciences), Ramagundam

[gopikrishna.chetti1@gmail.com](mailto:gopikrishna.chetti1@gmail.com)

Article History  
Volume 6, Issue 8, 2024

Received: 24 Mar 2024

Accepted : 22 Apr 2024

doi: 10.33472/AFJBS.6.8.2024.559-573

#### ABSTRACT

**Aims :** To evaluate and compare the endothelial cell count and its morphology using specular microscopy in senile cataract patients with and without pseudoexfoliation.

**Materials and methods:** A cross-sectional study of patients will be conducted in 80 patients from the ophthalmology Out Patient Department/In Patient Department (OPD/IPD) were patients without PXF and cataracts were selected from age-matched cataract subjects. Most patients underwent thorough ocular examinations, including specular microscopy.

**Results:** The average subject was 60 to 69 years old, with a minimum age of 50 and a maximum age of 86. 70 percent of the 160 patients had SMC. 7.5% and 22.5%, respectively, had SHMC and IMSC. Patients with pseudoexfoliation had a considerably lower mean endothelial cell density. Individuals with pseudoexfoliation (80+) had considerably lower endothelial cell counts than younger patients. For cataract individuals having PXF in the form of polymegathism, the variance coefficient in the cell area is different. In cataract patients with PXF, the average hexagonal pattern of the endothelial is changed in a way called pleomorphism. 4% of 80 PXF cataract patients also had pseudoexfoliative glaucoma. When contrasted to the control group, patients with PXF had thinner central corneas. People with diabetes had a slightly lower endothelial cell density than patients without diabetes.

**Conclusions:** Individuals with pseudoexfoliation have considerably less endothelial cells than age-matched controls. Pleomorphism and polymegathism are two manifestations of the altered endothelial morphology. When compared to controls of the same age, patients with pseudoexfoliation had thinner central corneas.

**Keywords:** Pseudoexfoliation, Central cornea, Pleomorphism, polymegathism

## INTRODUCTION

Pseudoexfoliation is a systemic age-related concern that was first identified by Lindberg in 1917. Its basic ocular manifestation is characterised by a measurable buildup of fibro granular extracellular pseudoexfoliative that is greyish white in colour and is generated by the trabeculum, lens capsule, iris, ciliary body of the eye, and corneal endothelium all have a basal layer of ageing epithelial cells. The disorders that were most closely associated to pseudoexfoliation were keratopathy, pseudouveitis, cataract, glaucoma, lens subluxation, and glaucoma. [1,2]

The endothelium of the cornea, which is composed of a monolayer of polygonal cells, undergoes deturgescence all during life. The corneal endothelium is composed of a single layer of nonregenerative hexagonal cells. If the typical density of corneal endothelial cells in adults, which is approximately 2500 cells/mm<sup>2</sup>, is lowered to approximately 800 cells/mm<sup>2</sup>, decompensation, which is characterised by corneal edoema and loss of corneal transparency, might impair vision. Corneal endothelial cells get exhausted by concentrated PEX synthesis, which results in secondary degeneration and corneal decompensation. The corneal endotheliopathy typically progresses slowly, bilaterally, and asymmetrically. Prior investigations have shown that IOP values are overestimated when the CCT is high and underestimated when the CCT is low . It is obvious that IOP shouldn't be undervalued in these circumstances given that individuals with PEX have a higher incidence of optic disc degeneration and a worse prognosis. Secondary degeneration and corneal decompensation are brought on by the collapse of corneal endothelial cells brought on by focal PEX formation. A bilateral, asymmetric, slowly progressing corneal endotheliopathy is the typical presentation. cataract surgery is challenging in these cases because of intraoperative problems include zonular instability, insufficient mydriasis, lost lens material, which has been connected to a 5-fold greater risk of PEX instances. Therefore, thorough examination and early PEX diagnosis become crucial to warn the surgeon of difficulties. [3]

Specular microscopy is a non-invasive method that outperforms traditional microscopes because it records a picture of the light reflected from an optical interface. The corneal endothelium layer is viewed and recorded utilising computer assisted morphometry to analyse the size, shape, and number of the endothelial cells.

## MATERIALS & METHODS

A cross-sectional study of patients will be conducted at Narayana Medical College, Nellore between February 2021 and August 2022. Sequentially, 80 patients from the ophthalmology Out Patient Department/In Patient Department (OPD/IPD) were included in the study with a diagnosis of cataract and PXF, and 80 age- matched patients with cataract but no PXF were also included in the trial and scheduled for cataract surgery. Each participant gave their free and informed permission.

All patients provided written informed permission after being told of the study's objectives. The institute's research and ethics committee gave its approval to this work. Eighty cataract patients eyes, 80 of which have pseudoexfoliation Eighty cataract patients 80 eyes without pseudoexfoliation

**Inclusion criteria:** Patients with senile cataract >50 years with pseudoexfoliation >50 years

**Exclusion criteria:** Traumatic, congenital, developmental and complicated cataract, Eyes with corneal pathology, Dry eye syndrome and H/O ocular surgery

The best-corrected visual acuity, intraocular pressure (IOP) was measured using Goldmann applanation tonometry that was attached to a slit lamp, and the anterior segment and fundus were both evaluated using an appaswamy slit lamp biomicroscope. We looked for endothelial alterations in the cornea and for pseudoexfoliative material in the pupil edge using the slit lamp. The patient's eyes were checked for iridopathy by examining the iris stroma, and pseudoexfoliative material, such as pregranular radial lines and granular deposits, were looked for on the anterior lens surface when the pupil was dilated. The pseudoexfoliative material in the angles was examined using gonioscopy. Qualitative and quantitative analyses of alterations in corneal endothelial cells were performed using Specular microscopy (Topcon SP- 3000p). The central corneal thickness, endothelial cell density, percentage of hexagonal cells, coefficient of variation in cell size, and number of photographs of both eyes were analysed.

### Preoperative Evaluation

All patients were given a thorough preoperative evaluation, which included a full medical history and an eye and overall body check. An entry was made noting the patient's name, age, sex, address, and profession. Detailed information about the patient's health and eye care was collected. Best corrected vision was documented using the Snellen eye chart. The anterior segment of both eyes were examined using a slit lamp biomicroscope, and pseudoexfoliation material was found on the papillary edge and the lens capsule in both eyes. Posterior segment examination and gonioscopy using a hand-held four-mirror indirect gonioscope were performed after topical anaesthetic (4% xylocaine) was applied to the eye. This analysis paid special attention to the following details. Sampolesi's line, extra pigmentation in the trabecular meshwork, pseudoexfoliation material in the angle, and so on.

**Table -1:** Shaffer grading system

Grade Number	Angle Width	Description	Risk of Closure
4	45-35°	Wide open	Impossible
3	35-20	Wide open	Impossible
2	20	Narrow	Possible
1	< 10	Extremely narrow	Probable
Slit	Slit	Narrowed to slit	Probable
0	0	Closed	Closed

Intraocular pressure was recorded using Goldmann applanation tonometer Ehler et al gave the following formula to calculate corrected IOP.<sup>54</sup> Corrected IOP = Measured IOP +  $[5 \times (\text{mean normal CCT} - \text{measured CCT})] / 70$ . Ehlers et al provided a table showing corrected IOP for CCT was used to calculate corrected IOP in this study.<sup>55</sup>

**Table -2: corrected IOP**

Central corneal Thickness(microns)	Adjustment in IOP(mm Hg)
445	+7
455	+6

465	+6
475	+5
485	+4
495	+4
505	+3
515	+2
525	+1
535	+1
545	0
555	-1
565	-1
575	-2
585	-3
595	-4
605	-4
615	-5
625	-6
635	-6
645	-7

The pupils were dilated with combination of tropicamide and phenylephrine .1 drop was instilled every 10 min over a 30 min interval.

Later slit lamp biomicroscopic examination done for examination of the lens capsule for central and peripheral zones of PXF material deposition.

**Table -3:** Exfoliation grade

	Note
I (mild)	Exfoliation confined to the periphery of the lens and not seen unless the pupil is dilated.
II (moderate)	Flakes of exfoliated material on the edge of the iris or on the surface of the lens capsule or both.
III (Severe)	Flakes of exfoliated material in the angle or on the posterior cornea surface.

They used a Tomey SP-3000 P for non-contact specular microscopy to do this. Participant was told to rest chin and forehead on rest and maintain steady stare at red target. After correctly aligning on the centre of the cornea, the bright central specular picture of the central CEI was acquired. In the event that the endothelial image was not immediately obvious, several attempts were made to focus it. Each of up to 300 photos has 0.135 mm<sup>2</sup> patches where cells are counted. Using a specialised automated cell counter recognition algorithm based on contrast differences and region counting technique, the central endothelial density (ECD, or cells per square millimetre), the variation in size of the endothelial cells (CV - coefficient of variation), and the percentage of hexagonal cells are assessed. By calculating the standard deviation of cell sizes and the coefficient of variation (CV) in cell sizes, we were able to determine the range of variation in cell size. We counted the number of hexagons in the area under analysis as a

measure of the variance in cellshape The results were recorded and tabulated for statistical analysis.

Descriptive and inferential statistics were calculated utilising the students unpaired t-test. Versions 22.0 of SPSS and 6.0 of Graph Pad Prism were used for the analysis. Significant results were defined as having a p-value of 0.05 or lower.

## RESULTS

Gender distribution of patients in our study, which in 51.25% were males and 48.75% were females.

**Table-4: Distribution of patients based on age**

Age in Years	Male	Female	Total
50 to 59	9	12	21
60 to 69	36	22	58
70 to 79	20	29	49
80 and Above	17	15	32
Total	82	78	160

. Most of the individuals were between the ages of 60 and 69. 50 was the minimum age while 86 was the oldest. The age distribution of study participants is shown in this table and graph, with the majority of the subjects falling within the range of 60 to 69 years.

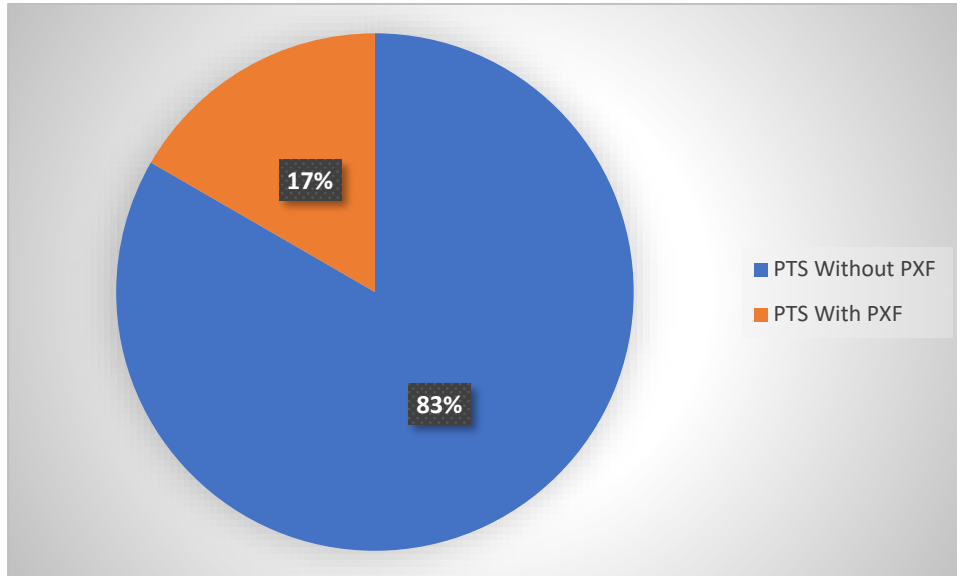
**Table-5: Distribution of patients according to patient details**

Eye	Frequency	Percentage
Right eye	96	60
Left Eye	64	40
<b>Type of Cataract</b>		
SHMC	12	7.5
SIMC	36	22.5
SMC	112	70
<b>Systemic Illness</b>		
DM	12	7.5
DM,HTN	20	12.5
HTN	15	9.37
HTN,BA	5	3.12
IHD	4	2.5
NIL	104	65

With or without PXF, 60% of people had cataracts in their right eye. In the study of 160 patients, the aforementioned table and graph shows that 70% of the patients had senile mature cataracts, 22.5% had senile immature cataracts, and 7.5% had senile hyper mature cataracts. Senile mature cataract was the most prevalent kind of cataract.

According to the aforementioned table and graph, out of the 160 patients who participated in the study, 7.5% had diabetes mellitus, 12.5% had both diabetes and hypertension, 9.37% had hypertension, 3.12% had HTN and BA, 2.5% had IHD, and 65% had no systemic disease.

**Figure-1: Distribution of diabetic patients in each group**

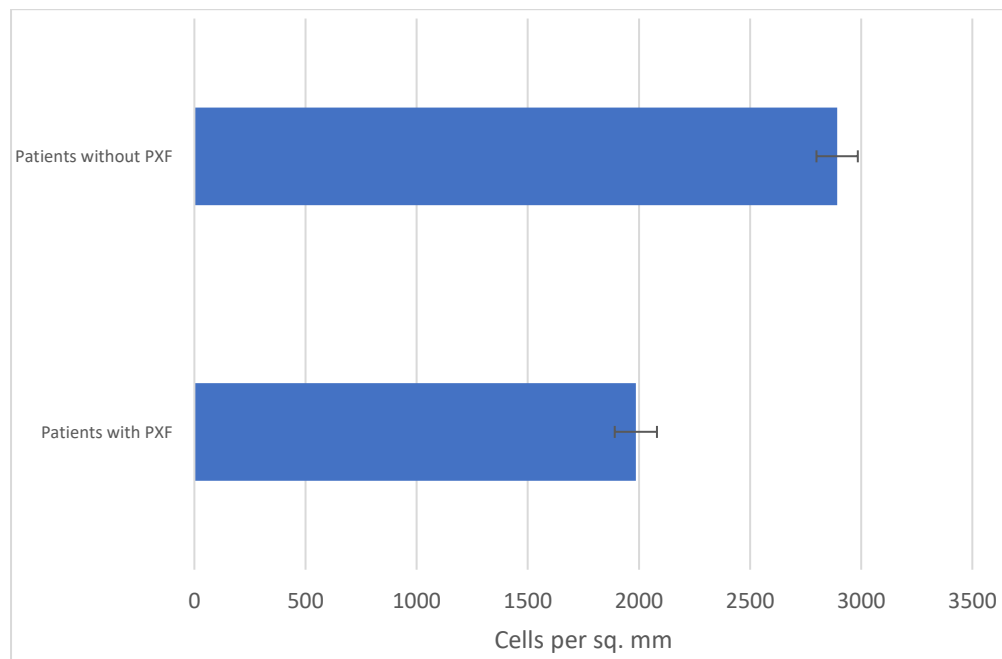


In the research, the allocation of diabetes patients is shown in a table and a graph. In the individuals with pseudoexfoliation group, 10 (83.33%) patients had the condition, while in the control group, 2 (16.66%) patients had it.

**Table-6: Endothelial cell count in patients with PXF and without PXF**

PXF					WITHOUT PXF			
AGE	N	MEAN	Std deviation	Std error mean	N	MEAN	Std deviation	Std error mean
50-59	10	2231.11	479.312	134.1	14	2574.12	195.432	33.232
60-69	32	2348.36	392.465	96.653	29	2712.45	168.432	39.909
70-79	26	2230.84	299.999	86.239	23	2644.00	181.426	41.172
80+	12	1211.18	225.621	119.89	14	2879.50	99.617	49.318

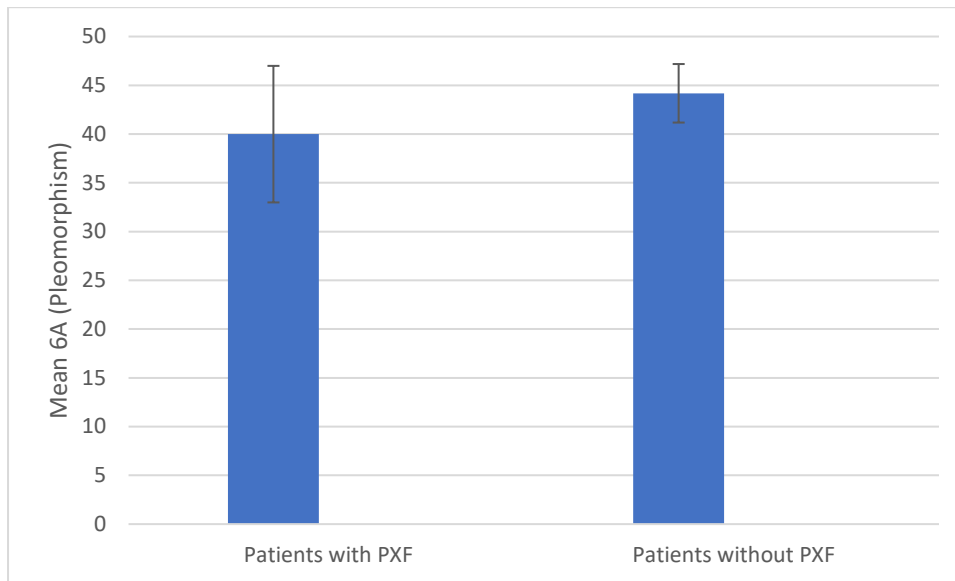
The dispersion of endothelial cells in our investigation, balanced by age, is shown in the table and graph below. Elderly patients with pseudoexfoliation exhibited a much lower endothelial cell count.

**Figure-2: Mean endothelial cell density in cells per sq.mm**

The average endothelial cell density in cataract patient populations with pseudoexfoliation is  $1986.20 \pm 954.406$  cells per sq. mm, whereas the average endothelial cell density in patients without pseudoexfoliation is  $2891.81 \pm 134.654$  cells per sq. mm. This difference is statically important ( $p < 0.0001$ ) because it demonstrates the lowered endothelial cell intensity in patient populations with PXF compared to patients without PXF.

**Table-7: CV% in patients with PXF and without PXF**

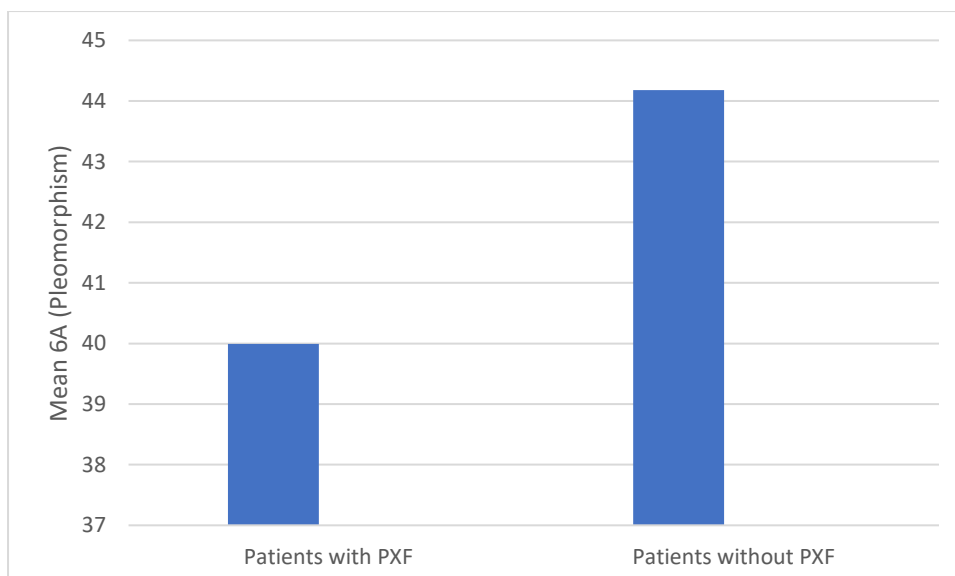
Coefficient of variation in the cell area									
PXF					WITHOUT PXF				
AGE	N	MEAN	Std deviation	Std error mean	N	MEAN	Std deviation	Std error mean	
50-59	10	28.19	3.4596	1.191	14	65.99	3.981	0.987	
60-69	32	32.92	3.281	1.215	29	36.70	3.307	0.995	
70-79	26	44.41	5.938	1.956	23	38.44	2.007	0.669	
80+	12	56.47	31.721	14.642	14	48.75	7.021	2.011	

**Figure-3: Mean CV % ( Polymegathism)**

Although participants with PXF have larger polymegathism than patients without pseudoexfoliation, the mean endothelial cell area in patients with pseudoexfoliation was  $51.10 \pm 4.611$  and in patients without pseudoexfoliation, it was  $31.25 \pm 1.181$  percent, which would be statistically insignificant.

**Table-8: PXF and without PXF in 6A patients**

PXF					WITHOUT PXF			
AGE	N	MEAN	Std deviation	Std error mean	N	MEAN	Std deviation	Std error mean
50-59	10	45.95	5.996	1.519	14	54.15	4.315	1.171
60-69	32	41.45	6.912	1.386	29	51.15	2.975	0.622
70-79	26	39.83	5.801	1.258	23	48.16	2.679	0.990
80+	12	31.57	3.217	1.658	14	42.25	5.482	2.586

**Figure-4: Mean 6A (Pleomorphism)**

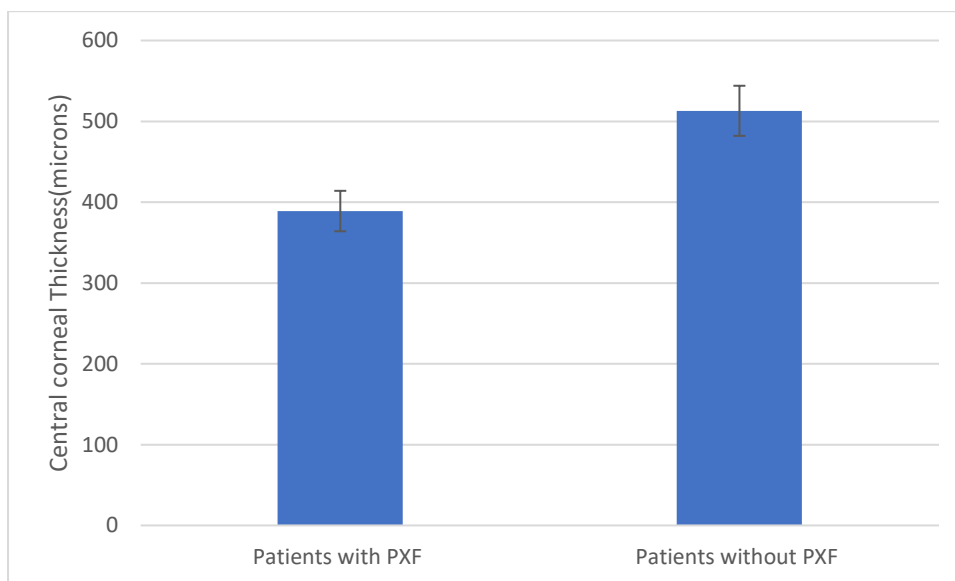


It's indeed statically important (P 0.001) that the average hexagonal pattern of endothelium (6A) in individuals having pseudoexfoliation was  $39.99 \pm 7.440$  and the mean hexagonal pattern in patients without pseudoexfoliation was  $44.18 \pm 3.978$ . Patients with pseudoexfoliation had a considerable impact on the endothelium's typical hexagonal configuration. All age ranges exhibit the decline in hexagonality.

**Table-9: Central corneal thickness in patients with PXF and without PXF**

PXF					Without PXF			
AGE	N	MEAN	Std deviation	Std error mean	N	MEAN	Std deviation	Std error mean
50-59	10	489.82	30.163	7.315	14	507.45	32.831	9.899
60-69	32	489.60	26.873	6.009	29	514.09	31.277	6.668
70-79	26	489.89	14.937	4.979	23	511.71	34.354	9.182
80+	12	480.75	14.315	7.157	14	532	11.533	6.658

**Figure-5: Mean Central corneal Thickness(microns)**



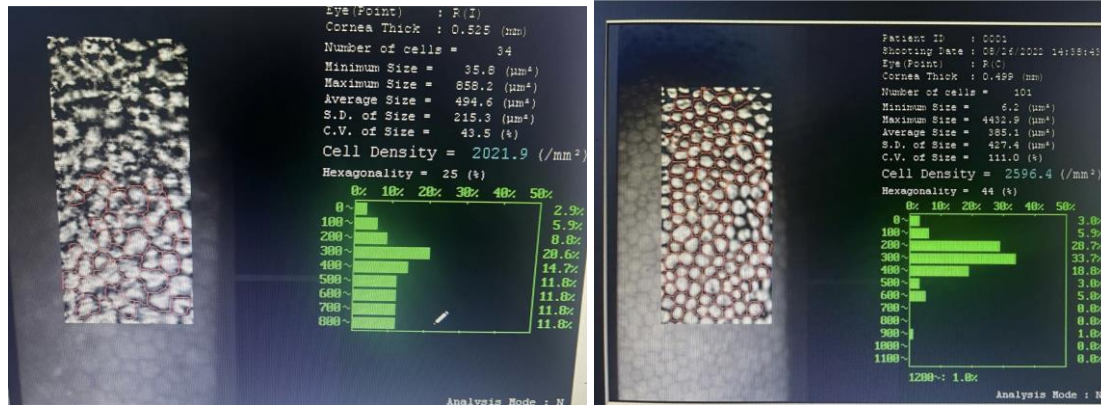
Participants with pseudoexfoliation had a mean CCT of  $389.02 \pm 25.142$ , while those who not had a mean CCT of  $513.02 \pm 428$

**Table-10: Distribution of fundus**

Fundus	Frequency	percentage
WNL	35	22
No view	119	74.375
Glaucoma	6	4
Total	160	100

The dispersion of individuals' fundi are shown in the above table and chart. Whereas in 74% of patients, the fundus wasn't really visible due to SMC and SHMC, and 4% of patients experienced pseudo exfoliative glaucoma.

### Images in study



**Figure-6: Endothelial cell count**

### DISCUSSION

Accumulation of extrinsic fibrils substance on the outside of several ocular surfaces is a hallmark of pseudo exfoliation. Clinically, pseudo exfoliative substance appears as a white, flaky skin substance on the pupil edge, the anterior surface of the lens, and the angle of the anterior chamber, along with an increase in the pigmentation of the trabecular meshwork. Additionally, it is linked to corneal endothelial abnormalities, inadequate pupil dilation, lens instability, and iris atrophy. Although it is a bilateral condition, the asymmetry appearance is clinically recognised as unilateral PXF [4]

By using specular microscopy, the current study investigated the endothelial cell morphology in pupils with clinically unilateral PXF and contrasted it to a seemingly normal peer eye. Numerous imaging techniques have been used to examine the quantitative and qualitative alterations in the morphology of the corneal endothelium in pseudoexfoliative eyes, which demonstrate endothelium destruction. The majority of the individuals in our study were aged between 60 and 69. The people's ages ranged from 50 to 86. [5]

The results support Patients with pseudoexfoliation who were 80 years or older had a considerably lower endothelial cell count than patients who were younger. With age, the average number of endothelial cells declines considerably, suggesting a gradual but constant loss of cells. [6]

It was discovered that large clumps of pseudoexfoliative material adhered to the corneal endothelium and were integrated into the posterior cornea. Descemet membrane was examined using electron microscopy.[7] These can lead to early-stage decompensation of the corneal endothelium and extensive keratopathy. There is a considerable variance in corneal thickness, according to various publications. It appears to be thicker in certain studies, while being thinner in others. [8]

In our investigation, we discovered that senile immature cataract affected 22.5% of the 160 patients, senile mature cataract affected 70%, and senile hyper mature cataract affected 7.5%. The most prevalent type of cataracts were senile mature cataracts. The study's 160 patients had an average of 7.5% diabetic mellitus, 12.5% diabetes and hypertension, 9.37% hypertension, 3.12% HTN and BA, 2.5% IHD, and 65% were systemically Nil affected. We discovered that people with this condition had a reduced endothelial cell count than those without diabetes mellitus, which is consistent with the results reported by Modis L Jr et al[9] Endothelial cell density in PXF patients was  $1986.20+954.406$  cell/mm<sup>2</sup>, which was lower than that of healthy individuals ( $2891.8+1134.654$  cell/mm<sup>2</sup>).

These results concur with those of Krysik K et al[9], who used an ultrasonic pachymeter to evaluate the central corneal thickness. Our investigation's findings are consistent with those of an earlier study by Acar et al.[10] Corneal endothelial cell density was shown to be significantly lower in PXF eyes ( $2336+383$  cells/mm<sup>2</sup>) compared to non-PXF eyes ( $2632+327$  cells/mm<sup>2</sup>) in earlier research by Inoue K et al. [11]. The average concentration of corneal endothelial cells in PXF eyes was  $2298+239$  cells/mm<sup>2</sup>, which was significantly lower 64 than the density of  $265+218$  cells/mm<sup>2</sup> in cataract eyes ( $p=0.026$ ), according to research by Wang M et al.[12]

Its coefficient of variation in cell size was  $34.7\%+7.1\%$  in PXF eyes and  $34.6\%+1.4\%$  in comparable normal eyes, according to Wang M et al. In one normal eye,  $54.5+2.8\%$  of the cells were hexagonal, while  $59.4+9.9\%$  are in the other normal eye. Between the two parameters, there was no statistically discernible difference [12].

The coefficient of variation in cell area between the PXF Group and the Control Group in the research by Inoue K et al. did not vary statistically significantly from each other. In the PXF and control groups, the proportions of hexagonal cells are similar ( $58.48.1\%$  and  $58.96.6\%$ , respectively) [11].

However, Miyazaki K et al. found that the PXF eyes had a much lower endothelial cell density than the comparable normal eyes, as well as a reduced hexagonality and a higher coefficient of variation in cell size [13]. In the PXF eye, the mean endothelial cell density was  $2669\pm 502$  cells/mm<sup>2</sup>, whereas in the normal fellow eye, it was  $2847\pm 540$  cells/mm<sup>2</sup>. The mean coefficient of variation in PXF eyes was  $0.339\pm 0.073$ , whereas it was  $0.343\pm 0.097$  in a comparable normal eye. In PXF eyes, the mean proportion of hexagonal cells was  $57.1\pm 7.1$ , while in a comparable normal eye, it was  $55.3\pm 9.3$ .

The corneal thickness was determined only using a specular microscope in the present research, as opposed to Krysik K et al study, [9] which used 3 distinct imaging modalities, including the Pentacam-Scheimpflug device, time-domain Optical Coherence Tomography (OCT) Visante, and swept-source OCT Casia. The central cornea of the PXF eyes was thicker than that of normal eyes in a prior work. Values were  $523\pm 32$  m for normal eyes and  $528\pm 30$  m for PXF eyes. The statistically significant p-value was 0.01 [14].

We discovered that patients with pseudoexfoliation had a significantly decreased endothelial cell density. Findings from past studies were in agreement with our findings. These researchers have demonstrated that the cell density of the corneal endothelium is significantly influenced by pseudoexfoliative material that settles on the endothelium, perforating it in the direction of Descemet's membrane and rupturing the links between the individual hexagonal structure, resulting in accelerated apoptosis of the cells. A higher level of transforming growth factor beta

1, changes in endothelial fibroblasts, and hypoxia in the anterior chamber are additional factors in addition to these. When the endothelial cell density falls below 800 cells per square millimetre, the cornea decompensates, enabling ocular/aqueous fluid to seep into the corneal stroma and reduce corneal transparency. People who are at risk for corneal decompensation can be identified using a straightforward test that is based on an understanding of endothelial cell density, alerting the surgeon to take the necessary precautions. According to research, when the CCT is high, IOP levels are inflated, and when the CCT is low, they are misunderstood. Due to the rapid progression of optic disc injury and the poorer prognosis in patients with PEX, underestimating IOP might have serious consequences in these circumstances.

**Table-11: Comparison of various studies**

Study	Endothelial cell count without PXF	Endothelial Cell density with PXF	CCT	Morphology
Schlotzer-Schrehardt UM et al [7]	2738.90±233.2	2100±236.6		Altered
Miyake K et al.,[13]	3938.70±233.2	2140±236.6	Decreased	Altered
Krysik K et al., [9]	2898.40±233.2	2210±236.6	Decreased	Altered
Wang M et al [12]	2999.71±233.2	1640±236.6	Decreased	Unaffected
Zheng et al[15]	2738.7±233.2	2240±236.6	Decreased	
Quioga et al[16]	2482;SE=20.36	2315;SE=49.13	Decreased	Altered
Kovaliunas et al[17]	2500.96±351.77	2228.57±290.01		
Zarnowski et al[18]	2721±352	2255±299		Altered
Inoue k et al[19]	2632+/-327	2336+/-383	Decreased	Unaffected
Bazydar T et al[20]	2503 ± 262	2297 ± 359	Decreased	-
Yukse N et al[21]	3073.63 ± 654.49	2592.60 ± 276.36	-	Altered
Present study	2695.86±124.944	2180.20±404.406	Decreased	Altered

During this research, researchers discovered that cataract sufferers with PXF had a mean endothelial cell density that has been 1986.20±954.406 cell/mm<sup>2</sup>, compared to cataract patients without PXF, who had 2891.81±134.654 cell/mm<sup>2</sup>. That was comparable to earlier research by Zheng et al.[15] K. Inoue et al[11] The PXF eyes have a considerably decreased density of corneal endothelial cells. Throughout our investigation, individuals with PXF and patients without PXF had a significant statistical difference in the variation coefficient for the cell area and the % of hexagonal cells.

This examination of adults with and without pseudoexfoliative glaucoma (PEXG) revealed that endothelial cell count is significantly lower in patients with PEXG when compared to those without PEXG. In line with earlier studies, we discovered that the PEX and POAG groups had reduced proportions of hexagonal cells and greater CVs of cell size when compared to normal eyes. There was a statistically meaningful (P0.001) trend more toward severe cell loss and structural abnormalities of the corneal endothelial cells in PXG eyes compared to PXS eyes when all pseudoexfoliative eyes were assessed collectively. Comparing PXS and PXG patients

to control people, higher frequencies of polymegathism and pleomorphism in endothelial cells were found which is consistent with prior studies as Yaksel N et al.[21]. Individuals who underwent pseudoexfoliation saw significant alterations to the endothelium's typical hexagonal configuration.

The present study found that, in comparison to cataract patients without pseudoexfoliation, individuals with pseudoexfoliation had thinner central corneas, lower endothelium densities, and altered morphology in the form of polymegathism and pleomorphism. The results support and confirm earlier study that showed a decrease in endothelial cell density and a change in their morphology.

This indicates that eyes with PXF have changed endothelium morphology that cannot be detected with a slit-lamp exam but can be examined statistically and qualitatively with imaging modalities like the specular microscope. If these modifications are taken into consideration beforehand, endothelial decompensation following intraocular surgery [8] could be avoided. When evaluating intraocular pressure, it's vital to consider the centre corneal thickness of PXF eyes. When evaluating intraocular pressure, it's vital to consider the centre corneal thickness of PXF eyes.

## CONCLUSION

According to the findings of this study, individuals with pseudoexfoliation have considerably less endothelial cells than age-matched controls. Pleomorphism and polymegathism are two manifestations of the altered endothelial morphology. When compared to controls of the same age, patients with pseudoexfoliation had thinner central corneas. The complications presented by pseudoexfoliative syndrome necessitate a thorough pre-operative examination.

The research revealed that after intra ocular procedures, these instances have a much reduced endothelial cell density and a higher risk of corneal decompensation. Additionally, the central corneal thickness in such pseudo exfoliative cases is notably low, which could cause the IOP reading to be underestimated and a potential early glaucomatous damage to be missed. Appropriate treatment for pseudoexfoliative glaucoma can be provided with early identification. Thus, in cases of pseudo exfoliation, examination of endothelial cell density and its morphology becomes a crucial pre-operative step. The current work contributes to a more accurate diagnosis and treatment of these participants prior to cataract surgery by providing a comparative examination of endothelial cell counts in individuals with and without pseudoexfoliation syndrome.

To sum up, a thorough preoperative examination of endothelial cell density and its morphology in cataract sufferers both with and without pseudoexfoliation aids in the most cases in the choice of appropriate surgical intervention and the reduction of problems.

## REFERENCES

1. Tarkkanen A, Kivela T, John G. Lindberg and the discovery of exfoliation syndrome. *Acta Ophthalmol Scand.* 2002;80:151-4
2. U Schlotzer-Schrehardt, M r Koca, G O H Naumann and H Volkholz Pseudoexfoliation syndrome ocular manifestation of a systemic disorder. *Am journal of Ophthalmology,* 2006;141: 921-933

3. G Martone, FCasprini, C Traversi, FLepri, PPichierri and ACaporossi. Pseudoexfoliation Syndrome in vivo confocal microscopy analysis. *Clinical and experimental ophthalmology*. 2007; 35(6): 582-585
4. Harminder S. Dua, Lana A. Faraz, Dalia G. Said. Human corneal anatomy redefined: A novel pre-descemet's layer (Dua's layer) *ophthalmology* 2013; 120:1778-1785
5. Shin Hatou, Mazaka Zuyarmada et al., "Role of insulin in regulation of Na<sup>+</sup> .K<sup>+</sup> dependent ATPase activity and pump function in corneal endothelial cells" *Invest Ophthalmol Viic Sci* 2010;51:3935-3942.
6. Elhawry E, Kamthan G, Dong CQ, Danias J. Pseudoexfoliation syndrome, a systemic disorder with ocular manifestations. *Hum Genomics*. 2012 Oct 10;6(1):22. doi: 10.1186/1479-7364-6-22. PMID: 23157966; PMCID: PMC3500235.
7. Schlötzer-Schrehardt UM, Dörfler S, Naumann GO. Corneal endothelial involvement in pseudoexfoliation syndrome. *Arch Ophthalmol*. 1993 May;111(5):666-74. doi: 10.1001/archophth.1993.01090050100038. PMID: 8489451.
8. Belovay GW, Goldberg I. The thick and thin of the central corneal thickness in glaucoma. *Eye (Lond)*. 2018 May;32(5):915-923. doi: 10.1038/s41433-018-0033-3. Epub 2018 Feb 15. PMID: 29445115; PMCID: PMC5944650.
9. Krysik K, Dobrowolski D, Polanowska K, Lyssek-Boron A, Wylegala EA. Measurements of Corneal Thickness in Eyes with Pseudoexfoliation Syndrome: Comparative Study of Different Image Processing Protocols. *J Healthc Eng*. 2017;2017:4315238.
10. B. T. Acar, I. B. Buttanri, and M. S. Sevim, "Evaluation of anterior segment parameters in pseudoexfoliation syndrome patients," *Turkish Journal of Ophthalmology*, 2010:vol. 40, no. 4, p.217–222.
11. Inoue K et al. Morphological study of corneal endothelium and corneal thickness in pseudoexfoliation syndrome 2003 May-Jun; 47 (3): 235-9
12. You Q. S., Xu L., Wang Y. X., et al. Pseudoexfoliation: normative data and associations: the Beijing eye study 2011. *Ophthalmology*. 2013;120:1551–1558.
13. Miyazaki M, Kubota T, Kubo M, Kiyohara Y, Iida M, Nose Y, Ishibashi T. The prevalence of pseudoexfoliation syndrome in a Japanese population: the Hisayama study. *J Glaucoma*. 2005;14(6):482–484.
14. Syed Z, Srikanth K, Nagarajan S. Diurnal variation of central corneal thickness and intraocular pressure in eyes with pseudoexfoliation. *Indian J Ophthalmol*. 2019 Oct;67(10):1607-1609. doi: 10.4103/ijo.IJO\_1899\_18. PMID: 31546490; PMCID: PMC6786200.
15. X. Zheng, A. Shiraishi, S. Okuma et al., "In vivo confocal microscopic evidence of keratopathy in patients with pseudoexfoliation syndrome," *Investigative Ophthalmology and Visual Science*. , 2011; 52(3) p. 1755–1761.
16. L. Quiroga, C. van Lansingh, M. Samudio, F. Y. Peña, and M. J. Carter, Characteristics of the corneal endothelium and pseudoexfoliation syndrome in patients with senile cataract. *Clinical and Experimental Ophthalmology*. 2010;38(5):p 449–455.
17. E. Kovalionas, S. Stech, and N. Jurkute. Characteristics of the corneal endothelium and pseudoexfoliation syndrome in patients with senile cataract. *Acta Ophthalmologica*. 2012;90(249).
18. T. Zarnowski, A. Łęka, and A. Dyduch, Gęstość śródbłonkarogówki u chorych z jaskrą, *Klinika Oczna*. 2005.107(7–9): p. 448–451.
19. Inoue K et al. Morphological study of corneal endothelium and corneal thickness in pseudoexfoliation syndrome 2003 May-Jun; 47 (3): 235-9.

*Dr Mothukuri Venumadhav / Afr.J.Bio.Sc. 6(8) (2024)*

20. Bozydar T Tomaszewski et al. Evaluation of the Endothelial Cell Density and the Central Corneal Thickness Pseudoexfoliation Syndrome and Pseudoexfoliation Glaucoma. *J Ophthalmol* 2014 Jul 1: 123683
21. Yuksel N, Emre E, Pirhan D. Evaluation of Corneal Microstructure in Pseudoexfoliation Syndrome and Glaucoma: In Vivo Scanning Laser Confocal Microscopic Study. *Curr Eye Res* 2016; 41 (1): 34-40