

<https://doi.org/10.48047/AFJBS.6.10.2024.6008-6016>



African Journal of Biological Sciences

Journal homepage: <http://www.afjbs.com>



Research Paper

Open Access

Effect of fenugreek seeds (*Trigonella foenum graecum* L.) on male rat of the Wistar strain (kidney function)

Faiza Rouag¹, Mabrouk Boussena¹, Sabri Benkermiche¹, Samir Djemli¹, Ines Reffes¹, Rouya Memouni¹.

¹Department of Biology, Laboratory of Neuro-endocrinology applied, Badji Mokhtar University, BP 12, 23000, Annaba, Algeria.

Corresponding author: Faiza Rouag : foufikenza@gmail.com

Article History

Volume 6, Issue 10, 2024

Received : 17 Apr 2024

Accepted : 16 Jun 2024

doi: 10.48047/AFJBS.6.10.2024.6008-6016

ABSTRACT

Fenugreek (*Trigonella foenum-graecum* L.) is an annual herb belonging to the Fabaceae family. It is found all over the world, but it is of Mediterranean origin. The whole fenugreek plant can be used in herbal medicine, but it is mainly the seeds that are of therapeutic interest.

The aim of this study is to strengthen the scientific data on the benefit of using the aqueous extract of fenugreek seeds in the medical field. Our study aims to evaluate the effect of fenugreek on some biochemical parameters of renal function of male rats of the Wistar strain, as well as the study of kidney tissue. The administration of the aqueous extract of fenugreek seeds for 30 successive days (*Trigonella foenum-graecum* L.) by gavage at a dose of 250g / l of water. In this work, we used 21 male rats, divided into three groups including a control group (T), a group treated with the aqueous extract of fenugreek (F) and a group (G) force-fed with

water alone for 30 days by the oral gavage method. Our results show a significant decrease in both blood urea and creatinine levels mainly in group (F) compared to group (T). We therefore found a significant decrease in the serum uric acid (AU) concentration in the fenugreek-treated group (F) compared to the control group (T).

The results found reveal that the aqueous extract of fenugreek seeds plays a nephroprotective or even prophylactic role in nephropathologies by improving the parameters of the kidney balance sheet while maintaining their serum levels within the range of normal values, also preservation of intact kidney tissue.

Keywords: Fenugreek; Wistar rats; Urea; Creatinine; Uric acid; Kidney.

INTRODUCTION

The African continent is endowed with a rich plant biodiversity in the world, with a very high number of plants used as herbs, natural foods and for therapeutic purposes. Many different natural substances have been identified and many of them have found use in traditional medicine for the prophylaxis and treatment of diseases (**Zeghad N, 2009**).

The protective effects of medicinal and aromatic plants against various diseases have been attributed to the presence of phytochemicals, including polyphenols which form a very important class of molecule, and are known for their numerous activities biological, such as antiviral, anti-inflammatory, antioxidant, anticancer activity, etc (**Bahorun I, 1997**).

Fenugreek (*Trigonella foenum-graecum* L.), *helba* in Arabic and *tifiḍas* (Berber) is a very ancient medicinal and aromatic plant, the seeds of this plant are widely used in traditional medicine, and in many countries to fight against various pathologies. They have extraordinary and promising therapeutic properties (anti-tumor, hypoglycemic, anti-inflammatory, hypocholesterolemic, and antioxidant) (**Ait Braham K & al., 2013**).

Fenugreek is a small leguminous plant whose young leaves are eaten in salads and seeds as a spice. It is one of the oldest medicinal plants and culinary traditions of human history. Its aromatic principles were already used in Pharaonic Egypt, around 1,500 years BC, to embalm the dead and purify the air in homes and places of worship. Its seeds were used in the making of bread, a culinary practice that persists in modern Egypt as well as in India.

The kidney plays a central role in maintaining the volume and ionic composition of body fluids. This homeostasis is ensured by glomerular filtration and tubular changes (reabsorption and secretion). Significant changes in flow urinary and those of the composition of urine reflect the capacity of the kidney to adapt to a given physiological or pathological situation (**Sibernagl S & al., 1996**).

This work is part of a study on research and valorization plants of medicinal and therapeutic interest. It focuses on the study of the effect of the aqueous extract of fenugreek seeds, used in traditional medicine, on the physiology of the kidneys in Wistar rats.

METHODOLOGY

Experimental Animals

In our study, we used the white rat of the Wistar strain having a weight body included in 200-205 g as basic biological material from the institute pastor (Algiers, Algeria). They are mammals of the order of rodents largely used in several areas of research. rats were housed in clean polyethylene cages (58 × 38 × 19 cm), 7 rats per cage and maintained under standard conditions of temperature (25 ± 2 °C), humidity (65 ± 5%) with a photoperiod of 12 hours of light and 12 hours of darkness. Rats were fed commercial chow and tap water ad libitum. Procedures for the care and handling of animals were in accordance with applicable international laws and policies (NIH Publication No. 85-23, 1985, revised 1996).

Study desing

After a three-week adaptation period, the male rats were divided into three (3) experimental groups, seven (7) rats in each group and treated as follows:

- Group 1 : included control dams (T)
- Group 2 : included dams treated with fenugreek extract (F)
- Group 3 : included dams treated with mineral water (G)

Rats were identified by numbering at the tail with a permanent color marker.

Fenugreek extract administration

The aqueous extract of fenugreek was prepared by the infusion process. 250g of fenugreek seeds were immersed in a liter (1L) of mineral water brought to a boil and kept at heat for five minutes (5 min). The extract is stored in the refrigerator until use (Harchane et al 2012).

The administration of the water and the aqueous extract of the fenugreek seeds were carried out orally by the force-feeding method, which was carried out at 8:30 a.m. daily for 30 days in the rats of the batches (G) and (F).

Biochemical assays:

We carried out the dosage of urea, creatinine and uric acid according to the spin react technical sheet

Histological study

The histological sections were carried out in the histology laboratory following the classic technique of (Houlot, 1984).

The histological technique aims to obtain thin, colored sections of biological materials observable under an optical microscope. The biological material to be studied will undergo different treatments before being able to be analyzed under the microscope: Fixation, dehydration, impregnation, inclusion, cutting and staining. The final result must reflect as closely as possible the native state of the sample (Lydie & al., 2010).

Statistical analysis

All results were expressed as the mean \pm standard deviation ($M \pm SD$). Statistical calculations were performed using GraphPad Prism software version 5.00 (Trial), March 12, 2007, except for body weights we used XLSTAT Launcher software (version 17.0.0.0) the comparison between the different groups was performed using Student's t-test. The differences were considered to be:

-Not significant when ($P > 0.05$);

-Significant when ($P \leq 0.05$);

-Highly significant when ($P \leq 0.01$);

-Very highly significant when ($P \leq 0.001$). With P: the significance level.

RESULTS

Uric acid variation

Our results show a significant decrease ($p \leq 0.05$) in the UA level in the lot treated with fenugreek (F) compared to the lot (T). No significant difference between batch (T) and batch (G) (**Figure 1**).

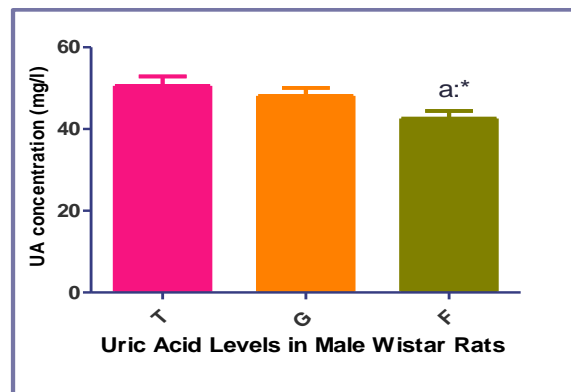


Figure 1: Variation in UA (mg/l) in control rats (T), rats treated with fenugreek (F) and rats gavaged with water alone (G). Results are expressed as Mean \pm SEM (n=7) (a: comparison vs T).

Urea variation

Our results show a significant decrease ($p \leq 0.05$) in the urea level in the lot treated with fenugreek (F) compared to the lot (T). No significant difference between lot (T) and lot (G) (**Figure 2**).

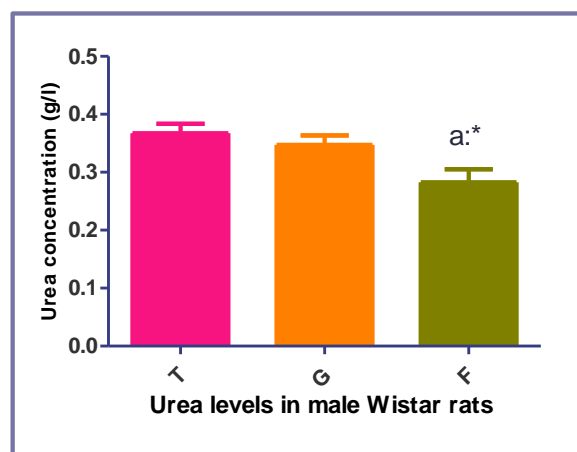


Figure 2: Variation in urea (g/l) in control rats (T), rats treated with fenugreek (F) and rats force-fed with water alone (G). Results are expressed as Mean \pm SEM (n=7) (a: comparison vs T).

Creatinine Variation

Our results show a significant decrease ($p \leq 0.05$) in the creatinine level in the lot treated with fenugreek (F) compared to the lot (T). No significant difference between batch (T) and batch (G) (**Figure 3**).

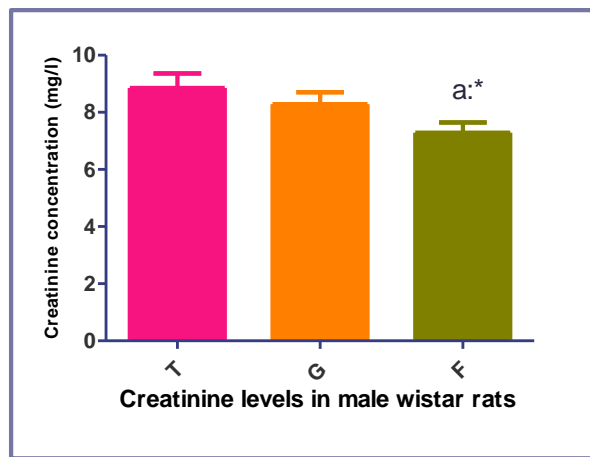


Figure 3: Variation in creatinine (mg/l) in control rats (T), rats treated with fenugreek (F) and rats gavaged with water alone (G). Results are expressed as Mean \pm SEM (n=7) (a: comparison vs T).

Histological study of the kidneys

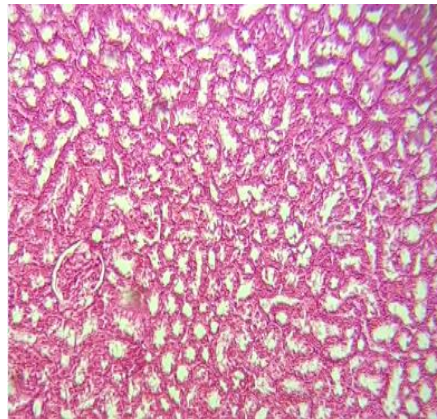


Figure 4: Kidney tissue from a rat from the control group (Hematein-Eosin “HE” G \times 40 staining). Histology in control rats (Figure 46) shows well-preserved tissue architecture, with the white pulp, red pulp and marginal zone visible, normal structure of the renal tubules and glomeruli.

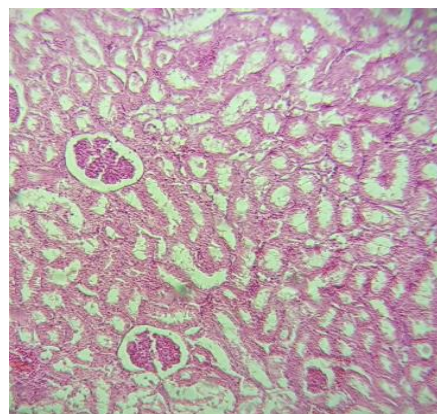


Figure 5: Kidney tissue from a rat from the lot treated with fenugreek (Hematein-Eosin “HE” stain G \times 40).

The histological study of the tissue section in rats treated with fenugreek shows a normal tissue appearance of which the white pulp, the red pulp and the marginal zone are clearly visible, normal structure of the renal tubules and glomeruli.

DISCUSSION

Our results showed that the medicinal plant named *Trigonella foenum graecum* L. has a nephroprotective capacity in addition to its anti-oxidant property, this has been confirmed by the work of several researchers; Fenugreek leaves and seeds are used as (antioxidant, antidiabetic, antimicrobial, anti-inflammatory, etc.) (Mabrouk B & al., 2017).

Fenugreek contains phenolic and flavonoid compounds that help improve its antioxidant capacity. This property could be useful in preventing or slowing down the progress of certain diseases due to oxidative stress (Priya V & al., 2011), and also to delay the oxidation of lipids in a variety of food products (Madhava M & al., 2011).

Fenugreek has demonstrated anti-inflammatory capabilities in in vitro research and hepatoprotective. The seeds of *Trigonella foenum-graecum* L. act as an agent protective against abnormalities induced in the liver (Öner A & al., 2008).

Fenugreek has a nephroprotective effect which can be attributed to its properties antioxidants and hypoglycemics and its constructive effect of collagen which prevents ROS-induced destruction of kidney filtration and basement membrane (Adeniyi T, 2012). Polyphenols are the most abundant and potentially very powerful antioxidants in our diets (Edeas M, 2007). Phenolic compounds have several other biological activities: they are antiallergic, anti-edematous and anti-inflammatory (Landolfi N & al., 1985).

In 2010, Navayath & al reported that the aqueous extract of *Trigonella foenum graecum* (fenugreek) prevents cypermethrin-induced hepatotoxicity and nephrotoxicity. Some rats Wistar males were treated with 1/10 LD50 (25 mg/kg body weight) of cypermethrin (CM) and 10% aqueous extract of fenugreek (GFaq) for 60 days. CM treatment resulted in increased thiobarbituric acid reactive substances (TBARS), depletion of glutathione (GSH), and reduced activities of superoxide dismutase (SOD), catalase (CAT), glutathione peroxidase (GPx) and glutathione-S-transferase (GST) in the liver and kidneys.

They observed a significant reduction in total phospholipids and an increase in the activities of phospholipases A (PLA) and C (PLC) in the liver and kidneys and an increase in the activities of serum marker enzymes, aspartate transaminase (AST), l alanine tansaminase (ALT), alkaline phosphatase ALP), lactate dehydrogenase²⁷ (LDH) and gamma glutamyl transferase (GGT). Treatment with 10% GFaq showed replenishment of antioxidant status and returned all values to near normal level, indicating the protective effect of fenugreek (Navayath S & al., 2010).

In 2007, Laroubi & al studied the prophylactic effect of *Trigonella foenum seeds graecum* L. on the formation of kidney stones in rats. The inhibitory effect of the aqueous extract of fenugreek seeds has been examined on calcium oxalate kidney stone formation induced by ethylene glycol (EG) with ammonium chloride.

At the end of the experiment, all kidneys were removed and examined microscopically for possible crystal/stone locations and the total amount of calcium in the kidney tissue was assessed. Blood was collected to determine calcium, phosphorus, creatinine, and urea levels. The results showed that the amount of calcification in the kidneys and the total amount of

kidney tissue calcium in rats treated with fenugreek were significantly reduced compared to the untreated group. Fenugreek can be used in the treatment of patients with calcium urolithiasis (**Laroubi A & al., 2007**).

Thus the antioxidant properties of fenugreek and *Allium sativum* improve the organ functions (**Masjedia F et al., 2008**).

On the other hand, numerous *in vivo* models have been developed to understand the mechanisms involved in the formation of urinary stones and to determine the effects of various therapeutic agents on the development and progression of the disease (**Khan S, 1985**) (**Bruijn W et al., 1995**).

As a result, the effectiveness of the medicinal plant, *Trigonella foenum-graecum*, has been evaluated on rats made nephrolithiasis by administration of ethylene glycol. Their seeds are widely used in Morocco for the treatment of kidney stone formation like antilithiasis and a diuretic agent.

It is suggested that the effect could be beneficial in preventing the formation of urinary stones, by excreting small particles from the kidney and reducing the risk of them being retained in the urinary tract. The data also showed that the plant extract may contain substances that effectively inhibited the aggregation of CaOx crystals.

A number of plant extracts and their isolated constituents have also showed a protective effect against the formation of kidney stones (**Atmani F & al., 2003**) (**Selvam P & al., 2001**). Particle agglomeration is considered a crucial step in urinary stone formation because larger crystalline aggregates are less likely to spontaneously pass from the urinary tract. Therefore, it is proposed that the plant extract can keep the CaOx particles dispersed in the solution and thus allow their elimination easily from the kidney.

Fenugreek extract has been used extensively in a number of formulations to plant based. For centuries it has been used as folk medicine. Its various Pharmacological actions reported so far in ancient medical literature have been scientifically validated. These include its antiulcerogenic effect (**Suja P & al., 2002**), anti-inflammatory, antipyretic (**Ahmadiani A & al., 2001**) and immunomodulatory effects (**Bin-Hafeez B & al., 2003**).

Fenugreek seeds have also been reported to increase levels of antioxidants and lower lipid peroxidation in the liver from ethanol poisoning (**Thirunavukkarasu T & al., 2003**).

CONCLUSION :

In the present study, we tried to show the effect of the aqueous extract of a herbaceous medicinal plant which is fenugreek on renal function in male wistar rats.

The ingestion of this product during the experimental period showed remarkable changes in the serum secretion of some biochemical parameters including a significant reduction in the level of urea, creatinine and also the level of uric acid in rats treated with fenugreek compared to control rats, also no alteration of kidney tissue and no cytotoxicity.

REFERENCES

Adeniyi T, Ajayi, Sado G, Olopade H (2012): Vitamin C and garlic (*Allium sativum*) ameliorate nephrotoxicity and biochemical alterations induced in lead-exposed rats. *Journal of Medicine and Medical Sciences*, 3:273-280.

- Ahmadiani A, Javan M, Semnianian S, Barat E, Kamalinejad M. (2001):** Anti-inflammatory and antipyretic effects of *Trigonella foenum graecum* leaves extract in the rat. *J Ethnopharmacol* 75: 283–286.
- Ait Braham K, Messaoudi S (2013) :** Etude De L'activité Antioxydante Des Polyphénols Des Graines De *Trigonella Foenum-Graecum* L. (Fenugrec), Université Abderrahmane Mira De Bejaïa, 01p.
- Atmani F, Slimani Y, Mimouni M, Hacht B (2003):** Prophylaxis of calcium oxalate stones by *Hernaria hirsuta* on experimentally induced nephrolithiasis in rats. *Br J Urol Int* 92: 137–140.
- Bahorun I (1997) :** Substances naturelles actives : la flore mauricienne, une source d'approvisionnement potentielle Ed AMAS. P 1-17.
- Bin-Hafeez B, Haque R, Parvez S, Pandey S, Sayeed I, Raisuddins S (2003):** Immunomodulatory effects of fenugreek (*Trigonella foenum-graecum* L.) extract in mice. *Int Immunopharmacol* 3: 257–265.
- Bruijn W, Boevé E, Van Rum PRWA (1995):** Etiology of calcium oxalate nephrolithiasis in rats.II. The role of the papilla in stone formation. *Scanning Microsc* 9: 115–125.
- Edeas M (2007) :** Les polyphénols et les polyphénols de thé. *Phytothérapie*, 5, 264-270.
- Houlot R., (1984).** Techniques d'histologie et de cytopathologie. Ed Maloine. pp 225-227.
- Khan S (1985):** Calcium oxalate urolithiasis in rat: is it a model for human stone disease. *Scanning Microsc* 2: 759–774.
- Landolfi N, Leone J, Womack J et Cook R (1985):** Activation of T lymphocytes result in an increase in H-2-encoded neuraminidase. *Immunogenetics*, 22, 159-167.
- Laroubi A, Touhami M, Farouk L, Zrara I, Aboufatima R, Benharref A (2007):** Prophylaxis effect of *trigonella foenum graecum* L. seeds on renal stone formation in rats. *Phytotherapy research*; 21(10): 921-925.
- Lydie V., Emilie V., (2010).** *Histotechnol* : L'importance de la fixation en histochimie, 23, (1), 25-32.
- Mabrouk B, D'Araujo M, Gouia H, Bettaieb B (2017) :** Effets de l'acide salicylique sur l'activité antioxydante de Fenugrec (*Trigonella-foenum-graecum*L). Cultivé en présence d'Arsenic et de Zinc. *Revue des Régions Arides*, (43).
- Madhava-Naidu M, Shyamala B, Pura J, Naik G, Sulochanamma et Srinivas p (2011):** Chemical composition and antioxidant activity of the husk and endosperm of fenugreek seeds. *LWT-Food Science and technology*, 44, 451-456.
- Masjedia F, Golb A, Dabiric S (2008):** Preventive Effect of Garlic (*Allium sativum* L.) on Serum Biochemical Factors and Histopathology of Pancreas. *utical Research*, 3: 325-338
- Navayath S., Thiyagarajan D., (2010).** Aqueous extract of *trigonella foenum graecum* (fenugreek) prevents cypermethrin induced hepatotoxicity and nephrotoxicity. *SAGE journals online*. 29(4): 311-319. Available from: <http://het.sagepub.com/content/29/4/311.abstract>
- Öner A, Mercan I, Öntürk H, Cengiz N, Erten R, Özbek H (2008):** Antiinflammatory and hepatoprotective activities of *Trigonella foenum graecum* L. *Pharmacologyonline*, 2, 126-132.

Priya V, Jananie R, Vijayalakshmi K (2011): IJPSR. 2(10): 2704-2708.

Selvam P, Kalaiselvi P, Govindaraj A, Murugan V, Sathishkumar (2001): Effect of A. lanata leaf extract and vediuppu chunnam on the urinary risk factors of calcium oxalate urolithiasis during experimental hyperoxaluria. Pharmacol Res 43: 89–93.

Sibernagl S, Despopoulos A (1996) : Physiologie. Deuxième édition Médecine-Sciences Flammarion Paris ; 120-153.

Suja P, nuradha C, Viswanathan P (2002): Gastroprotective effect of fenugreek seeds (*Trigonella foenum-graecum*) on experimental gastric ulcer in rats. J Ethnopharmacol 81: 393–397.

Thirunavukkarasu T, Anuradha C, Viswanathan P (2003): Protective effect of fenugreek (*Trigonella foenum graecum*) seeds in experimental ethanol toxicity. Phytother Res 17: 737–743.

Zeghad N (2009) : Etude Du Contenu Polyphénolique De Deux Plantes Médicinales D'intérêt Economique (*Thymus Vulgaris*, *Rosmarinus Officinalis*) Et Evaluation De Leur Activité Antibactérienne, Thèse de Doctorat Université Mentouri Constantine, 01 P.