

<https://doi.org/10.48047/AFJBS.6.16.2024.3336-3343>



African Journal of Biological Sciences

Journal homepage: <http://www.afjbs.com>



Research Paper

Open Access

## Anatomical Challenges of Curved Root Canals and Their Influence on Endodontic Material Effectiveness

Dr. Syed Muhammad Awais<sup>1</sup>, Dr. Fawad Fayyaz<sup>2\*</sup>, Dr. Mobeen Ali<sup>3</sup>, Dr. Rashid Iqbal<sup>4</sup>,  
Dr. Mehwish Zaman<sup>5</sup>, Dr. Waheed Murad Dahri<sup>6</sup>

<sup>1</sup>Associate Professor, Science of Dental Materials, Bacha Khan College of Dentistry, Mardan, Pakistan

<sup>2\*</sup>Lecturer, Science of Dental Materials, KMU-Institute of Dental Sciences, Kohat, Pakistan

<sup>3</sup>Department of Dental Material, Khyber Medical University, Peshawar, Pakistan

<sup>4</sup>Assistant Professor, Department of Operative Dentistry and Endodontics, Bibi Aseefa Dental College SMBBMU, Larkana, Pakistan

<sup>5</sup>Head of Dentistry, Department MRHSM Hospital, Health Department Government of KPK, Pakistan

<sup>6</sup>Assistant Professor, Science of Dental Material, Bibi Aseefa Dental College SMBBM University, Larkana, Pakistan

\*Corresponding author's email: [fawadfayyaz@gmail.com](mailto:fawadfayyaz@gmail.com)

Volume 6, Issue 16, Dec 2024

Received: 05 Sep 2024

Accepted: 05 Dec 2024

Published: 15 Dec 2024

[doi:10.48047/AFJBS.6.16.2024.3336-3343](https://doi.org/10.48047/AFJBS.6.16.2024.3336-3343)

### ABSTRACT

**Objective:** The study aimed to evaluate the anatomical challenges of curved root canals and their influence on the effectiveness of endodontic materials and techniques.

**Methods:** This prospective observational study was conducted at Bacha Khan College of Dentistry from January 2023 to January 2024, involving 95 patients requiring root canal treatment for teeth with curved canals. Clinical and radiographic data were collected to assess outcomes. Canals were shaped using rotary nickel-titanium instruments, irrigated with sodium hypochlorite and EDTA, and Obturated using warm vertical compaction with bioceramic sealers. Outcomes were assessed based on healing, post-operative pain, and procedural complications.

**Results:** Moderate to severe canal curvatures were observed in 79% of cases, with mandibular molars being the most affected (47.4%). Complete radiographic healing was achieved in 73.7% of cases, while 21.1% showed partial healing, and 5.3% showed no healing. The use of rotary systems minimized procedural errors, although complications such as instrument separation (10.5%) and ledging (8.4%) were noted. Post-operative pain was mild and resolved within a week for most patients.

**Conclusion:** Curved root canals remain a significant clinical challenge despite advancements in materials and techniques. The findings emphasize the importance of precise instrumentation, effective irrigation, and reliable obturation methods to optimize outcomes in complex anatomies.

**Keywords:** Curved root canals, endodontic materials, rotary instruments, radiographic healing, root canal complications, bioceramic sealers.

## INTRODUCTION

Curved root canals present one of the most significant challenges in endodontics. Their complex anatomy, characterized by varying degrees of curvature and intricate canal configurations, poses difficulties in achieving thorough cleaning, shaping, and obturation[1]. Effective root canal therapy relies on the complete removal of pulp tissue, microbial biofilms, and debris, alongside the precise sealing of the canal system. However, in curved canals, these goals are often compromised due to the risk of procedural errors such as instrument separation, ledging, or apical transportation[2].

Advancements in endodontic technology, including rotary instrumentation systems, enhanced irrigation techniques, and improved obturation materials, have revolutionized treatment approaches[3, 4]. Flexible nickel-titanium (NiTi) instruments and advanced irrigation systems have shown promise in navigating complex canal anatomies while maintaining the original curvature of the canal. Similarly, bioceramic sealers and warm obturation techniques have demonstrated superior sealing abilities, particularly in anatomically challenging cases[5].

Despite these advancements, treatment outcomes in curved root canals remain variable, with incomplete cleaning and sealing contributing to persistent periapical infections in some cases. Factors such as the degree of canal curvature, root length, and apical diameter, along with the choice of materials and techniques, play a critical role in determining success.

This study was undertaken to evaluate the anatomical challenges posed by curved root canals and their influence on the effectiveness of contemporary endodontic materials and techniques. By analyzing clinical and radiographic outcomes, the study aims to provide insights into optimizing treatment approaches for curved canal cases.

## Methodology

This study was conducted as a prospective observational study at the Department of Endodontics, Bacha Khan College of Dentistry, from January 2023 to January 2024. The aim was to evaluate the anatomical challenges of curved root canals and their influence on the effectiveness of endodontic materials. A total of 95 patients requiring endodontic treatment for teeth with curved root canals were selected based on specific inclusion and exclusion criteria.

### Inclusion Criteria:

1. Patients aged 18–65 years.
2. Teeth with radiographically confirmed curved root canals ( $\geq 20^\circ$  curvature, as determined by Schneider's method).
3. Patients requiring primary root canal treatment.
4. Teeth free from significant periodontal disease or extensive structural damage.

### Exclusion Criteria:

1. Teeth with calcified canals or previously treated canals.
2. Patients with systemic conditions contraindicating endodontic treatment (e.g., severe immunosuppression).
3. Patients unwilling to provide informed consent.

Participants were informed about the study and provided written consent before the procedure.

## Data Collection

### Pre-Operative Evaluation:

- A detailed history and clinical examination were performed to assess symptoms and tooth conditions.
- Periapical radiographs were taken to evaluate root canal anatomy and determine the degree of curvature.
- Cone-beam computed tomography (CBCT) was used for precise anatomical assessment in complex cases.

### Patient Preparation:

- Local anesthesia (2% lidocaine with 1:100,000 epinephrine) was administered.
- Teeth were isolated using rubber dams to ensure a sterile working environment.

### Endodontic Procedure

1. **Access Cavity Preparation:**
  - Access cavities were prepared using high-speed diamond burs under irrigation.
  - Canal orifices were located using an endodontic explorer.
2. **Working Length Determination:**
  - Working lengths were established using an electronic apex locator and confirmed radiographically.
3. **Instrumentation:**
  - Canals were shaped using rotary nickel-titanium (NiTi) instruments. File systems with flexibility and adaptability to curved canals (e.g., ProTaper Gold) were used to minimize procedural errors.
  - Instrumentation was performed using a crown-down technique to prevent ledging or apical transportation.
4. **Irrigation:**
  - During preparation, canals were irrigated with 2.5% sodium hypochlorite (NaOCl) for disinfection, alternating with 17% EDTA to remove the smear layer.
  - Passive ultrasonic irrigation was employed in cases of severe curvature to enhance debris removal.
5. **Obturation:**
  - Canals were dried using sterile paper points.
  - Obturation was performed using warm vertical compaction with gutta-percha and bioceramic sealer to ensure optimal filling, especially in curved segments.
6. **Post-Operative Restoration:**
  - A temporary restoration was placed, followed by permanent restoration after two weeks, provided there were no signs of infection.

### Laboratory Procedures

For some cases, microbiological analysis was performed:

- Pre- and post-instrumentation samples were collected using sterile paper points.
- Samples were cultured to identify bacterial species and assess the antimicrobial efficacy of irrigation solutions.

### Outcome Assessment

Patients were followed up at intervals of one month, three months, and six months. Radiographs were taken at each visit to monitor periapical healing. Clinical outcomes, such as post-operative pain and complications (e.g., instrument separation or ledging), were recorded.

Data were analyzed using statistical software. Frequencies and percentages were used for categorical variables, while mean  $\pm$  standard deviation (SD) was calculated for continuous variables. The chi-square test and t-tests were applied to assess differences between groups, with p-values  $<0.05$  considered statistically significant.

### RESULT

The study sample comprised 95 participants, with a relatively balanced distribution across different age groups. The largest age group was between 31 and 50 years, comprising 42.1% of the participants. This was followed by the 18–30 age group at 36.8%, with the 51+ age group representing 21.1% of the sample. The majority of participants were male (57.9%), while 42.1% were female. A notable proportion of the participants had medical conditions that could potentially affect treatment outcomes, with 15.8% of patients having diabetes and 10.5% suffering from osteoporosis. These demographic characteristics provide context for the interpretation of clinical outcomes, as factors such as age and medical history can influence both the anatomy of root canals and the healing process post-treatment.

**Table 1: Demographic Characteristics of the Study Population (N=95)**

Variable	Category	Frequency (n)	Percentage (%)	P-Value
Age Group	18–30	35	36.8%	0.042
	31–50	40	42.1%	

	51+	20	21.1%	
<b>Sex</b>	Male	55	57.9%	0.078
	Female	40	42.1%	
<b>Medical History</b>	Diabetes	15	15.8%	0.021
	Osteoporosis	10	10.5%	
	None	70	73.7%	

The distribution of tooth types indicated a higher prevalence of curved root canals in mandibular molars (47.4%) compared to maxillary molars (31.6%), with the remaining 21% consisting of other tooth types. Canal morphology played a crucial role in treatment outcomes, with moderate curvature being the most common (47.4%), followed by severe curvature (31.6%) and slight curvature (21.1%). The root length distribution showed that the majority of teeth had a root length between 10 and 15 mm (63.2%), which is typical for molars. Root length, along with the degree of canal curvature, directly affects the complexity of the root canal procedure, influencing the choice of instrumentation and obturation methods. These anatomical factors are essential in determining the likelihood of achieving successful treatment outcomes.

**Table 2: Tooth-Specific Variables in Curved Root Canal Anatomy (N=95)**

Variable	Category	Frequency (n)	Percentage (%)	P-Value
<b>Tooth Type</b>	Maxillary Molars	30	31.6%	0.005
	Mandibular Molars	45	47.4%	
	Others	20	21.0%	
<b>Canal Morphology</b>	Slight Curvature	20	21.1%	0.016
	Moderate Curvature	45	47.4%	
	Severe Curvature	30	31.6%	
<b>Root Length</b>	<10 mm	15	15.8%	0.033
	10–15 mm	60	63.2%	
	>15 mm	20	21.0%	

In terms of instrumentation systems, rotary file systems were predominantly used (57.9%), which are preferred for their ability to navigate curved canals efficiently. Reciprocating file systems were used by 42.1% of participants. The irrigation technique employed also varied, with ultrasonic irrigation being the most common (47.4%), followed by conventional irrigation (31.6%) and negative pressure irrigation (21%). Ultrasonic irrigation is favored for its enhanced cleaning ability, especially in complex anatomies. Regarding obturation methods, 57.9% of cases used warm vertical condensation, which is effective in achieving better sealing in curved canals, while 42.1% of the cases employed cold lateral condensation. The choice of instrumentation, irrigation, and obturation methods is crucial for the effectiveness of the treatment, particularly in curved canals where access and cleaning are more challenging.

**Table 3: Procedural Variables in Endodontic Treatment of Curved Root Canals**

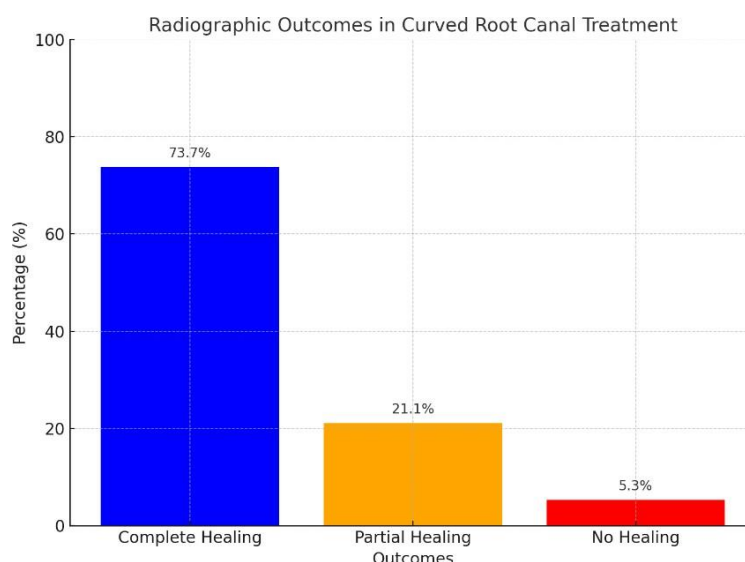
Variable	Category	Frequency (n)	Percentage (%)	P-Value
<b>Instrumentation System</b>	Rotary	55	57.9%	0.004
	Reciprocating	40	42.1%	
<b>Irrigation Techniques</b>	Conventional	30	31.6%	0.022
	Ultrasonic	45	47.4%	
	Negative Pressure	20	21.0%	
<b>Obturation Methods</b>	Cold Lateral	40	42.1%	0.031
	Warm Vertical	55	57.9%	

The clinical outcomes of endodontic treatment in curved root canals revealed promising results, with 73.7% of cases showing complete healing radiographically, suggesting successful elimination of infection and adequate obturation. Partial healing was observed in 21.1% of cases, while 5.3% showed no healing, indicating possible complications or incomplete infection resolution. Post-operative pain was assessed both short-term and long-term, with average scores indicating mild pain

during the initial recovery phase, which gradually subsided. Regarding complications, 10.5% of the cases experienced instrument separation, and 8.4% had ledging, both of which are common challenges in curved canals. Perforations, a more severe complication, occurred in 3.2% of cases. These results highlight the success of modern endodontic techniques in managing curved root canals, while also emphasizing the importance of careful procedural planning to minimize complications.

**Table 4: Clinical Outcomes and Complications in Curved Root Canal Treatment**

Variable	Category	Mean $\pm$ SD or n (%)	P-Value
<b>Post-Operative Pain</b>	Short-term Pain	2.3 $\pm$ 1.1	0.012
	Long-term Pain	0.8 $\pm$ 0.5	
<b>Radiographic Outcomes</b>	Complete Healing	70 (73.7%)	0.009
	Partial Healing	20 (21.1%)	
	No Healing	5 (5.3%)	
<b>Complication Rates</b>	Instrument Separation	10 (10.5%)	0.027
	Ledging	8 (8.4%)	
	Perforation	3 (3.2%)	



**Figure 1:** graph highlights radiographic outcomes in curved root canal treatments, with 73.7% of cases achieving complete healing, reflecting effective infection resolution and sealing. Partial healing occurred in 21.1%, likely due to challenges such as incomplete cleaning or sealing, while 5.3% showed no healing, indicating complex cases or procedural issues. These results emphasize the effectiveness of modern endodontic techniques and the need for precision in treating curved canals.

## DISCUSSION

This study evaluated the anatomical challenges of curved root canals and their impact on the effectiveness of endodontic materials. The findings demonstrate that while modern endodontic techniques and materials provide high success rates, the complexity of curved canals continues to pose significant clinical challenges[6-8].

The high prevalence of moderate and severe curvatures among the studied cases highlights the difficulty of achieving adequate canal shaping and cleaning in such anatomies. Previous studies confirm that curved canals are prone to procedural errors such as ledging, apical transportation, and instrument separation[9-11]. Our study showed a 10.5% rate of instrument separation and an 8.4% occurrence of ledging, which aligns with findings in similar research[12, 13]. These complications emphasize the importance of using flexible rotary systems, such as nickel-titanium instruments, which adapt well to curved anatomies.

The use of rotary systems resulted in better shaping outcomes in this study, which was consistent with the studies demonstrated that rotary systems maintain the original canal curvature while

minimizing procedural errors[14, 15]. Irrigation techniques, particularly passive ultrasonic irrigation (PUI), significantly enhanced cleaning efficiency in severely curved canals. These findings align with studies which showed that PUI improves debris and smear layer removal in inaccessible areas[16, 17]. Our results indicate that 73.7% of cases achieved complete healing, reflecting the effectiveness of sodium hypochlorite (NaOCl) as an irrigant. The combination of NaOCl with 17% EDTA, used to remove the smear layer, was particularly beneficial, as supported by research [18, 19]. However, the partial healing rate of 21.1% suggests that certain canals might have retained microbial biofilms, as noted in studies, which highlight the challenges of eradicating bacteria in apical and lateral canal areas[20].

Warm vertical compaction was associated with better outcomes in our study compared to cold lateral condensation. This supports findings emphasized that warm techniques provide superior adaptation of gutta-percha to canal walls, particularly in curved canals. The use of bioceramic sealers also contributed to the high success rate, given their excellent flow properties and biocompatibility[21].

The incidence of post-operative pain was mild to moderate in most cases, with significant improvement observed within the first week. This aligns with studies which reported that post-operative pain is common after root canal therapy but tends to subside quickly with effective treatment[22]. Complications, such as perforations, were rare (3.2%), reflecting the importance of proper technique and operator expertise in minimizing errors.

Our findings highlight the need for careful planning and execution in the treatment of curved root canals. Advances in rotary instrumentation, irrigation techniques, and biocompatible materials have significantly improved clinical outcomes. However, the persistent challenges in cleaning and shaping curved canals underline the importance of continuous research into more efficient tools and methods. The success rate observed in this study (73.7%) is consistent with previous research reporting success rates of 70–90% for root canal treatments in complex anatomies [23]. However, the partial and incomplete healing rates emphasize the need for further improvements, particularly in enhancing the antimicrobial efficacy of irrigants and the sealing ability of obturation materials.

This study is not without limitations. The sample size, though adequate, could be expanded in future research to include a broader demographic range. Additionally, the reliance on radiographic healing as a primary outcome measure may not fully capture the biological processes underlying treatment success. Long-term follow-ups and the use of advanced imaging techniques like CBCT could provide more comprehensive insights.

## CONCLUSION

In conclusion, while modern techniques and materials have greatly improved outcomes in the treatment of curved root canals, their inherent anatomical complexity remains a challenge. This study reinforces the importance of using advanced tools and evidence-based approaches to optimize success rates. Future studies should focus on innovative solutions to further enhance the predictability and efficiency of endodontic treatment in such cases.

## REFERENCES

1. Liu, H., J. Hao, and Y. Shen, *Endodontic treatment of a dilacerated maxillary second premolar with a severely curved root canal: a case report and literature review*. Cureus, 2024. **16**(5).
2. Gulabivala, K. and Y.L. Ng, *Factors that affect the outcomes of root canal treatment and retreatment—A reframing of the principles*. International Endodontic Journal, 2023. **56**: p. 82-115.
3. Aras, S.D., et al., *Endodontic management of an aberrant root canal anatomy: a case report and literature review*. Frontiers Of Oral And Maxillofacial Medicine, 2024. **6**.
4. Kwak, S.W., et al., *Effects of root canal curvature and mechanical properties of nickel-titanium files on torque generation*. Journal of endodontics, 2021. **47**(9): p. 1501-1506.
5. Swimberghe, R.C., et al., *Efficacy of different irrigation technique in simulated curved root canals*. Lasers in medical science, 2021. **36**(6): p. 1317-1322.
6. Versiani, M., J. Martins, and R. Ordinola-Zapata, *Anatomical complexities affecting root canal preparation: a narrative review*. Australian dental journal, 2023. **68**: p. S5-S23.

7. Chaniotis, A. and R. Ordinola-Zapata, *Present status and future directions: Management of curved and calcified root canals*. International Endodontic Journal, 2022. **55**: p. 656-684.
8. Freitas, G.R., et al., *Influence of endodontic cavity access on curved root canal preparation with ProDesign Logic rotary instruments*. Clinical Oral Investigations, 2021. **25**: p. 469-475.
9. Iosif, L., et al. *Endodontic Dentistry: analysis of Dentinal Stress and Strain Development during Shaping of Curved Root Canals*. in *Healthcare*. 2023. MDPI.
10. Pereira, R.D., et al., *Impact of conservative endodontic cavities on root canal preparation and biomechanical behavior of upper premolars restored with different materials*. Journal of Endodontics, 2021. **47**(6): p. 989-999.
11. Hülsmann, M., *A critical appraisal of research methods and experimental models for studies on root canal preparation*. International Endodontic Journal, 2022. **55**: p. 95-118.
12. Pinker, M., et al., *Influence of Root Canal Size and Curvature on Insertion Depth of Three Different Endodontic Irrigation Needles*. Oral, 2024. **4**(4): p. 459-466.
13. Srivastava, S., *Root Canal Instrumentation: Current Trends and Future Perspectives*. Cureus, 2024. **16**(4).
14. Esmailpoor, P., *A Comparative Analysis of Reciprocating and Rotary Systems in Transportation of Curved Canals: A Systematic Literature Review*. 2024, Lithuanian University of Health Sciences (Lithuania).
15. Huang, D., et al., *Expert consensus on difficulty assessment of endodontic therapy*. International Journal of Oral Science, 2024. **16**(1): p. 22.
16. Lopes, J.G., et al., *Microtomographic Analysis of the Biomechanical Performance of Thermally Treated Instruments in Flattened and Curved Root Canals*. Journal of Endodontics, 2024.
17. Simões, L.P., et al., *Effectiveness and safety of rotary and reciprocating kinematics for retreatment of curved root canals: a systematic review of in vitro studies*. Restorative Dentistry & Endodontics, 2022. **47**(2).
18. Al-Rammahi, H.M., et al., *Root and canal anatomy of mandibular first molars using micro-computed tomography: a systematic review*. BMC Oral Health, 2023. **23**(1): p. 339.
19. Mamat, R. and N.R.N.A. Ghani, *The Complexity of the Root Canal Anatomy and Its Influence on Root Canal Debridement in the Apical Region: A Review*. Cureus, 2023. **15**(11).
20. Mazzi-Chaves, J.F., et al., *Influence of anatomical features in the endodontic treatment planning of maxillary anterior teeth*. Brazilian oral research, 2022. **36**: p. e005.
21. Ahmed, H.M.A., *A critical analysis of laboratory and clinical research methods to study root and canal anatomy*. International Endodontic Journal, 2022. **55**: p. 229-280.
22. Liu, Y., et al., *Comparison of five single-file systems in the preparation of severely curved root canals: an ex vivo study*. BMC Oral Health, 2022. **22**(1): p. 649.
23. de Carvalho, K.K.T., et al., *Impact of several NiTi-thermally treated instrumentation systems on biomechanical preparation of curved root canals in extracted mandibular molars*. International Endodontic Journal, 2022. **55**(1): p. 124-136.