



Transformative Solutions: A Comprehensive Case Series on Large Ventral Hernia Repairs with Transversus Abdominis Release

**Authors: Dr Balavignesh Durai¹; Dr Rahul Raj Chennam Lakshmi kumar ²;
Dr Dakshay A Chordia³; Prof Dr Khalilur Rahman⁴; Dr Mudduluru Vishnu Priya¹
Dr Sinduja Saravanan¹**

1- Post Graduate, Department of Department of General Surgery, Saveetha Medical College and Hospital Simats and Saveetha University;

2-Assistant Professor, Department of General Surgery, Saveetha Medical College and Hospital Simats and Saveetha University;

3- Senior Resident Department of General Surgery, Saveetha Medical College and Hospital Simats and Saveetha University;

4- Professor, Department of General Surgery, Saveetha Medical College and Hospital Simats and Saveetha University;

Primary author: Dr. Balavignesh Durai¹

ORCID iD:0009-0001-2518-4761 postgraduate,

Department of General Surgery, Saveetha Medical College and Hospital Simats and Saveetha University Email – teechirurg2744@gmail.com;

Telephone- 9629489437

Corresponding Author: Dr Rahul Raj Chennam Lakshmi Kumar²

ORCID iD: 0009-0000 2917-1055 Assistant professor,

Department of General Surgery, Saveetha Medical College and Hospital Simats and Saveetha University. Email – rahul808@gmail.com; Telephone-

9600429942

Dr. Dakshay A Chordia ⁴**ORCID iD: 0009-0005-3933-9858**Senior Resident, Department of General Surgery, Saveetha Medical College and Hospital Simats and Saveetha University Email – dakshaychordia@gmail.com; Telephone – 9003187055

Article Info

Volume 6, Issue Si3, 2024

Received: 19 April 2024

Accepted: 28 May 2024

doi: 10.48047/AFJBS.6.Si3.2024.1907-1913

ABSTRACT:

Large ventral hernias present a significant challenge to patients and surgeons, requiring innovative and effective repair techniques. In this case series, we provide an in-depth analysis of patients with large ventral hernias who underwent treatment using the transverse abdominis release (TAR) technique. Through a retrospective review of this patient cohort, we offer insights into the surgical approach, perioperative management, and postoperative outcomes. The abstract includes detailed information about the patient's demographic characteristics, such as their age, comorbidities, and hernia size. It also outlines the surgical procedure and emphasizes the steps involved in the TAR technique. Additionally, it discusses the postoperative recovery and complications and provides information on the follow-up of patients. This case series provides valuable data to the hernia surgery field, highlighting the efficacy and safety of the TAR technique in treating large ventral hernias. The information presented in this study can guide both practicing surgeons and researchers in optimizing patient outcomes.

KEYWORDS: Hernias, Ventral, Ventral Hernia, Hernia, Abdominal

INTRODUCTION:

Incisional hernia is a frequent complication that can occur following laparotomy, with a reported incidence rate of 10-20%. Ventral hernia repair, including Primary Ventral Hernia and Incisional Hernia, is a common procedure surgeons perform. However, the ideal surgical approach for ventral hernias with large defects is still a matter of debate due to the high risk of complications. It can be challenging to obtain a reliable and durable repair with low morbidity and recurrence rates for large ventral hernias, which can lead to complications such as abdominal compartment syndrome, respiratory failure, frequent recurrences, and poor quality of life when dealing with large abdominal wall hernias, it is crucial to avoid using traditional suture and mesh techniques which do not relax the musculofascial flaps. Such techniques lead to poor outcomes that can be detrimental to the patient's health and well-being. Therefore, it is highly recommended to opt for alternative surgical approaches such as the Component separation technique that can provide better results and ensure a successful outcome. which makes CST a promising alternative for achieving successful outcomes. Achieving tension-free closure of the midline is crucial for successful surgical outcomes. However, it's worth noting that creating large lipocutaneous flaps can increase the risk of wound complications. Therefore, Before proceeding with this technique, it is crucial to consider its potential risks and benefits carefully. The Posterior Component Separation, also known as the Transverse Abdominis Release (TAR), was developed by Yuri Novitsky Field(Novitsky et al., 2012) and Michael Rosen. The Transversus Abdominis Release (TAR) technique is an advanced solution to the wound morbidity and mesh limitations associated with the anterior component technique. TAR

extends the retro-rectus plane developed by the Rives-Stoppa repair, simultaneously allowing for mesh placement and fascial advancement.

METHODS :

This retrospective case series examines a cohort of patients who presented with large ventral hernias and subsequently underwent treatment with Transversus Abdominis Release, (TAR) at SAVEETHA MEDICAL COLLEGE AND RESEARCH INSTITUTE between November 2022 and November 2023. The study was conducted with meticulous attention to detail, and the researchers collected and analyzed comprehensive data on patient demographics, comorbidities, hernia size, surgical procedure details, perioperative management, postoperative complications, and long-term follow-up outcomes. The comprehensive data collection approach adopted in this study is critical in maintaining the accuracy, reliability, and validity of the results. The collected information gives valuable insights into the treatment of large ventral hernias and constitutes a sound basis for further research and analysis. The study on the Transversus Abdominis Release (TAR) technique for large ventral hernias provides hope and optimism for patients and surgeons alike. Traditional methods of treatment often result in complications and morbidity, but TAR offers a promising solution that can provide better postoperative outcomes and reduce morbidity. The meticulous retrospective case series offers insights into the surgical approach, perioperative management, and postoperative outcomes associated with TAR, highlighting its efficacy and safety in treating large ventral hernias. This study's commitment to maintaining the highest standards of professionalism and expertise is inspiring and sets an example for the medical community to follow. By sharing these findings, we can optimize patient outcomes and guide practicing surgeons and researchers in the field of hernia surgery. We thank you for your attention and support.

Table 1: Represents the distribution of recurrent and novel hernia in our population




Table 2: Represents the loss of domain in the population

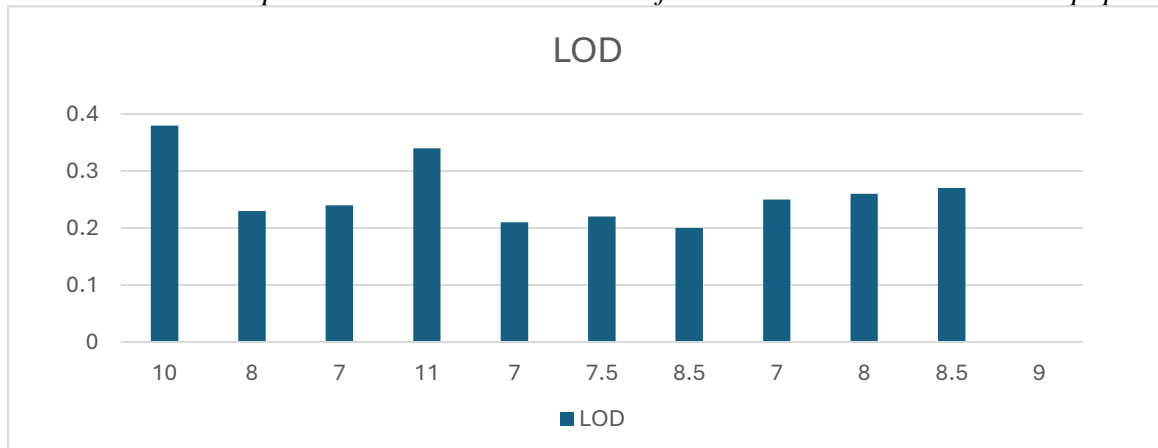


Figure 1: shows the different methods of loss of domain calculation

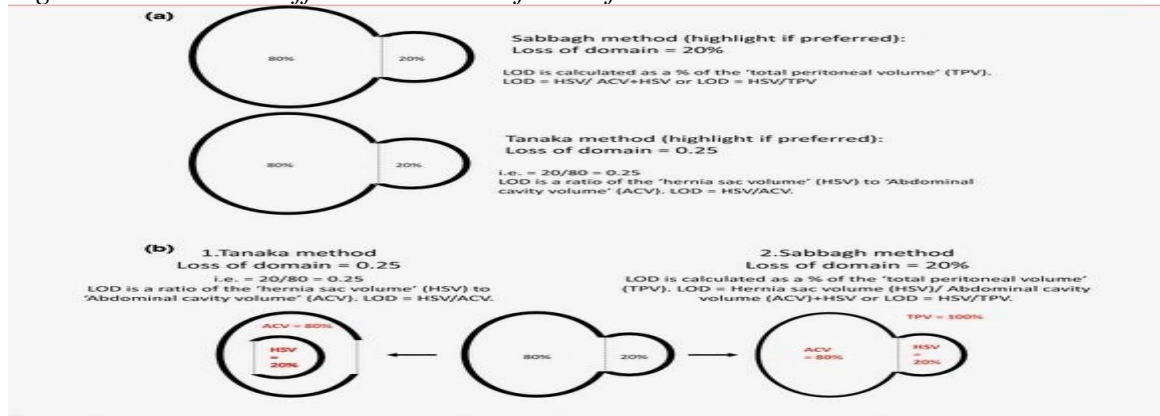
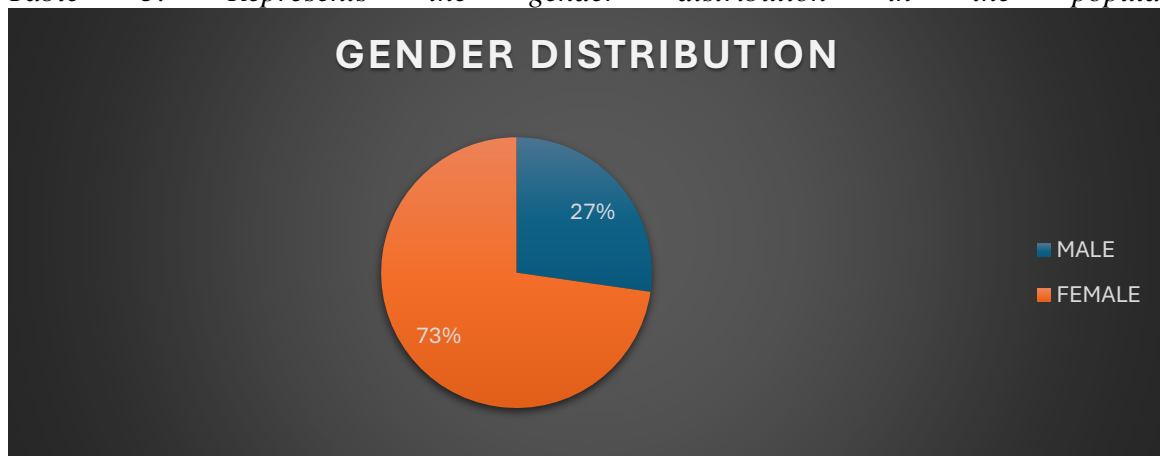


Fig. 1 a Two schematic diagrams used in Round 1 to illustrate the Tanaka and Sabbagh methods for describing loss of domain. b Schematic diagram to facilitate understanding and accurately describe the Tanaka and Sabbagh volumetric definitions. (Diagram used for Rounds 2 and 3)

SOURCE : (Parker et al., 2019)

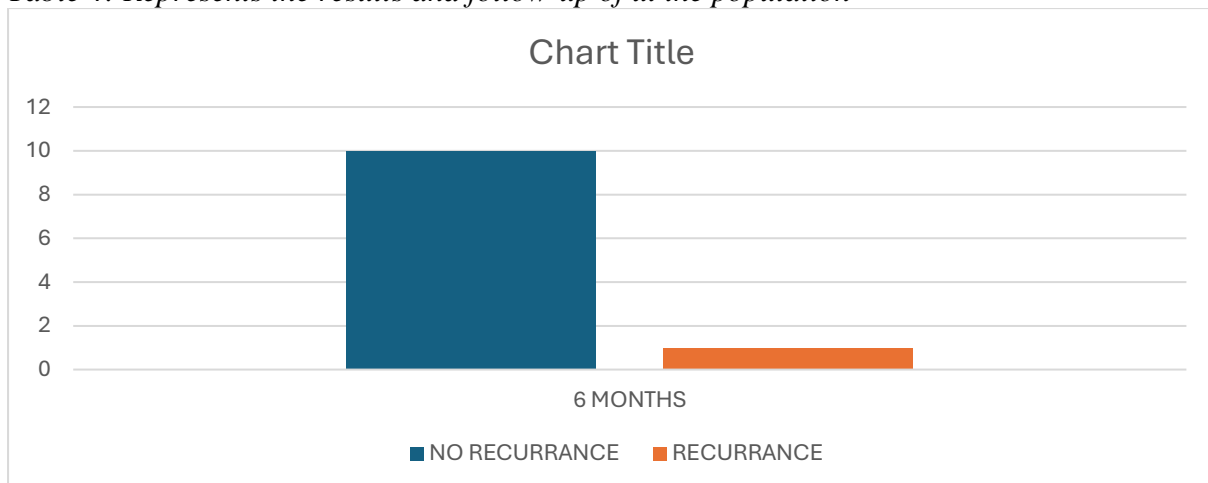
Table 3: Represents the gender distribution in the population



TAR is a complex surgical technique that involves a meticulous dissection of the abdominal wall to expose the transversus abdominis muscle and fascial tissue layers. The surgeon cuts the posterior rectus sheath longitudinally, exposing the Transverse Abdominal Muscle fibers and detaching them from the tissue. After examining the abdominal cavity, the surgeon performs a wide release of the fascial tissue on both sides and implants large uncoated standard alloplastic meshes. Finally, the hernial defect is closed, and the linea alba is restored using a running suture in the small-stitch small-bite technique.

RESULTS:

Table 4: Represents the results and follow-up of ut the population



Our observations regarding the efficacy of TAR in large ventral hernias resonate with (Baco & Mitric, 2022) focus on TAR's application in giant incisional hernias. The favourable outcomes, particularly low recurrence rates, align with their findings, reinforcing the notion that TAR is a robust technique, especially in managing challenging hernia cases. Complications post-TAR, as highlighted in (Baig et al., 2022), parallel our emphasis on meticulous complication management. Our case series provides a practical demonstration of effective protocols for mitigating surgical site infections and other complications, emphasizing the critical role of postoperative care in optimizing patient outcomes. (Baco & Mitric, 2022) comparing other open approaches for TAR offers a broader perspective on the technique. While their study delves into short-term outcomes, our case series narrows the focus to the specific challenges presented by large ventral hernias, elucidating TAR's advantages in this particular patient subgroup. (Gala et al., 2022) retrospective review (2022) of anterior and posterior component separation techniques provides a valuable reference point. Our study complements this by concentrating on large ventral hernias, contributing nuanced insights into patient characteristics and selection criteria specific to this challenging subset. (Parker et al., 2019) work on defining "loss of domain" (2019) lays the groundwork for understanding a crucial aspect of hernia repair. The term refers to the loss of abdominopelvic compartment volume and the necessity for abdominal viscera to reside (Parker et al., 2019) Our discussion incorporates this foundational knowledge, emphasizing the relevance of addressing the loss of domain in large ventral hernias and its implications for the application of TAR. (Rabie et al., 2022) randomized controlled trial (2022) comparing posterior component separation with TAR versus mesh-only repair is a notable reference, aligning with our study's focus on evidence-based approaches. Both studies collectively contribute to guiding future research endeavors, offering potential pathways for refining surgical techniques and optimizing outcomes in complex ventral hernia cases.

DISCUSSION

The central theme of large ventral hernia /Incisional hernia repair is midline re-approximation of the autologous tissue with physiologic tension and proper mesh reinforcement to reduce the risk of recurrence Classic Retro rectus repair is a surgical technique that was developed by Jean Rives and Rene Stoppa in 1960 for the repair of open ventral hernias. This technique involves the placement of a prosthetic mesh within the retro rectus space, which is highly vascular, and a two-layer fascia closure to ensure a stable repair. The mesh can extend up to 6-8 cm on each side of the midline, providing a large surface area for tissue ingrowth and support. This technique has proven to be highly effective over time, but it is also technically demanding and requires a skilled surgeon to perform. However, in some cases, the extent of the hernia defect may exceed the capabilities of Stoppa's repair alone, making it insufficient for achieving a tension-free midline approximation. In such cases, alternative surgical techniques may need to be considered. For large gaps in the abdominal wall where the rectus muscles need to be brought together, a method called component separation can be used. The most commonly used technique is the anterior or external oblique release, which was first described by Ramirez in 1990. The procedure involves lifting the skin and cutting through the external oblique aponeurosis lateral to the rectus sheath. This allows the muscles to be advanced myofascially by 8-10 cm at the waist and 3-5 cm in the upper and lower abdomen. An additional 2 cm can be achieved by elevating the rectus muscle from the posterior rectus sheath. Multiple variations of components have been described, but one gaining immense popularity over the past few years is TAR (Transversus abdominis release) described by (Novitsky et al., 2012), which has advantages over the traditional anterior release 1. avoidance of large subcutaneous flaps (leading to wound morbidity-seroma, abscess, skin necrosis). 2. Creating Recto rectus space for mesh placement which isolates the prosthesis from the viscera and dissection between Transverse abdominis and Transversalis fascia allows large mesh to be utilised. The present approach has the potential to effectively restore the native biomechanics of the abdominal wall.

Over the long term, transversus abdominis release (TAR) has been demonstrated to be a versatile, reliable, and durable surgical technique that boasts a low recurrence rate. Its efficacy in abdominal wall reconstruction is widely acknowledged in the medical community, making it a preferred choice for treating complex abdominal wall defects. The use of the TAR technique should be considered in cases where the native biomechanics of the abdominal wall need to be restored, as it has proven to be a successful therapeutic option.

CONCLUSION

Our case series, in conjunction with the referenced studies, contributes to the discussion on treating large ventral hernias with TAR. The combination of clinical observations and evidence-based research demonstrates the consistency of findings across studies, providing a strong foundation for advancing the field of hernia repair. This collaborative effort between clinical experience and scientific inquiry is essential for refining surgical strategies and improving outcomes for patients with complex ventral hernias. The Transverse Abdominis Release (TAR) technique is a specialized form of the component separation method, which complements the traditional retromuscular repair of Rives Stoppa. TAR has been demonstrated to have minimal perioperative morbidity, a reduced incidence of wound-related complications, and a low rate of recurrence. The use of posterior component separation via TAR has proven to be a dependable and effective strategy for repairing ventral hernias, offering a promising addition to the arsenal of surgeons engaged in complex abdominal wall reconstructions.

REFERENCES

- Baco, S., & Mitric, M. (2022). Transversus Abdominis Muscle Release in Giant Incisional Hernia. *Cureus*. <https://doi.org/10.7759/cureus.28277>
- Baig, S. J., Afaque, M. Y., & Priya, P. (2022). Surgical Site Infection After Transversus Abdominis Release: A Review. *Indian Journal of Surgery*. <https://doi.org/10.1007/s12262-022-03413-4>
- Gala, J., Nichat, P., Bhandarwar, A., Dhimole, N., Bhat, R., & Muley, G. (2022). Single institute experiences in anterior and posterior component separation technique for the large ventral hernia: A retrospective review. *Asian Journal of Surgery*, 45(3), 854–859. <https://doi.org/10.1016/j.asjsur.2021.07.042>
- Novitsky, Y. W., Elliott, H. L., Orenstein, S. B., & Rosen, M. J. (2012). Transversus abdominis muscle release: A novel approach to posterior component separation during complex abdominal wall reconstruction. *The American Journal of Surgery*, 204(5), 709–716. <https://doi.org/10.1016/j.amjsurg.2012.02.008>
- Parker, S. G., Halligan, S., Blackburn, S., Plumb, A. A. O., Archer, L., Mallett, S., & Windsor, A. C. J. (2019). What Exactly is Meant by “Loss of Domain” for Ventral Hernia?

Systematic Review of Definitions. *World Journal of Surgery*, 43(2), 396–404.

<https://doi.org/10.1007/s00268-018-4783-7>

Rabie, M., Abdelnaby, M., Morshed, M., & Shalaby, M. (2022). Posterior component separation with transversus abdominis muscle release versus mesh-only repair in the treatment of complex ventral-wall hernia: A randomized controlled trial. *BMC Surgery*, 22(1), 346. <https://doi.org/10.1186/s12893-022-01794-7>