

<https://doi.org/10.48047/AFJBS.6.7.2024.2844-2847>



African Journal of Biological Sciences

Journal homepage: <http://www.afjbs.com>



Research Paper

Open Access

## CASE REPORT

### An Unusual Impaction of a tooth Mimicking Salivary Stone: A Rare Case Report

<sup>1</sup>Dr. Sudhir Rishi, <sup>2</sup>Dr. Monika Bhat, <sup>3</sup>Dr. Deepa Dubey, <sup>4</sup>Dr. Diksha Garg, <sup>5</sup>Dr. Pranjal

<sup>1</sup>Professor and Head, <sup>2</sup>Assistant Professor, <sup>3</sup>Associate Professor, <sup>4,5</sup>Intern, Department of Oral Medicine and Radiology, Adesh Institute of Dental Sciences and Research, India

**Corresponding Author:** Dr. Monika Bhat, Assistant Professor, Department of Oral Medicine and Radiology, Adesh Institute of Dental Sciences and Research, India

**Email:** [monikabhat6433@gmail.com](mailto:monikabhat6433@gmail.com)

ArticleHistory  
Volume:6,Issue7,2024  
Received:30May2024  
Accepted:26June2024  
doi:10.48047/AFJBS.6.7.2024.  
2844-2847

#### ABSTRACT

**Aim:** The aim of this case report is to present clinical and advanced radiographic features of an unusual impacted tooth in the floor of mouth.

**Case Report:** A 37-year-old female patient presented to our department with history of swelling that was localized in right floor of mouth. Clinically it was noticed that her all permanent teeth in the right quadrant were present. So, we first underwent for her occlusal radiography in relation to the offending region where tooth like structure was found lying horizontally with complete presentation of crown and root part. Then, we underwent for an advanced three-dimensional radiographic technique of CBCT, with the purpose of detailed assessment of tooth like structure. After complete assessment patient was advised for the removal of tooth and hence was referred to the Department of Oral Surgery to relieve the pain and the patient was followed up periodically.

**Discussion:** In cases of having a suspicious diagnosis of bony hard lesion in floor of mandible like sialoliths, mandibular tori, impacted tooth : periapical, orthopantomography or occlusal radiographs can be indicated to detect it. But the only drawback with these conventional techniques is that they being the 2-dimensional are not sufficient for determining of the exact localization and the relation with adjacent structures and extent cannot be determined. Thereby, Cone beam computed tomography that is a three-dimensional tool is proven more successful in defining the localization as in our case of retained deciduous impacted teeth.

**Conclusion:** In the diagnostic assessment of such cases cone beam computed tomography has high scope in better outcome results in managing the patients.

**Keywords:** Cone-beam computed tomography, Dentistry, Impacted teeth, Mandible, Tooth.

## INTRODUCTION

Impaction by definition is described as a tooth which is completely or partially unerupted and is positioned against another tooth, bone or soft tissue so that its further eruption is unlikely, described according to its anatomic position.<sup>1</sup> Hence, the teeth having the impactions can be associated with various causes. The sequences of impaction vary with different teeth, and studies have found third molars are the most frequently impacted teeth, followed by maxillary canines, maxillary and mandibular premolars. In oral and maxillofacial region, out of all developmental defects, tooth eruption failures are very common developmental defects in which tooth impaction in submandibular region is quite rare. We report a case of an impacted tooth bearing an unusual similarity to sialolith of the submandibular gland on routine radiographic examination.

## CASE REPORT

37-year-old female reported to our department with a chief complaint of swelling in the right side of floor of mouth. Her history of presenting illness revealed that she had a history of trauma 20 years back to her face region for which she took symptomatic treatment. Now since 6 months she started noticing swelling in the right side of floor of mandible that does not increase or decrease in size with any factor. There was no pain in this side of offending region also, there was no reduction in salivary flow according to patient as well as noted following intraoral examination. Extra orally there was no evident asymmetry, but a small swelling was perceived with palpation, at the lower border of right mandibular area. On Intra oral examination, inspectory findings revealed a localized swelling in the right floor of mandible which was oval in shape, measuring about 2x2cm in size. On palpation it was found that swelling was hard, tender with no evidence of discharge present.

The patient gave no history of systemic disease, and there were no abnormal findings on general physical examination. Based on the history and clinical findings we suspected it was sialolithiasis. Thus, to confirm the diagnosis patient was sent for occlusal radiography, where well defined radiopaque mass, located on right lower premolar area was observed (Fig. 1)..and then for further investigations patient was sent for cone beam computed tomography i.r.t offending region where Sagittal view revealed: Evidence of hyperdense tooth like structure appreciated lingually in the floor of mouth measuring about 14.93 mm antero-posteriorly (fig2), 6.58 mm superior inferiorly (fig.2). Single root canal was also seen in relation to the horizontally inclined tooth like structure. It appeared to be displaced to the floor of the mandible with horizontally inclined to the lingual cortical plate. Thus from the radiographic findings a final diagnosis of impacted tooth in submandibular region was made. (Fig. 2) The patient was then operated at Oral Surgery Department under local anaesthesia and the mass was removed from submandibular region by intraoral approach. The removed mass was 12x6 mm in size of yellowish-white color with an irregular surface. Macroscopic examination revealed that the removed mass was having tooth like appearance. (Fig. 4)

## DISCUSSION

These type of unique and novel case situation, as per the available knowledge, are quite rare in the existing literature. It highlights the potential for new discoveries and the need for further research to explore and understand the use of advanced technologies. Where the present case report has discussed about the mimicking scenario for the pathology related to salivary gland as here i.r.t submandibular salivary gland. Where clinically it was presenting as salivary stone and from a radiological study of the present case it would seem unlikely that the tooth had ever been impacted in the floor of mouth where there was no possibility of either tooth being submerged in such an abnormal position. The importance of taking routine X-rays where the history of missing teeth is unknown but clinically more it was towards salivary gland pathology which is clearly illustrated by this report.

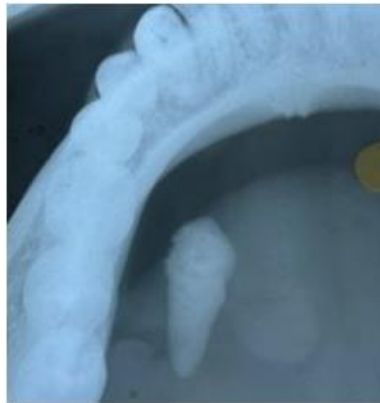Salivary calculi are usually small and measure from 1 mm to 1 cm. They rarely measure more than 1.5 cm and the mean size reported is between 6 mm and 9 mm.<sup>3</sup> In this report, clinically swelling was present in the Wharton duct region opposing the mandibular left premolar and the first molar region while the radiological features depicted a tooth like structure (Fig. 3). The shape and density of the calcified mass exactly mimicked an impacted tooth with well appreciable root canal.

Sialolithiasis usually triggers pain and swelling in the affected salivary gland by blocking the surge of saliva during meals.<sup>4</sup> These calcifications can also create a backlog of saliva, allowing bacteria to climb into the gland tissue, leading to infection, discomfort, and

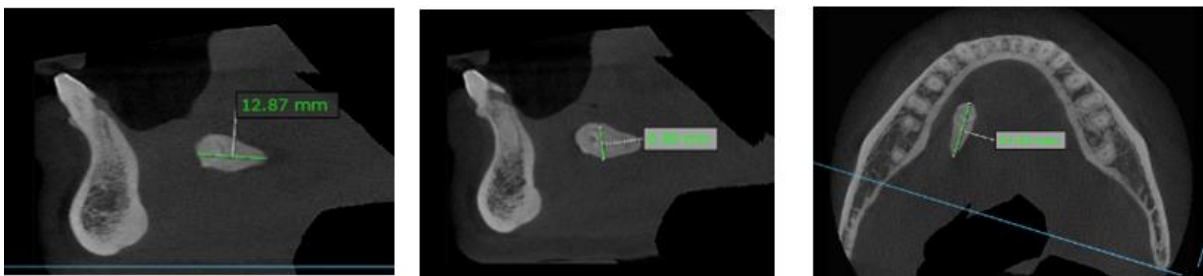
swelling.<sup>5,6</sup> However, in this case report, the patient only complained of intermittent pain without any history of significant swelling or infection.

Salivary gland calculi, or sialoliths, are intriguing yet common formations within these glands.<sup>7</sup> They form when calcium carbonate and phosphate solidify within the ducts, particularly in the submandibular gland.<sup>8</sup> Diagnosis blends clinical assessment with radiological imaging. While smaller calculi may hide on X-rays, giant sialoliths stand out on panoramic radiographs. Uncovering asymptomatic cases requires careful observation amidst overlapping structures. Occlusal radiographs serve as treasure maps, guiding clinicians through the Wharton's duct. These images reveal the size and location of these hidden treasures, enabling precise treatment strategies.<sup>9</sup>

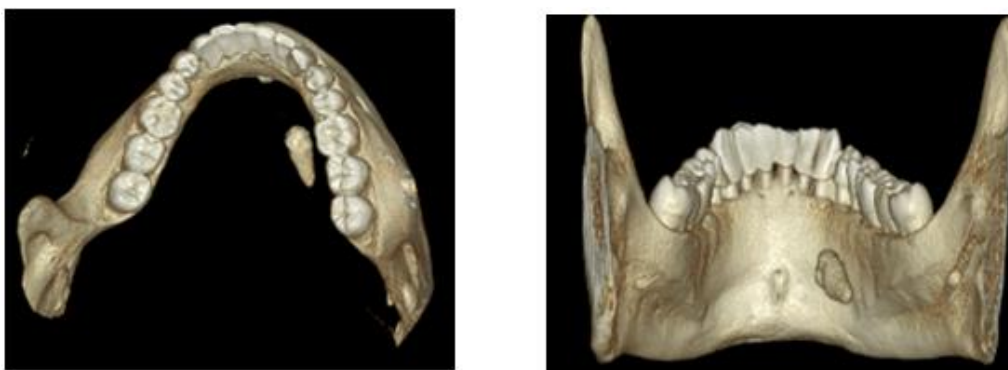
In our case, harnessing the 3-D capabilities of CBCT facilitated an accurate diagnosis, effectively differentiating the clinical diagnosis from potential alternatives. This informed a meticulously planned treatment approach, resulting in successful treatment outcomes without any postoperative complications. CBCT's transformative role in guiding precise diagnoses and treatment strategies underscores its invaluable contribution to enhancing oral healthcare standards.<sup>10</sup>



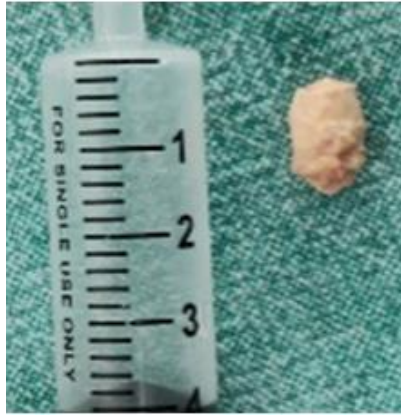**Fig. 1: Preoperative occlusal**



**Fig. 2: Preoperative Sagittal and axial CBCT sections radiography**



**Fig. 3: Preoperative 3D CBCT sections radiography**



**Fig. 4.: macroscopic image**

## CONCLUSION

Oral physicians are the superheroes of diagnosis and treatment, and this case report showcases their extraordinary skills. It emphasizes the importance of diving deep into patients' dental histories and using cutting-edge radiographic techniques, like cone-beam computed tomography (CBCT), to unveil hidden mysteries.

CBCT isn't just a tool—it's a game-changer. With its superhero-like abilities to reveal intricate details, it's like having X-ray vision to distinguish between dental and salivary gland issues. This advanced technology empowers oral physicians to deliver personalized care, tailored to each patient's unique needs, ensuring they emerge victorious against any oral health challenge.

This case report isn't just about solving a medical puzzle—it's a thrilling journey into the world of oral medicine, where innovation and expertise combine to save the day and transform lives.

## REFERENCES

1. Janakiraman EN, Alexander M, Sanjay P. Prospective analysis of frequency and contributing factors of nerve injuries following third-molar surgery. *J Craniofac Surg.* 2010; 21:784–6
2. Bjork A., Jensen E. and Palling M. (1956) Mandibular growth and third molar impaction. *Acta Odon tol. Stand.* 14, 23 1-272.
3. Ledesma-Montes C, Garcés-Ortíz M, Salcido-García JF, Hernández-Flores F, Hernández-Guerrero JC. Giant sialolith: Case report and review of the literature *J Oral Maxillofac Surg.* 2007; 65:128–30
4. Gupta A, Rattan D, Gupta R. Giant sialoliths of submandibular gland duct: Report of two cases with unusual shape. *ContempClin Dent.* 2013;4:78–80.
5. Bodner L. Giant salivary gland calculi: Diagnostic imaging and surgical management. *Oral Surg Oral Med Oral Pathol Oral RadiolEndod.* 2002;94:320–3.
6. Bhullar RS, Dhawan A, Bhullar K, Malhotra S. Giant submandibular gland duct sialolith mimicking an impacted canine tooth. *Natl J Maxillofac Surg.* 2015 Jan-Jun;6(1):89-92.
7. Rabinov K, Weber AL. Radiology of the salivary glands. Boston: GK Hall 1985:231-34.
8. Marchal F, Becker M, Dulguerov P, Lehmann W. Interventional sialendoscopy. *Laryngoscope* 2000 Feb;110(2 Pt 1):318-20.
9. Alkurt, M.T. and Peker, I., 2009. Unusually large submandibular sialoliths: report of two cases. *European journal of dentistry*, 3(02), pp.135-139.
10. Jaju PP, Jaju SP. Clinical utility of dental cone-beam computed tomography: current perspectives. *Clinical, cosmetic and investigational dentistry.* 2014 Apr 2:29-43.