

<https://doi.org/10.48047/AFJBS.7.4.2025.1452-1461>



African Journal of Biological Sciences

Journal homepage: <http://www.afjbs.com>



Research Paper

Open Access

## Prosthetic management of amelogenesis imperfecta. Case report

Islam Mohsen<sup>1</sup>, Fatma Makkeyah<sup>2\*</sup>, Farid Emad Eldin<sup>3</sup>

<sup>1</sup> A. Lecturer of Fixed Prosthodontics, The British University in Egypt, Cairo, Egypt  
<sup>1\*</sup> A. Professor of Fixed Prosthodontics, The British University in Egypt, Cairo, Egypt  
<sup>1</sup> Lecturer of Fixed Prosthodontics, The British University in Egypt, Cairo, Egypt

Corresponding author: Fatma Makkeyah e.mail: [fatma.makkeyah@bue.edu.eg](mailto:fatma.makkeyah@bue.edu.eg)

Volume 7, Issue 4, Apr 2025

Received: 15 Feb 2025

Accepted: 05 Mar 2025

Published: 05 Apr 2025

[doi:10.48047/AFJBS.7.4.2025.1452-1461](https://doi.org/10.48047/AFJBS.7.4.2025.1452-1461)

### Abstract

Amelogenesis imperfecta has been described as a complex group of inherited conditions that disturb the developing enamel structure and exist independent of any related systemic disorder. It is a rare dental disease that represents a great restorative challenge for dentists. This clinical case report describes the oral rehabilitation of an adult male patient diagnosed with hypoplastic amelogenesis imperfect. This challenge was corrected by gingivectomy, gingivoplasty, by achieving the desired crown length keeping in view the biological width. Fixed zirconia ceramic restorations were given to enhance the esthetics, masticatory function, eliminate the teeth sensitivity and to enhance the overall personality of the patient. Follow-up visits were scheduled at 3 months, 6 months and 1 year. No esthetic or functional problems were seen after the follow-up period. The goal of the treatment was to achieve function, reduce sensitivity, protect enamel and improve esthetics.

**Keywords:** amelogenesis imperfecta, oral rehabilitation, ceramic crowns, esthetics

**Introduction**

Amelogenesis imperfecta (AI), a group of hereditary diseases affecting the tooth enamel in either quality or quantity, is associated with crown malformation and abnormal enamel density (Chamarthi et al., 2012).

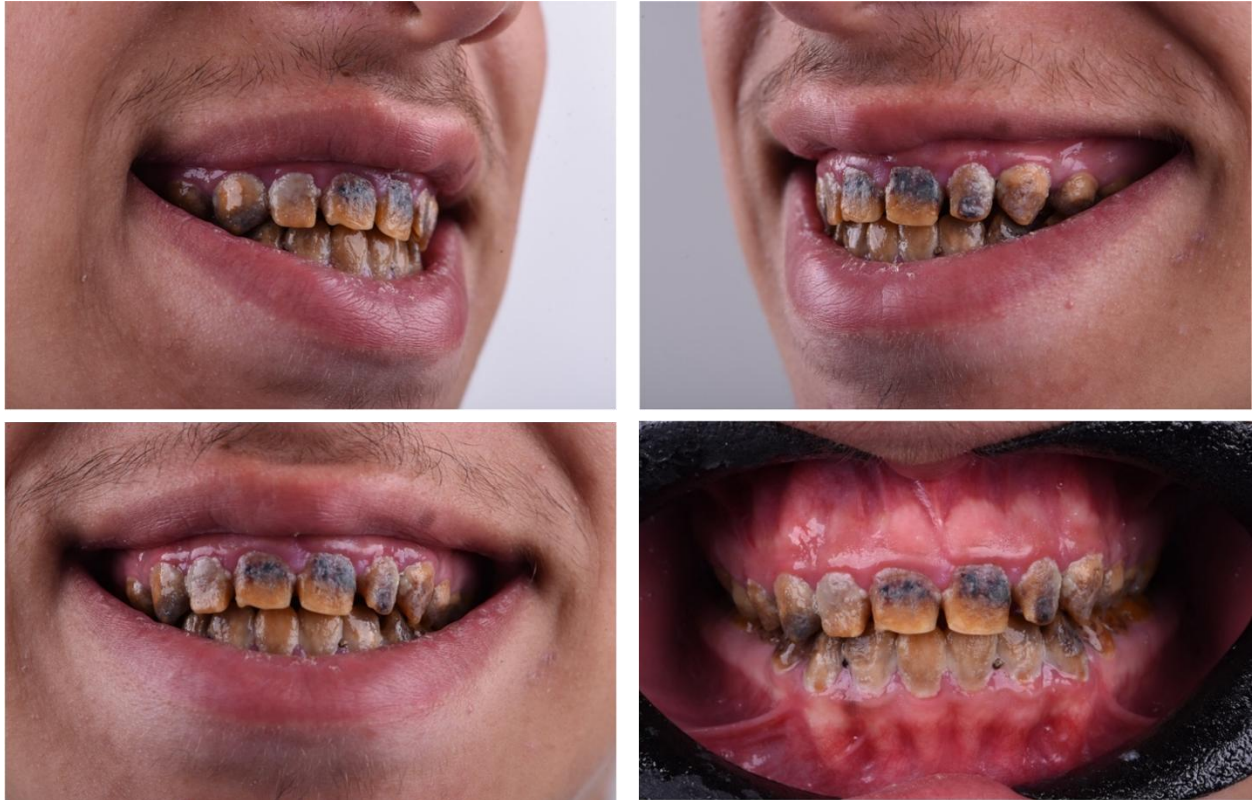Clinical features of patients with AI depend on the type of AI involved. AI has been classified based on clinical, radiographic, and histologic appearance of the enamel defect and the mode of inheritance of the trait. AI has been categorized as hypoplastic, hypocalcified, hypomaturational types and hypoplastic-hypomaturational type. Hypoplastic AI represents 60 to 73% of all cases, hypomaturational AI represents 20 to 40%, and hypocalcification AI represents 7% (Crawford et al., 2007; Herrera-Rojas and Perona-Miguel de Priego, 2023).

The presence of AI has a negative effect on health for life if not properly diagnosed and treated as it may cause accentuated sensitivity, often leading to the avoidance of foods that cause pain and a consequent change in adequate eating habits as well as altered dental esthetics, which can cause psychological distress. The purpose of this case report was to describe a case with AI and evaluate possible clinical approaches (Mohn et al., 2021).

Treating AI cases is considered a full mouth rehabilitation case that represents a challenge to the clinicians. A thorough understanding of various occlusion concepts is substantial in order to properly address the patient's complaint, reach an effective treatment plan and optimize the restorative outcomes especially when all the teeth of one or both arches are involved.

**Case report**

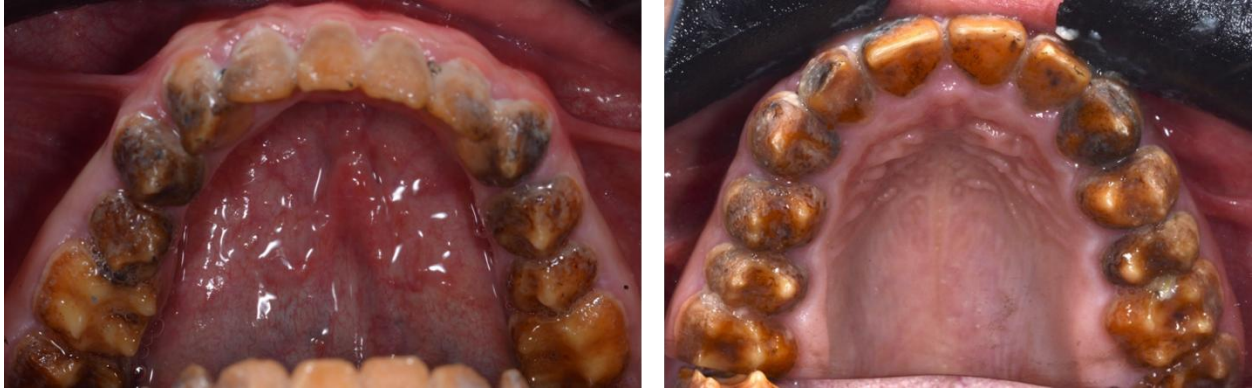A 23-year-old male patient was referred to the Fixed Prosthodontic Department, Faculty of Dentistry, The British University in Egypt, Cairo, Egypt, seeking prosthetic treatment to change his smile. Patient was a student and there was history of similar condition in the family, other family member presented with similar dental findings. The patient's chief complaint was bad esthetic appearance. Preoperative facial and lateral views of the patient with full smile are shown in (Figure 1). The patient's medical history was noncontributory.



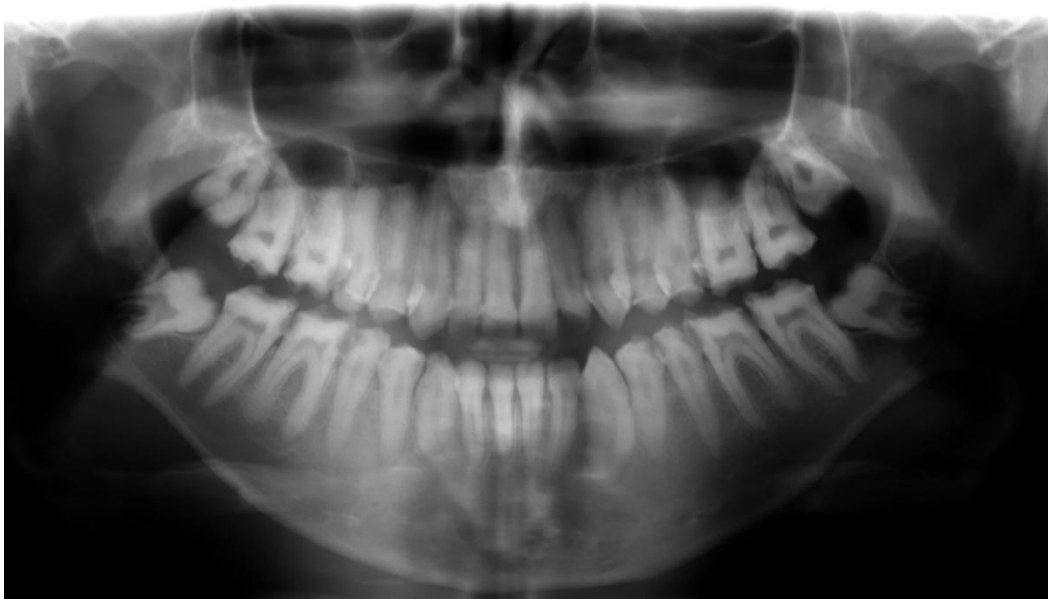**Figure 1:** Preoperative facial and lateral views of the patient with full smile

Extra-oral examination disclosed normal mouth opening and no temporomandibular joint problems. The patient was healthy with no co-morbidities.

On intraoral examination, careful clinical examination revealed poor oral hygiene with gingival inflammation and calculus depositions on all teeth, multiple decayed teeth with normal size clinical crowns and contact with adjacent teeth, but the mottled, brownish-yellow enamel was soft and has a radiodensity similar to dentin. Also, the lack of prosthetic space to restore the mandibular and maxillary molars was evident. Panoramic radiograph revealed the presence of complete dentition with caries in almost all teeth (Figures 2 & 3).



*Figure 2: Intraoral view showing mottled, brownish-yellow enamel*



*Figure 3: Panoramic radiograph*

Based on clinical and radiological examination, it was diagnosed as hypoplastic type of amelogenesis imperfecta. Based on the diagnosis, a full mouth rehabilitation was planned. A well formulated treatment plan involving endodontic, and prosthetic procedures was charted out to furnish a functional occlusion with good esthetics and further prevent tooth loss. The entire treatment plan was explained to the patient and informed consent was obtained.

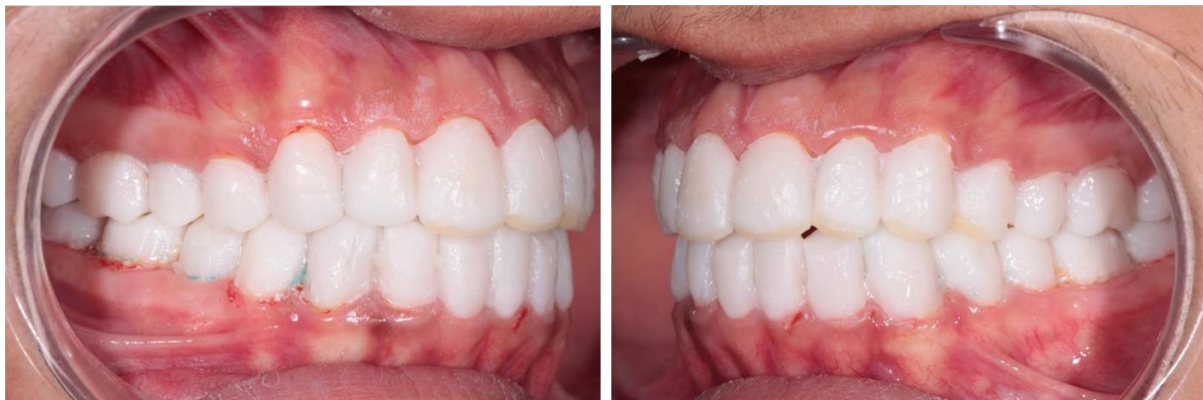Steps of performed treatment

- 1- Patient examination and diagnosis
- 2- Scaling and oral hygiene measures
- 3- Crown lengthening of all posterior quadrants
- 4- Endodontic treatment of all maxillary & mandibular teeth except upper & lower 6,7 teeth in right side.

- 5- Primary impressions, centric relation occlusal records for mounting of casts on semi adjustable articulator and assessment of the vertical dimension of occlusion (VDO) to be used in the future rehabilitation
- 6- Diagnostic waxing of the planned prosthesis for visualization of treatment plan, planning types of restorations and adjusting esthetics and occlusion
- 7- Mock-up fabrication with intraoral adjustment of esthetics and occlusion
- 8- Scanning of functional wax up after examination with the final adjusted occlusion then scanning of all prepared maxillary & mandibular teeth
- 9- Functional temporary stage: Follow-up sessions for phonetic tests and check the presence of muscle pain and temporomandibular joint discomfort
- 10- Fabrication of the definitive restorations
- 11- One year follow-up session

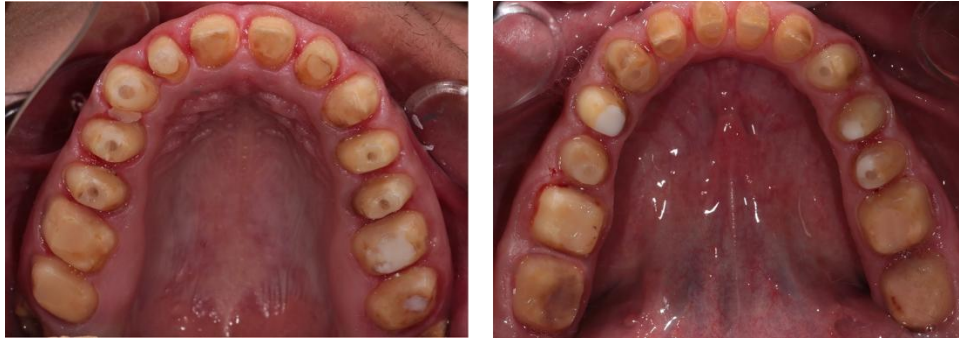The mock-up shown in (Figure 4) was used as functional provisional restoration for one month with follow-up appointments twice per week to evaluate phonetics and check for presence of muscle pain and temporomandibular joint (TMJ) discomfort. No symptoms of abnormal muscle activity were found and the phonetic test revealed normal characteristics.

This was followed by guided preparations of the teeth through the mock-ups. This technique of guided preparations helps determining the proper type of restoration and amount of coverage that provides the required function without unnecessary preparation.



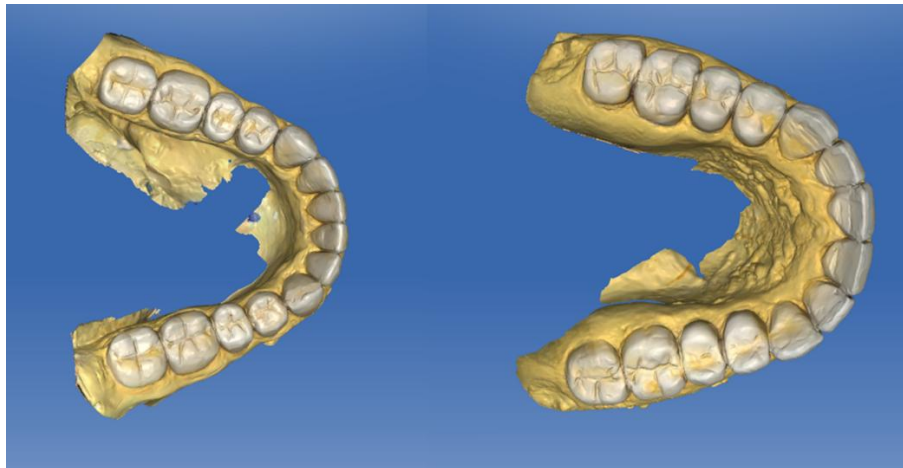
**Figure 4:** Mock-up

All teeth were prepared to receive full coverage crowns (Figure 5).

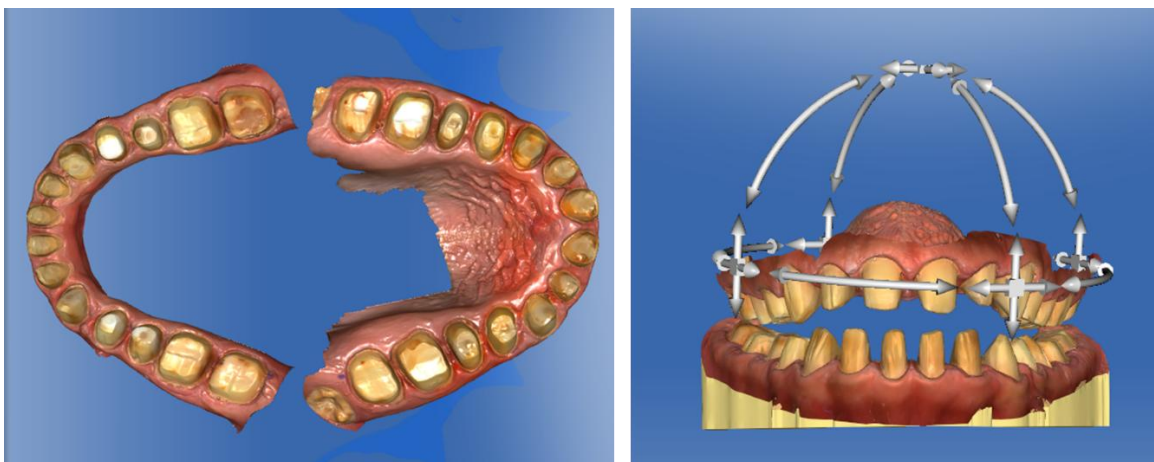


*Figure 5: Preparation of upper and lower arches*

Digital impressions (Figures 6 & 7) were taken using omniscam scanner (sirona), followed by the fabrication of provisional restorations with temporary crown material (Structure 3, VOCO GmbH, Cuxhaven, Germany) by an index of the diagnostic wax-up created in three sections: two posterior sections from molar to first premolar, and an anterior section from canine to canine.



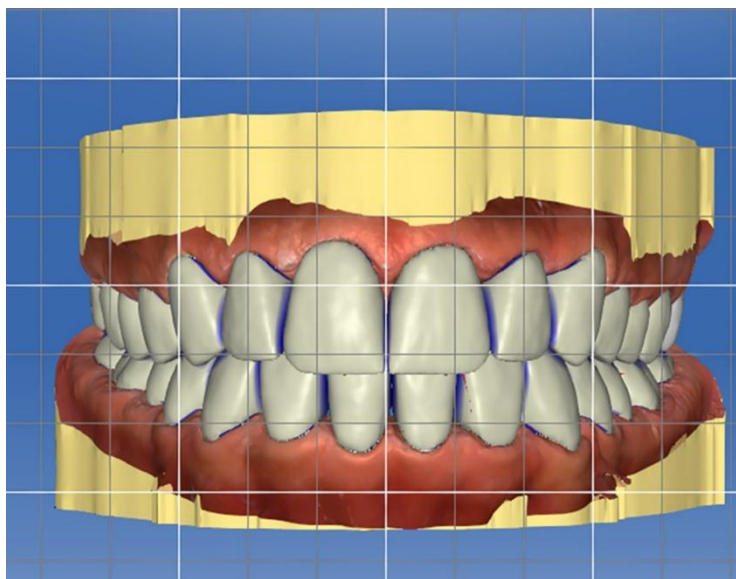
*Figure 6: Digital impression of mock-up in place*



*Figure 7: Digital impression of prepared teeth*

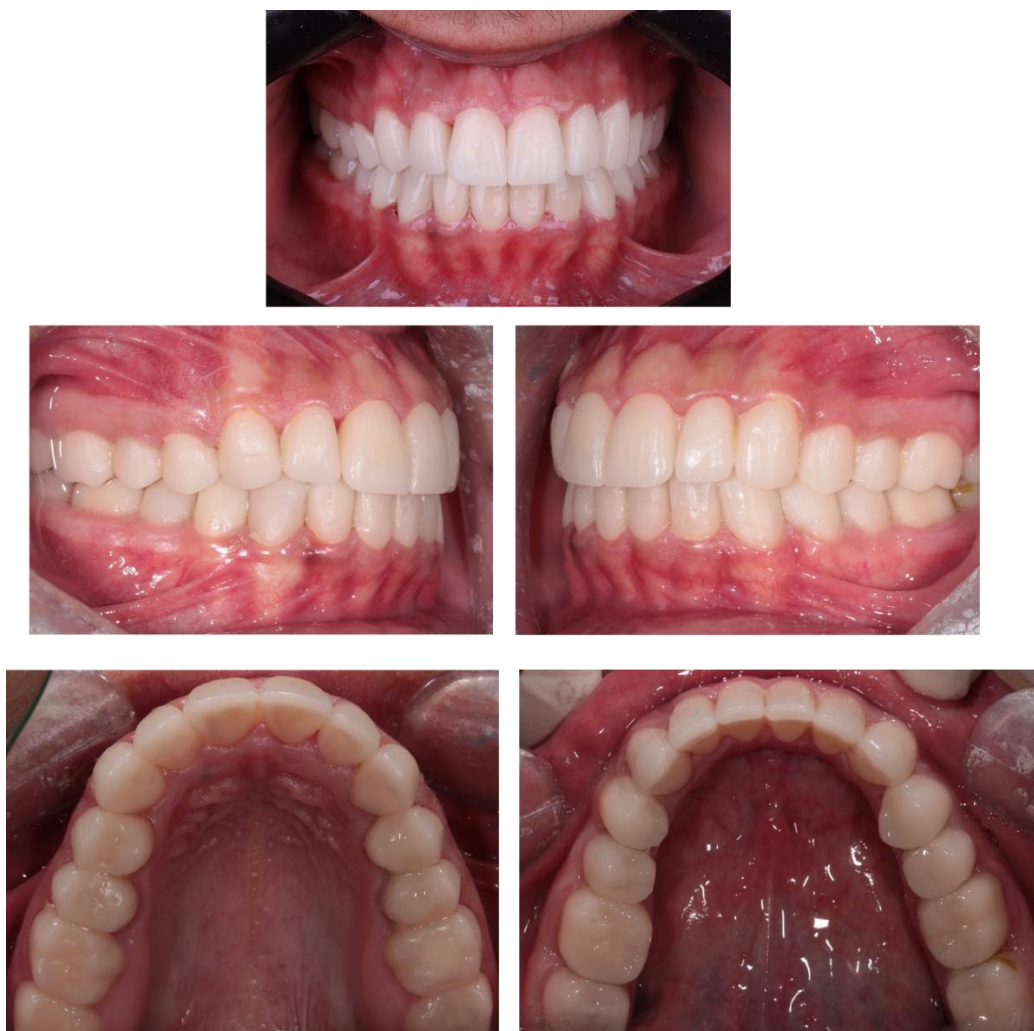All maxillary and mandibular teeth were prepared to receive full contour zirconia crowns, upper anterior teeth to adjust anterior guidance and improve esthetics, posterior teeth to adjust vertical dimension of occlusion.

All zirconia crowns were designed using cerec software (Sirona ) and milled by MCX5 (milling machine ) from BruxZir full contour zirconia blanks (BruxZir, Glidewell laboratories, California, USA) (Figure 8).



**Figure 8:** *Designing using cerec software*

Finally, the restorations were tried and evaluated for esthetics, occlusion, and phonetics followed by definitive delivery stage. Proper isolation, surface treatments of the restorations by sandblasting then using Z prime, surface treatments of teeth and cementation were performed using resin cement (G-Cem capsules, GC corporation , Tokyo,Japan ) (Figure 9). The same occlusal scheme established in the provisional rehabilitation was followed in the final prosthetic restoration. Follow-up of the restorations and surrounding tissues was done every two months for a year, and during the one-year follow-up session, there were no clinical symptoms or signs of temporomandibular disorder, no signs of recurrent caries around the restorations, and no debonding. The patient expressed satisfaction with the significant improvement in chewing function and esthetic appearance. follow-up sessions are done.



*Figure 9: Intraoral pictures of final restorations*

## **Discussion**

Enamel is considered as the hardest and the highly mineralized tissue in the human architecture, with 85% of the volume enveloped by hydroxyapatite crystals. The physiological morphology is forthwith related to compositional microstructure, direction and orientation of enamel rods, and structural configuration of the mineral constituent of the tissue (Simmer and Fincham, 1995; Chaudhary et al., 2009). Any divergence from the normal organogenesis leads to amelogenesis imperfecta which can be manifested in the oral cavity.

Amelogenesis imperfecta is of genomic origin affecting the structural, physical and clinical appearance of the individual which can be demotivating patient's self-esteem.

Treatment planning in AI involves a comprehensive diagnosis and treatment using an interdisciplinary approach of periodontal, prosthodontic and restorative treatment.

The entire treatment plan for a patient suffering from amelogenesis imperfecta (AI) should be aimed at protecting the entire stomatognathic system and restoration of hard tissues. The final treatment modality till date still revolves around either full coverage restorations or, more of adhesive restorations (e M and Hegde, 2016).

Full mouth rehabilitation continues to be one of the most difficult challenges that clinicians face because it requires comprehensive diagnosis and systematic treatment planning to reach the best outcome that optimize function, health and esthetics. This clinical report demonstrates a systematic approach for full mouth rehabilitation to create restorative space posteriorly and restore defected teeth.

The treatment options vary considerably depending on several factors such as the age of the patient, socioeconomic status, periodontal condition, loss of tooth structure, severity of the disorder, and, most importantly, the patient's cooperation (Sari and Usumez, 2003).

There are a number of alternatives for the treatment of anterior teeth affected by AI. For many years the most predictable and durable esthetic restoration of anterior teeth has been achieved with complete crowns (Peumans et al. 2000). Several authors prefer full porcelain restorations as the treatment modality of their patient with AI (Gokce et al., 2007; Siadat et al., 2007). However, the advances in the field of esthetic dentistry, especially in bonding to dentin, help practitioners restore function and aesthetics to an acceptable level (Izgi et al. 2015; Roma et al. 2021). Nevertheless, marginal adaptation and bonding problems have been pointed out as disadvantages of laminate veneers (Ozturk et al., 2004).

In the present case, full-mouth zirconia restorations were preferred to redouble the mechanical durability, recover aesthetics and protect the residual dentin. The clinician has to consider the long-term prognosis of the treatment outcome.

### **Conclusion**

Dental esthetics has a significant impact on patients' psychological health and self-perception. AI patients usually experience oral, social, and psychological difficulties and express feelings of embarrassment and shame. Multidisciplinary work is essential in such cases to manage all the problems related to this condition. For patients with AI to have the best treatment results, dentists and dental labs must effectively communicate and coordinate care.

**Reference:**

- Chamarthi, V., B. R. Varma and M. Jayanthi (2012). "Amelogenesis imperfecta: a clinician's challenge." J Indian Soc Pedod Prev Dent **30**(1): 70-73.
- Chaudhary, M., S. Dixit, A. Singh and S. Kunte (2009). "Amelogenesis imperfecta: Report of a case and review of literature." J Oral Maxillofac Pathol **13**(2): 70-77.
- Crawford, P. J., M. Aldred and A. Bloch-Zupan (2007). "Amelogenesis imperfecta." Orphanet J Rare Dis **2**: 17.
- e M, R. and S. Hegde (2016). "Amelogenesis Imperfecta: A Review of the Literature." J. Pharm. Sci. & Res. **8**: 1042-1044.
- Gokce, K., C. Canpolat and E. Ozel (2007). "Restoring Function and Esthetics in a Patient with Amelogenesis Imperfecta: A Case Report." The journal of contemporary dental practice **8**: 95-101.
- Herrera-Rojas, N. A. and G. A. Perona-Miguel de Priego (2023). "Amelogenesis imperfecta. case report." Rev Cient Odontol (Lima) **11**(2): e156.
- Izgi, A. D., E. Kale and R. Nigiz (2015). "Amelogenesis Imperfecta: Rehabilitation and Brainstorming on the Treatment Outcome after the First Year." Case Rep Dent **2015**: 579169.
- Mohn, M., J. C. Bulski, N. Kramer, A. Rahman and N. Schulz-Weidner (2021). "Management of Amelogenesis Imperfecta in Childhood: Two Case Reports." Int J Environ Res Public Health **18**(13).
- Ozturk, N., Z. Sarı and B. Ozturk (2004). "An interdisciplinary approach for restoring function and esthetics in a patient with amelogenesis imperfecta and malocclusion: a clinical report." The Journal of Prosthetic Dentistry **92**(2): 112-115.
- Peumans, M., B. Van Meerbeek, P. Lambrechts and G. Vanherle (2000). "Porcelain veneers: a review of the literature." J Dent **28**(3): 163-177.
- Roma, M., P. Hegde, M. Durga Nandhini and S. Hegde (2021). "Management guidelines for amelogenesis imperfecta: a case report and review of the literature." J Med Case Rep **15**(1): 67.
- Sari, T. and A. Usumez (2003). "Restoring function and esthetics in a patient with amelogenesis imperfecta: a clinical report." J Prosthet Dent **90**(6): 522-525.
- Siadat, H., M. Alikhasi and A. Mirfazaelian (2007). "Rehabilitation of a patient with amelogenesis imperfecta using all-ceramic crowns: a clinical report." J Prosthet Dent **98**(2): 85-88.
- Simmer, J. P. and A. G. Fincham (1995). "Molecular mechanisms of dental enamel formation." Crit Rev Oral Biol Med **6**(2): 84-108.