



## COMPARATIVE EVALUATION OF PHOTODYNAMIC THERAPY AS AN ADJUNCT TO SURGICAL PERIODONTAL TREATMENT APPROACH IN STAGE II OR III WITH GRADE B OR C PERIODONTITIS – A CLINICAL STUDY

Dr.Arru Khajuria<sup>1</sup>, Dr.Sehraj Chhina<sup>2</sup>, Dr.Harleen Kaur<sup>3</sup>, Dr.Navneet Kaur<sup>4</sup>,  
Dr.Gurpreet Kaur<sup>5</sup>

1. PG student, Department of Periodontics & Oral Implantology, National Dental College & Hospital, Derabassi, Punjab  
Email-id: [arrukhajuria@gmail.com](mailto:arrukhajuria@gmail.com)
2. BDS, Department of Periodontics & Oral Implantology, National Dental College & Hospital, Derabassi, Punjab. [sehrajchhina21@gmail.com](mailto:sehrajchhina21@gmail.com)
3. PG student, Department of Periodontics & Oral Implantology, National Dental College & Hospital, Derabassi, Punjab. [harleenkaur0515@gmail.com](mailto:harleenkaur0515@gmail.com)
4. Reader, Department of Periodontics & Oral Implantology, National Dental College & Hospital, Derabassi, Punjab. [kaurparneet1963@gmail.com](mailto:kaurparneet1963@gmail.com)
5. Professor & HOD, Department of Periodontics & Oral Implantology, National Dental College & Hospital, Derabassi, Punjab. [gurpreet.nenu@googlemail.com](mailto:gurpreet.nenu@googlemail.com)

**Corresponding Author:** Dr. Navneet Kaur, Reader, Department of Periodontics & Oral Implantology, National Dental College & Hospital, Derabassi, Punjab  
Email: [kaurparneet1963@gmail.com](mailto:kaurparneet1963@gmail.com)

### Article History

Volume 6, Issue 12, 2024

Received: 02 Jun 2024

Accepted: 25 Jun 2024

doi:

[10.48047/AFJBS.6.12.2024.3751-3757](https://doi.org/10.48047/AFJBS.6.12.2024.3751-3757)

### ABSTRACT

**BACKGROUND:** Periodontal therapy aims to eliminate the etiological factors which plays a primary role in the initiation and progression of disease. Photodynamic therapy is an advanced technique which involves three components; photosensitizer agent (Indocyanine green dye), source of light (LASER) and oxygen.

**AIM:** To compare the efficacy of surgical periodontal therapy with PDT versus surgical periodontal therapy alone.

**MATERIALS AND METHODS:** 5 participants with Stage II or III, with Grade B or C periodontitis with PPD  $\geq$ 5 mm on mandibular anterior teeth, were randomly assigned to surgical periodontal therapy (Group 1) and photodynamic therapy assisted surgery (Group 2). PI, GI, PPD, and CAL were measured using UNC-15 probe at baseline and 3 months.

**RESULTS:** The intra group comparison of all the clinical parameters between 2 study groups were found to be non-significant. Only the intra group comparison of mean GI scores were found to be statistically significant in PTAS group. The inter gp comparison of all the clinical parameters at baseline and after 3 months were found to be significant for PTAS group.

**CONCLUSION:** The adjunctive use of PDT to surgical periodontal treatment is a clinical option for

significant improvement in clinical parameters in periodontitis cases.  
**KEY WORDS:** Stage II with Grade B Periodontitis, PDT, ICG dye, Diode LASER.

## INTRODUCTION:

Periodontitis is a polymicrobial, polygenetic and multi factorial inflammatory disease of the periodontium.<sup>1</sup> It is characterized by destruction of attachment apparatus including alveolar bone loss.<sup>2,3,4,5</sup>

The results of periodontal therapy aims to reduce and eliminate etiological factors particularly themicrobial causative factors. The gold standard treatment includes Phase I therapy and Phase II therapy. Non-surgical periodontal therapy i.e. SRP is indicated mostly in cases of shallow pockets. However, the deep pockets can be treated with Phase II therapy i.e. Surgical periodontal therapy followed by regenerative procedures in cases of intra bony defects. Therefore, the surgical intervention may be considered as the best treatment option by the clinicians to improve the periodontal status in cases of deep probing depth<sup>3,7,8</sup>. Phase II therapy provides promising results in long-term PPD reduction, CAL gain.

Photodynamic therapy was first introduced with concept of antimicrobial therapy which may inactivate or destroy cells and microorganisms. Diode laser can be used along with conventional surgical therapy and provides additional benefits particularly in terms of healing<sup>12</sup>. Diode laser with a wavelength of 650-980nm and anontoxic photosensitizer dye provides bactericidal effects<sup>13</sup>. The mechanism of photodynamic therapy involves the generation of reactive oxygen species which may react or cause damage to the membrane results in the death of micro-organisms<sup>14</sup>.

In the present study, Indocyanine green is used as a photosensitizer dye which is water-soluble tri carbocyanine dye belonging to a family of cyanine dyes. It can produce a powerful photosensitized cellular damage with 800-810 nm range of wavelengths. It exhibits strong absorption with peak at around 700nm. The introduction of indocyanine green as photosensitizer dye results in significant reduction of periodontal pathogens.

**MATERIAL AND METHODOLOGY:** 5 patients with PPD  $\geq$  5mm in mandibular anterior teeth with Stage III or IV with Grade B or C periodontitis were selected from the OPD services, Department of Periodontology and Oral Implantology. Each subject will be given a detailed description of study and a consent form was signed prior to commencement of the study.

## INCLUSION CRITERIA

Patients with 25-50 years. Patients with interproximal attachment loss in mandibular anterior teeth with PPD of  $\geq$  5mm. Systemically healthy patients with no known allergy. No surgical periodontal intervention for the past 6 months.

## EXCLUSION CRITERIA

Subgingival periodontal therapy or antibiotic therapy for last 6 months. Individuals with any recognized systemic illnesses. Smoking and alcohol. Pregnant and lactating females.

## METHODOLOGY:

5 patients were randomly selected to participate in the study. Phase I therapy i.e. complete SRP was performed in all the patients. After phase I therapy, patients who were suffering from Stage II or III with Grade B or C periodontitis with probing pocket depth of  $\geq$  5mm were selected. This study was a split mouth study.

**GROUP I (Surgical periodontal therapy group):** Received SPT alone. (Figure 1 and 2)

**GROUP II (Photodynamic assisted surgery group):** Received surgical periodontal therapy with indocyanine green dye assisted PDT. (Figure 3-5)

**Group I(Surgical periodontal therapy group):**

Crevicular and Interdental incision were given and flap was reflected. After elevation of the flap mechanical debridement was performed with Gracey’s curette for the removal of granulation tissue followed by thorough root planning. 3-0 non resorbable silk sutures were given for re approximation of flap. A periodontal dressing was applied to cover the surgical site and was removed after 7 days.

**Group II(Photodynamic assisted surgery group):**

Crevicular and Interdental incision were given and flap was reflected. After elevation of the flap, mechanical debridement was performed with Gracey’s curette for the removal of granulation tissue followed by thorough root planning. Indocyanine green dye was injected with 2 ml syringe on the photodynamic therapy assisted site. Diode laser was activated with a wavelength of 940nm with a continuous wave frequency and a power of 1 watt with 200µm fibre tip for 20-30 seconds and irrigation was done.

3-0 non resorbable silk sutures were given for re approximation of flap. A periodontal dressing was applied to cover the surgical site and was removed after 7 days.

**ASSESSMENT OF CLINICAL PARAMETERS**

Probing pocket depth (PPD) using UNC 15 periodontal probe, Clinical attachment loss (CAL) using customised acrylic stent, PI Sillness and Loe 1964 and GI Loe and Sillness 1963 were recorded at baseline and 3 months (Table 1)

**RESULTS**

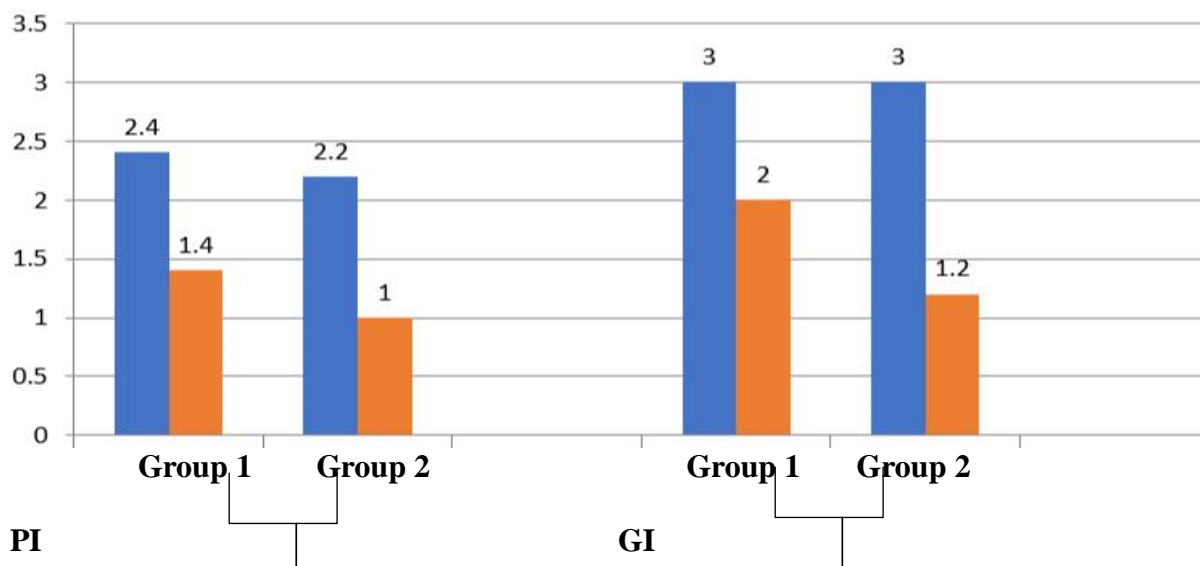
**Statistical analysis**

**Table 1: Intragroup comparison of all the clinical parameters between group 1 and group2**

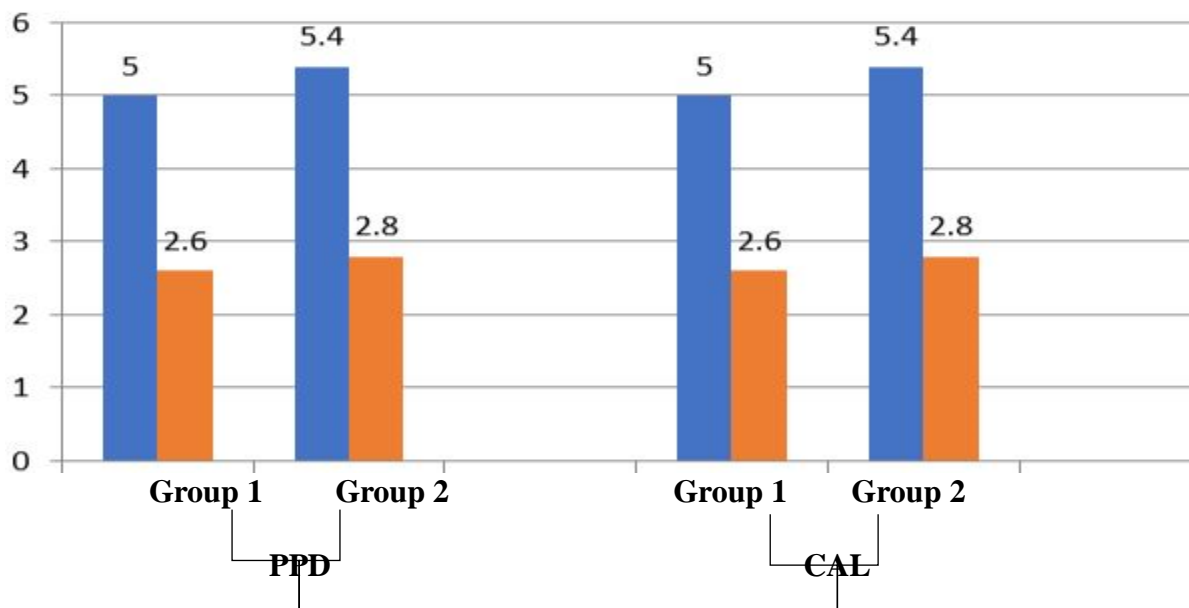
Clinical parameters	Group 1 (Surgical Therapy Group)		Group 2 (Photodynamic Assisted Surgery Group)		P value
	Baseline	3 months	Baseline	3 months	
Plaque index	2.40±0.54	1.40±0.54	2.20±0.44	1.00±0.01	0.145*
Gingival index	3.00±0.01	2.00±0.01	3.00±0.01	1.20±0.44	0.001**
PPD	5.00±0.01	2.60±0.54	5.40±0.54	2.80±0.83	1.000*
CAL	5.00±0.01	2.60±0.54	5.40±0.54	2.80±0.83	1.000*

P < 0.05 indicates SS\*\*; P > 0.05 NS\*

Paired t test at p value less than 0.05 is significant



**Graph 1: Intergroup comparison of plaque index and gingival index between group 1 (Surgical periodontal therapy group) and group 2 (PTAS group)**



**Graph 2: Intergroup comparison of PPD and CAL between group 1 (Surgical periodontal therapy group) and group 2 (PTAS group)**

**Table 2: Intergroup comparison between group 1 and group 2 at Baseline and after 3 months**

Clinical parameters	Group 1 (Surgical Periodontal Therapy Group)		P value	Group 2 (Photodynamic Assisted Surgery Group)		P value
	Baseline	3 months		Baseline	3 months	
Plaque index	2.40±0.54	1.40±0.54	0.001**	2.20±0.44	1.00±0.01	0.001**
Gingival index	3.00±0.01	2.00±0.01	0.001**	3.00±0.01	1.20±0.44	0.001**
PPD	5.00±0.01	2.60±0.54	0.001**	5.40±0.54	2.80±0.83	0.001**
CAL	5.00±0.01	2.60±0.54	0.001**	5.40±0.54	2.80±0.83	0.001**

P < 0.05 indicates SS\*\*; P > 0.05 NS\*

Student t test at p value less than 0.05 is significant

**DISCUSSION:**

Complete removal of etiological factors is difficult with phase I therapy i.e., SRP alone.<sup>17</sup> After phase I therapy, surgical intervention is indicated in sites having critical probing pocket depth of greater than 5mm. Presence of residual pocket and calculus are the predictive risk factors for the disease progression as well as clinical attachment loss.

Lasers result in enhancing the clinical outcome particularly in terms of healing the periodontal tissues.<sup>18</sup> Photodynamic therapy results in significant reduction of periodontal pathogens particularly red complex and green complex bacteris.<sup>15</sup>

There is insufficient data in the literature to evaluate the efficiency of PDT in the surgical management of periodontitis. The findings of the current study also showed that over the surgical periodontal therapy group, the PTAS group with a single application of PDT resulted in clinical differences in PPD values, gain in CAL, reduction in PI, and GI with significant differences between the groups. (Graph 1-2)

The adjunctive use of PDT provides advantages as it can easily irradiate the inaccessible areas. With conventional therapy there are chances of increased bacterial resistance to antibiotics, whereas PDT is highly unlikely to cause bacterial resistance. PDT mainly cause damage to the cytoplasmic membrane and DNA because of photo destruction. An investigation conducted in 2016 by Abbas Monzavi found that the use of indocyanine green as a photosensitizer in the treatment of chronic periodontitis dramatically decreased clinical indices such as GI and PPD.<sup>20</sup>(Table 2)

The significant reduction in the GI score in PTAS group is due to reduction of the inflammatory mediators which results in decreased inflammation and BOP. Woodruff et al. showed that the favourable effect of PDT and laser treatment on soft tissue healing would allow an increase in collagen fibre production in the region where PDT was administered.

### GROUP I SURGICAL PERIODONTAL THERAPY

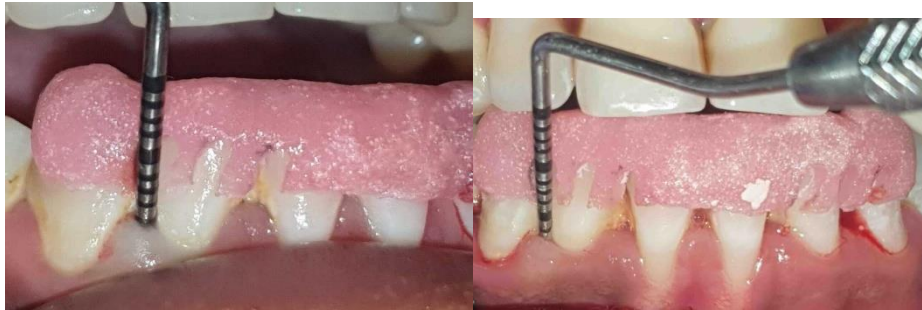

FIGURE 1

Figure 1: PPD measured at baseline w r t 42

FIGURE 2

Figure 2: PPD measured after 3 months w r t 42

### GROUP II PHOTODYNAMIC THERAPY ASSISTED SURGERY

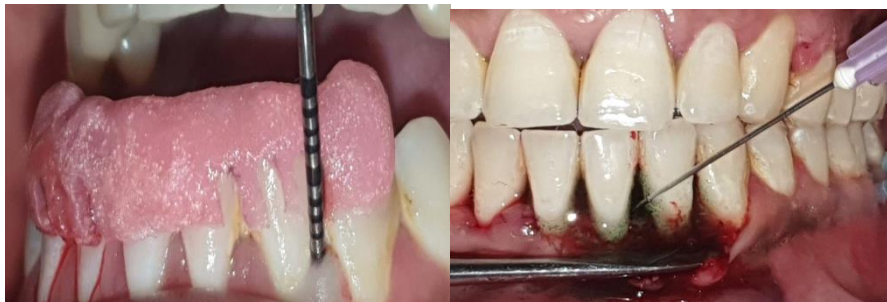

FIGURE 3

Figure 3: PPD measured at baseline w r t 32

FIGURE 4

Figure 4: ICG dye application with cannula

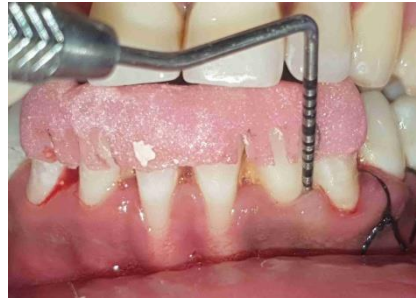

FIGURE 5

Figure 5: PPD measured after 3 months wrt 32

### CONCLUSION:

Given the study's limitations, that individuals with periodontitis can benefit from the successful use of both LASER and PDT. PPD and GI score were two clinical parameters where PDT demonstrated improvement. In the future, more research should be done to corroborate the results on the optimization of laser settings and treatment frequency in larger sample sizes. To assess the outcome in a more predictive manner, the microbiological examination of inflammatory markers and periodontal infections should be carried out.

### REFERENCES:

1. Papapanou PN et al. Periodontitis: Consensus report of workgroup 2 of the 2017 World Workshop on the Classification of Periodontal and Peri-Implant Diseases and Conditions. *J Periodontol* 2018; 89:173-182.
2. Mailoa J et al. Long-Term Effect of Four Surgical Periodontal Therapies and One Non-Surgical Therapy: A Systematic Review and Meta-Analysis. *J Periodontol* 2015;86: 1150-1158.
3. Heitz Mayfield LJA, Lang NP. Surgical and non-surgical periodontal therapy. *Periodontol* 2000 2013; 62: 218-231.
4. Vander Weijden GA, Timmerman FA. A systematic review on the clinical efficacy of subgingival debridement in the treatment of chronic periodontitis. *J Clin Periodontol* 2002;29: 55-71.
5. Philstrom BL et al. Comparison of surgical and non-surgical treatment of periodontal disease. A review of current studies and additional results after 6.5 years. *J Clin Periodontol* 1983;10(5): 524-541).
6. Ramford SP et al. 4 modalities of periodontal treatment compared over 5 years. *J Clin Periodontol* 1987;14(8): 445-452.
7. Kaldahl WB et al. Evaluation of four modalities of periodontal therapy. Mean probing depth, probing attachment level and recession changes. *J Periodontol*. 1988;59(12): 783-793.
8. Lindhe J et al. "Critical probing depth" in periodontal therapy. *J Clin Periodontol* 1982;9(4): 323-336.
9. Ishikawa I et al. Application of lasers in periodontics: true innovation or myth? *Periodontol* 2000 2009;50: 90-126.
10. Wilson M. Bactericidal effect of laser light and its potential use in the treatment of plaque related disease. *Int Dental J* 1994;44: 181-189.
11. Moan J, Berg K. The photodegradation of porphyrins in cells can be used to estimate the lifetime of singlet oxygen. *PhotochemPhotobiol* 1991;53(4): 549-553.

12. Harris F, Chatfield LK, Phoenix DA. Phenothiazinium based photosensitizers-photodynamic agents with a multiplicity of cellular targets and clinical applications. *Curr Drug Targets* 2005;6(5): 615-627.
13. Tobias K Boehm. Diode laser activated indocyanine green selectively kills bacteria. *J Int AcadPeriodontol* 2011;13: 1-7.
14. Chaitanya PK, Penmetsa GS, Gottumukkala SNVS, et al. Evaluation of Clinical and Microbiological Outcomes of Photodynamic Therapy-assisted Flap Surgery in Stages II and III, with Grades B and C Periodontitis: A Prospective Clinical Trial. *World J Dent* 2022;13(S-1):S66–S71.
15. Tanaka M et al. Association of oxygen tension in human periodontal pockets with gingival inflammation. *J Periodontol* 1998;10: 1127-1130.
16. Deas, D. E., Moritz, A. J., Sagun, R. S., Jr., Gruwell, S. F. & Powell, C. A. (2016) Scaling and root planing vs. conservative surgery in the treatment of chronic periodontitis. *Periodontol* 2000 71, 128 -139.
17. Aoki A, Sasaki KM, Watanabe H, et al. Lasers in nonsurgical periodontal therapy. *Periodontol* 2000 2004; 36:59–97.
18. Pfitzner, A., Sigusch, B. W., Albrecht, V. &Glockmann, E. Killing of periodontopathogenic bacteria by photodynamic therapy. *Journal of Periodontology* 2004; 75: 1343–1349.
19. Al-Hamoudi N, Mokeem S, Shafqat SS, et al. Effectiveness of antimicrobial photodynamic therapy as an adjunct to open flap debridement in patients with aggressive periodontitis. *PhotodiagnosisPhotodyn Ther* 2021;33:102075.
20. Abbas monzavi et al. Antimicrobial photodynamic therapy using diode laser activated indocyanine green as an adjunct in the treatment of chronic periodontitis photodiagnosis and photodynamic therapy 2016; 14: 93-97.