



## Pyknodysostosis – Rare Pediatric Case Report

Dr. Divya Lakshmi A<sup>1\*</sup>, Dr. Sundari S<sup>2</sup>, Dr. Ramya R<sup>3</sup>

<sup>1\*</sup>Junior Resident, Department Of Pediatrics, Sree Balaji Medical College and Hospital, Chennai.

<sup>2</sup>professor and Head of Department, Department Of Pediatrics, Sree Balaji Medical College and Hospital, Chennai.

<sup>3</sup>associate Professor, Department Of Pediatrics, Sree Balaji Medical College and Hospital, Chennai.

### Article Info

Volume 6, Issue 6, July 2024

Received: 02 June 2024

Accepted: 30 June 2024

Published: 24 July 2024

*doi: 10.33472/AFJBS.6.6.2024.7494-7499*

### ABSTRACT:

Pyknodysostosis is a rare autosomal recessive genetic disorder affecting the CTSK gene, which is involved in bone matrix proteins. It is associated with its own set of distinctive features such as multiple Oro-maxillary facial abnormalities and skeletal deformities. We present a 4-year-old boy child, born to a non-consanguineous marriage, with features typical of the disease. A skeletal survey was performed, and associated features were confirmed. Whole exome sequencing was done to confirm the presence of mutation in CTSK gene. The child was advised regular follow up and adequate counselling was given to the parents regarding the need for a regular follow-up and multidisciplinary approach for maintaining the quality of life. Potential research in this field is essential as there is no standard approach of care for the child.

**Keywords:** genetic, growth hormone, CTSK gene, acro-osteolysis, cathepsin K

© 2024 Dr. Divya Lakshmi A, This is an open access article under the CC BY license (<https://creativecommons.org/licenses/by/4.0/>), which permits unrestricted use, distribution, and reproduction in any medium, provided you give appropriate credit to the original author(s) and the source, provide a link to the Creative Commons license, and indicate if changes were

## 1. Introduction

Pyknodysostosis is a lysosomal storage disorder, which is autosomal recessive in nature and is comprising of various skeletal abnormalities. It was first described in 1962 by Maroteaux and Lamy. The name is derived from the Greek words "pykno," meaning "dense," and "dysostosis," referring to abnormal bone formation.<sup>1</sup> It is caused by mutations in the CTSK gene, which encodes the enzyme cathepsin K, which is required for the breakdown of bone matrix proteins. These mutations lead to an abnormal or absent cathepsin K, resulting in impaired bone resorption and formation of brittle but dense bones.<sup>2</sup>

### Clinical Details:

A 4-year-old male child, third-born out of non-consanguineous marriage, presented to the OPD with a delayed attainment of milestones. Baby was born via a normal vaginal delivery at full term with a birth weight of 3.5kg. There were no significant antenatal, natal or post-natal events. Later, the mother noticed a delayed attainment of gross motor milestones compared to her other children. The child attained head control at 11 months, rolled over at 2 years, sat with support at 2.5 years, walked with support at 2 years 9 months and walked without support at 3 years. All other domains of development were appropriate for age. Delay was noted only in gross motor development. According to Denver II scale, the child could throw a ball overhead and could not do a broad jump.<sup>2</sup> This corresponds to 3 years of age of development. No family history of any genetic disorders was noted.

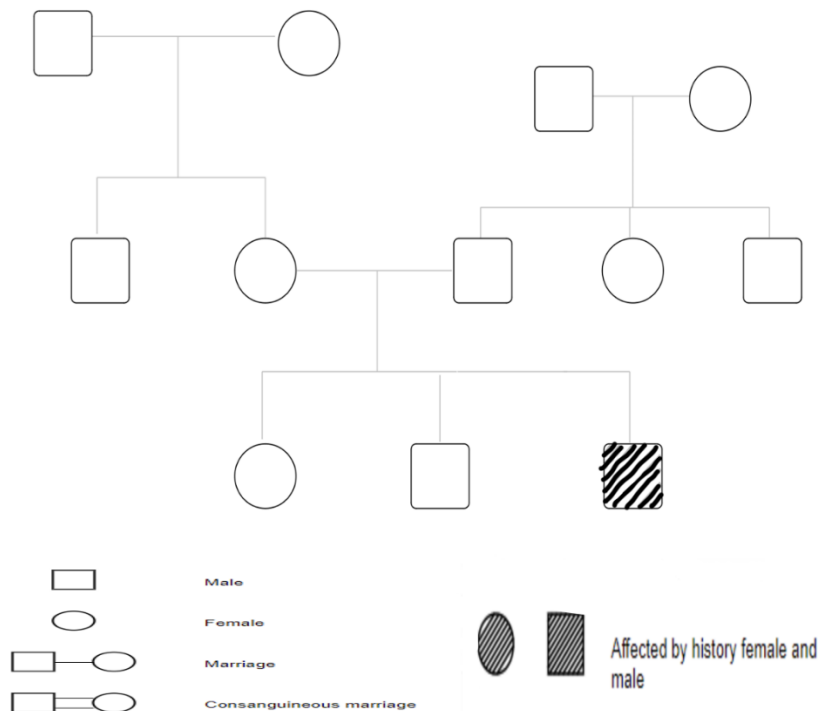


Fig 1: Pedigree analysis of the family

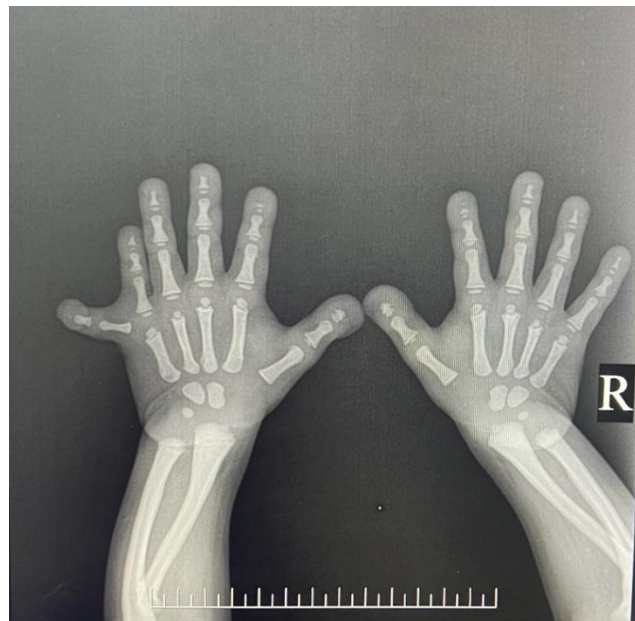
On examination, the child was alert, active and afebrile. Anterior and posterior fontanelles were wide open with unfused sutures. Large and wide palpebral fissures were noted with biparietal enlargement and frontal bossing. Dental malalignment was noted for which dental consultation was sought. Pectus excavatum was a prominent feature along with a protruded abdomen. The

child had a short stature with short and stubby fingers, left polydactyly and flat foot with prominent calcaneum. Vitals were all stable.

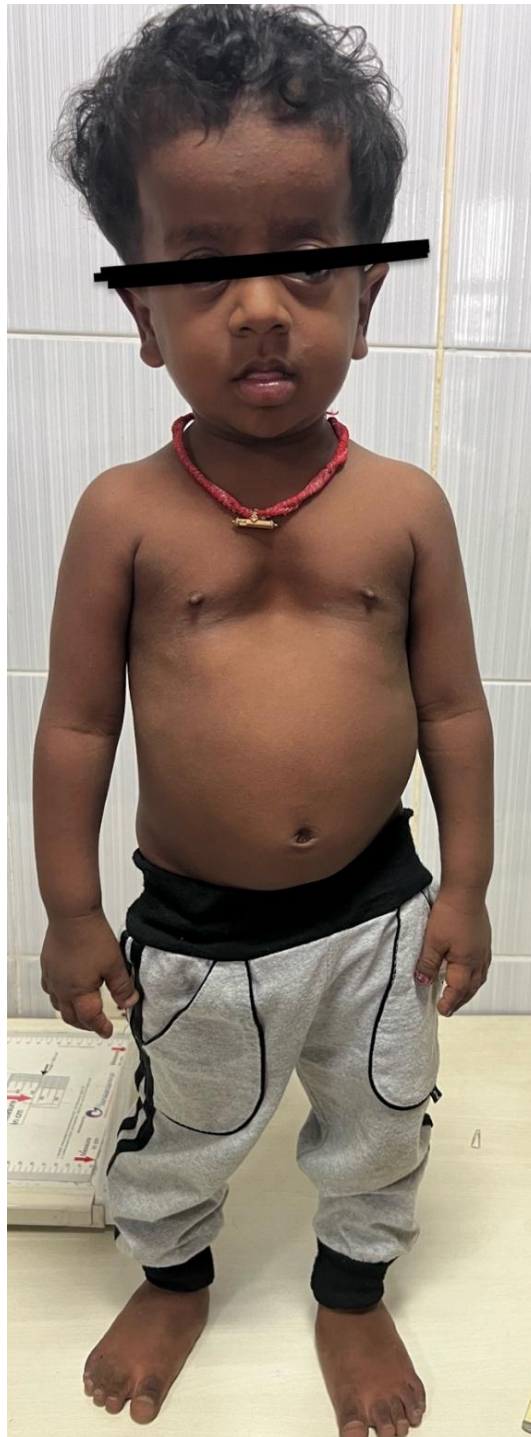

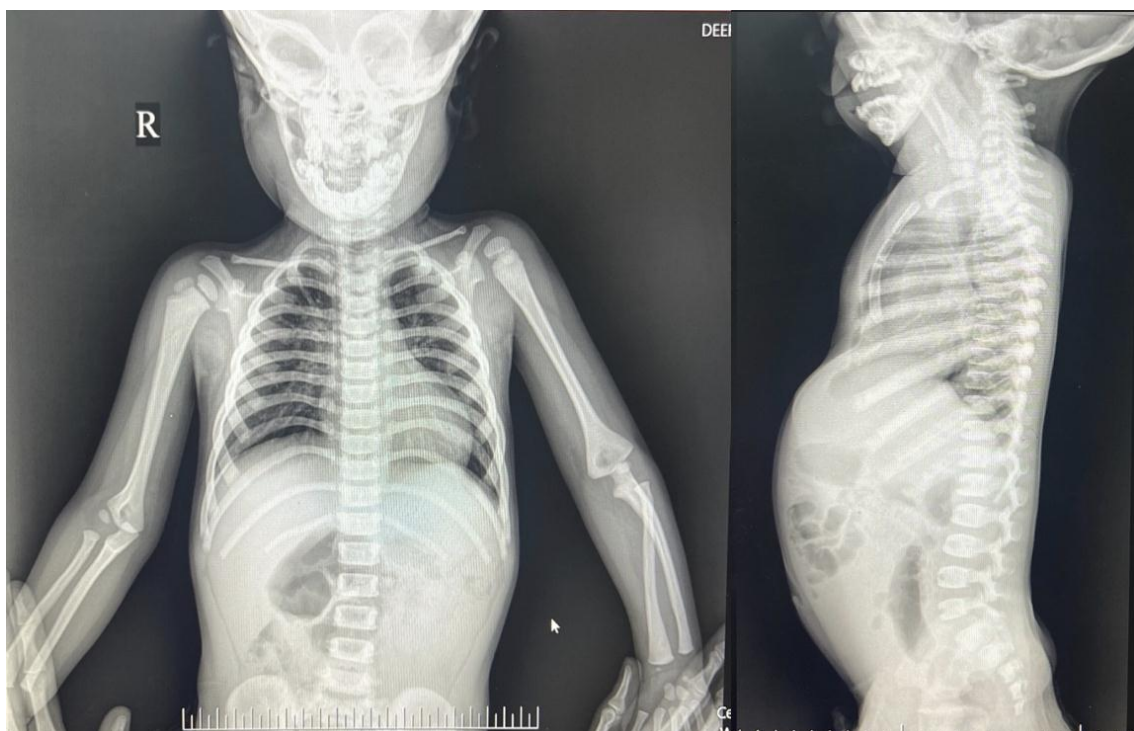
Fig 2: Characteristics of the child with short stature, characteristic facial features (small jaw with angled mandible and pectus excavatum)

Fig 2: Antero posterior (AP) radiograph of hands showing acro-osteolysis. Medullary expansion of distal radius. Remodeled and narrowed terminal phalanges with left



polydactyly.

Fig 3: (Left) Chest radiograph AP showing typical hypoplastic clavicles (Right) Lateral view of Lumbosacral spine showing dense vertebral bodies with sparing of transverse process



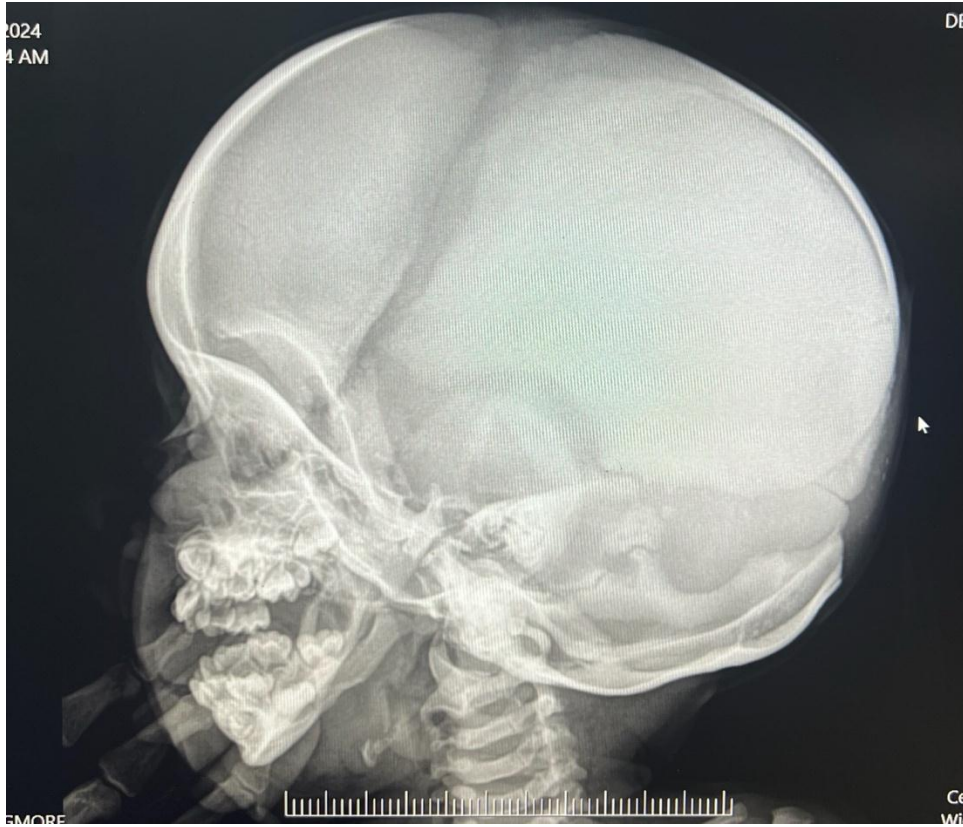


Fig 4: Lateral radiograph skull showing wide open fontanelle, acutely angled mandible and Wormian bones.

The child had a head circumference of 51cm (0 to 1 SD), height of 80cm (<-3 SD), weight of 10.150kg (<-3 SD) with weight for height (0 to -1SD). Systemic examination was all found to be normal.

Vision and hearing assessment was done and found to be normal. Ultrasonography of the abdomen revealed no other anomalies. A skeletal survey was done to look for bony abnormalities as shown in the figures. Genetics opinion was obtained and was advised to do whole exome sequencing. Sequencing showed that the patient was homozygous for a pathogenic variant in the CTSK gene associated Pyknodysostosis.

The parents were counseled regarding the disease and need for a multi-departmental follow up in the long term. An option of growth hormone therapy was offered but was not given due to affordability issues.

## 2. Discussion

Pyknodysostosis is an autosomal recessive disease, which means that both the parents must carry the defective gene for the child to be affected. A high amount of suspicion is required to make the diagnosis, which needs to be made primarily based on clinical findings. Radiological imaging helps in further affirming the diagnosis by showing increased bone density, notably seen in the skull and long bones.<sup>3</sup> Three main features of the disease include osteosclerosis, acro-osteolysis and disproportionate short stature, all of which are present in our case.<sup>4</sup> Other notable features which were seen were brachydactyly with grooved nails, dental anomalies. Confirmatory tests include testing for a mutation in the CTSK gene. Several other diseases such as osteopetrosis, hypoparathyroidism and cleidocranial dysplasia are to be

ruled out while diagnosing the disease. As there is no well-defined primary care, the child is treated with supportive therapy. Even though it is known to have no impact on life expectancy, regular follow-up with the pediatrician as the primary team and intervention with orthopedics, and Oro-maxillary facial surgeons is essential in the long term to avoid complications. One such case was reported in literature with a 17-year-old girl with the disease and severe facial and dental abnormalities.<sup>5</sup> Follow-up with pediatric endocrinologists for growth hormone therapy may be required for some children with short stature. It is shown to have a good response if started during early life.<sup>6</sup> Further research in enzyme and gene replacement therapy may help in potential treatment options in the future.

### 3. Conclusion

Pyknodysostosis is a rare but well characterized genetic disorder with distinctive features and a clear genetic cause. With no known cure for the disease, supportive measures can help in managing the symptoms and improving the quality of life for the children. Once identified, adequate checkups along with proper family genetic counselling is required. Potential research in this area may provide some hope for affected individuals and their family.

### 4. References

1. Xue Y, Cai T, Shi S, Wang W, Zhang Y, Mao T, Duan X. Clinical and animal research findings in pycnodysostosis and gene mutations of cathepsin K from 1996 to 2011. *Orphanet J Rare Dis.* 2011;6:20.
2. Frankenburg WK, Dodds JB. The Denver developmental screening test. *J Pediatr.* 1967;71(2):181-91.
3. Dixon A, Pyknodysostosis. Case study, Radiopaedia.org (Accessed on 22 Jul 2024) <https://doi.org/10.53347/rID-10291>
4. LeBlanc S, Savarirayan R. Pycnodysostosis. 2020 Nov 5 [Updated 2023 Apr 6]. In: Adam MP, Feldman J, Mirzaa GM, et al., editors. *GeneReviews®* [Internet]. Seattle (WA): University of Washington, Seattle; 1993-2024.
5. Ramaiah KK, George GB, Padiyath S, Sethuraman R, Cherian B. Pyknodysostosis: report of a rare case with review of literature. *Imaging Sci Dent.* 2011 Dec;41(4):177-81. doi: 10.5624/isd.2011.41.4.177. Epub 2011 Dec 19.
6. Omer Sulaiman H, Thalange NKS. Pycnodysostosis: A Growth Hormone Responsive Skeletal Dysplasia. *AACE Clin Case Rep.* 2021 Mar 4;7(4):231-235. doi: 10.1016/j.aace.2021.02.006. PMID: 34307842; PMCID: PMC8282518.