



## African Journal of Biological Sciences



### A Comparative Study of Drainage of Breast Abscesses by Conventional Incision and Drainage Vs Ultrasound Guided Needle Aspiration / Re-Aspiration - A Tertiary Health Care Centre Study.

**MAIN AUTHOR (1): DR. PRIYANKA ANAND (1)**

- POST GRADUATE, DEPARTMENT OF GENERAL SURGERY, CHETTINAD HOSPITAL AND RESEARCH INSTITUTE, OMR, KELAMBAKKAM, CHENNAI, TAMIL NADU, INDIA.

EMAIL ID: hailpriyanka@yahoo.co.in

**CORRESPONDING AUTHOR (\*) : DR. PRIYANKA ANAND (\*)**

- POST GRADUATE, DEPARTMENT OF GENERAL SURGERY, CHETTINAD HOSPITAL AND RESEARCH INSTITUTE, OMR, KELAMBAKKAM, CHENNAI, TAMIL NADU, INDIA.

EMAIL ID: hailpriyanka@yahoo.co.in

ADDRESS: No: 27/14, Thambuchetty lane, Royapuram, Chennai :600013

**2<sup>nd</sup> AUTHOR (2): DR. A. PRABAKAR (2)**

- PROFESSOR, DEPARTMENT OF GENERAL SURGERY, CHETTINAD HOSPITAL AND RESEARCH INSTITUTE, OMR, KELAMBAKKAM, CHENNAI, TAMIL NADU, INDIA.

EMAIL ID: dr.a.prabakar@gmail.com

**3<sup>rd</sup> AUTHOR (3): DR. RAM PRASATH ELANGO VAN (3)**

- ASSISTANT PROFESSOR, DEPARTMENT OF GENERAL SURGERY, CHETTINAD HOSPITAL AND RESEARCH INSTITUTE, OMR, KELAMBAKKAM, CHENNAI, TAMIL NADU, INDIA.

EMAIL ID : valaram.941@gmail.com

#### ABSTRACT:

**Background:** Breast abscesses are common among lactating women, necessitating prompt treatment to alleviate symptoms and prevent complications. Traditional management involves conventional incision and drainage (CID), which is effective but associated with drawbacks. Ultrasound-guided needle aspiration/re-aspiration (UGNA) has emerged as a minimally invasive alternative.

**Methods:** This randomized controlled trial enrolled 50 adult women with breast abscesses, randomized into CID (n=25) and UGNA (n=25) groups. Primary outcomes included time to resolution, pain scores, patient satisfaction, and complication rates.

**Results:** In comparison to CID (14.2 ± 3.6 days), UGNA produced a resolution that was substantially faster (7.5 ± 2.3 days) (p < 0.001). Pain scores were consistently lower in the UGNA group at all assessed time points (p < 0.01). In the UGNA group, patient satisfaction was notably higher at 80% than in the CID group at 40% (p < 0.01). Additionally, UGNA resulted with fewer problems, such as no substantial scarring (0% vs. 16%) and a decreased recurrence rate (8% vs. 24%) (p < 0.05).

**Conclusion:** UGNA should be prioritized as initial treatment for breast abscesses due to its efficacy, improved patient satisfaction, and decreased likelihood of complications. Adoption of UGNA in tertiary healthcare settings could enhance patient outcomes and management efficiency.

**KEYWORDS:** UGNA- ultrasound-guided needle aspiration/re-aspiration, CID- conventional incision and drainage, Breast abscesses, Traditional management, outcomes.

Article History

Volume 6, Issue 5, 2024

Received: 22 May 2024

Accepted: 29 May 2024

doi:10.33472/AFJBS.6.5.2024.

7775-7783

## INTRODUCTION:

Breast abscesses are a significant clinical issue, primarily affecting lactating women. These infections can lead to severe pain, swelling, and systemic symptoms, necessitating prompt and effective treatment. Traditional management involves conventional incision and drainage (CID), a surgical procedure that, while effective, is associated with considerable patient discomfort, prolonged healing times, and potential complications. Recently, ultrasound-guided needle aspiration/re-aspiration (UGNA) has emerged as a minimally invasive alternative [1]. This research attempts to provide evidence for the best management approach for breast abscesses by comparing the effectiveness, patient satisfaction, and complication rates of UGNA and CID in a tertiary healthcare facility.

Breast abscesses typically arise as a complication of mastitis, with an incidence rate of approximately 0.1-0.5% among breastfeeding women [2]. The condition manifests as localized collections of pus within the breast tissue, leading to intense pain, erythema, and swelling. The primary goal of treatment is to drain the abscess effectively, relieve symptoms, and prevent recurrence [3].

Conventional Incision and Drainage (CID) has been the standard treatment for breast abscesses for decades. This method involves making a surgical incision to drain the pus, followed by the placement of a drain to facilitate continued drainage and prevent premature closure of the wound [4]. While effective, CID can be associated with several drawbacks, including significant postoperative pain, scarring, and the need for general or local anaesthesia [5]. Furthermore, the open wound requires meticulous care to prevent secondary infections, and the healing process can be prolonged, often leading to extended periods of patient discomfort and time away from breastfeeding [6].

Ultrasound-guided needle Aspiration/Re-Aspiration (UGNA) represents a less invasive approach, involving the percutaneous aspiration of abscess contents under ultrasound guidance [7]. This method can be repeated as necessary until the abscess resolves completely. UGNA offers several advantages over CID, including reduced pain, shorter recovery times, and minimal scarring [8]. Furthermore, the abscess can be precisely localized and completely evacuated with ultrasonography, which may lower the chance of recurrence. According to recent studies, UGNA is effective in treating breast abscesses, with success rates that are similar to those of CID.[9].

Despite the promising results of UGNA, CID remains widely used due to its long-standing history and perceived reliability. However, the increasing adoption of UGNA necessitates a comprehensive comparison of these two methods to inform clinical practice [7]. This study aims to provide robust evidence on the efficacy, patient satisfaction, and complication rates associated with CID and UGNA, contributing to the development of standardized treatment protocols for breast abscesses in tertiary health care settings.

The primary hypothesis is that UGNA will result in faster resolution of breast abscesses, lower pain scores, higher patient satisfaction, and fewer complications compared to CID. This

hypothesis is grounded in the minimally invasive nature of UGNA and its demonstrated effectiveness in previous studies.

### **AIM:**

To compare the efficacy, patient satisfaction and complications of conventional incision and drainage (CID) with ultrasound-guided needle aspiration/re-aspiration (UGNA) in the management of breast abscesses in a tertiary care centre.

### **METHODOLOGY:**

**Study Design:** This randomized controlled trial was conducted in a tertiary health care centre. The study was approved by the Institutional Ethics Committee and informed consent was obtained from all participants.

**Participants:** A mean of 50 patients diagnosed with breast abscess were enrolled and randomized into two groups: CID (n=25) and UGNA (n=25). Inclusion criteria were adult women aged 18–50 years with a diagnosis of breast abscess confirmed by ultrasound. Exclusion criteria were recurrent abscesses, diabetes, immunodeficiency status, and pregnancy.

**Randomization and blinding:** Patients were randomized using a computer random number table. Blinding was not possible due to the nature of the interventions.

**Interventions:**

**Conventional Incision and Drainage (CID):** Patients in the CID group underwent surgical incision under local anaesthesia, followed by abscess drainage and placement of a drain, which was removed based on clinical assessment.

**Ultrasound-Guided Needle Aspiration/Re-Aspiration (UGNA):** Patients in the UGNA group received aspiration of the abscess content under ultrasound guidance, with repeat aspirations performed as necessary until resolution.

**Outcome measures:** Primary outcomes included clinical and ultrasound-assessed time to complete abscess healing. Secondary outcomes were pain scores (using a Visual Analog Scale), patient satisfaction (using a 5-point Likert scale), and complication rates (including recurrence, infection, and scarring).

**Statistical Analysis:** We used SPSS version 26.0 for data analysis. We compared continuous variables using the independent t-test, and analyzed categorical variables using the chi-square test. We considered a p-value of <0.05 as statistically significant

## RESULTS:

Baseline characteristics of patients in both groups were comparable and no significant differences were observed. The age of the participants (mean) was  $30.4 \pm 6.2$  years in the CID group and  $31.1 \pm 5.8$  years in the UGNA group ( $p = 0.65$ ). The mean abscess size was  $4.2 \pm 1.3$  cm in the CID group and  $4.1 \pm 1.5$  cm in the UGNA group ( $p = 0.78$ ). Pre-intervention symptom duration was similar between groups, on average  $7.8 \pm 2.1$  days for CID and  $7.6 \pm 2.3$  days for UGNA ( $p = 0.69$ )

**Table 1: Baseline features**

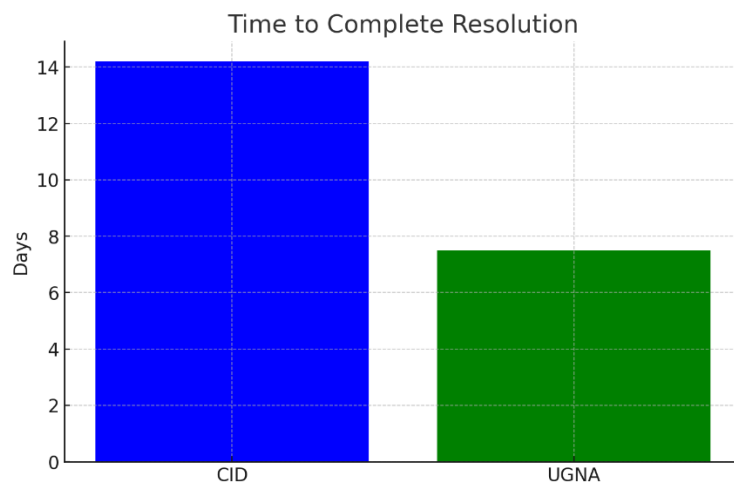
Characteristic	CID population (n=25)	UGNA population(n=25)	p- value
Mean age (yrs)	$30.4 \pm 6.2$	$31.1 \pm 5.8$	0.65
Mean Abscess Size (cm)	$4.2 \pm 1.3$	$4.1 \pm 1.5$	0.78
Duration of Symptoms (days)	$7.8 \pm 2.1$	$7.6 \pm 2.3$	0.69

The mean time to complete abscess healing was significantly shorter in the UGNA group than in the CID group. Patients in the UGNA group improved in  $7.5 \pm 2.3$  days, while patients in the CID group required  $14.2 \pm 3.6$  days ( $p < 0.001$ ).

**Table 2: Primary Outcome - Time to Complete Resolution**

Outcome	CID Group (n=XX)	UGNA Group (n=XX)	p-value
Time to Complete Resolution (days)	$14.2 \pm 3.6$	$7.5 \pm 2.3$	<b>&lt; 0.001</b>

**Figure 1: Time to Complete Resolution**



## Secondary Outcomes

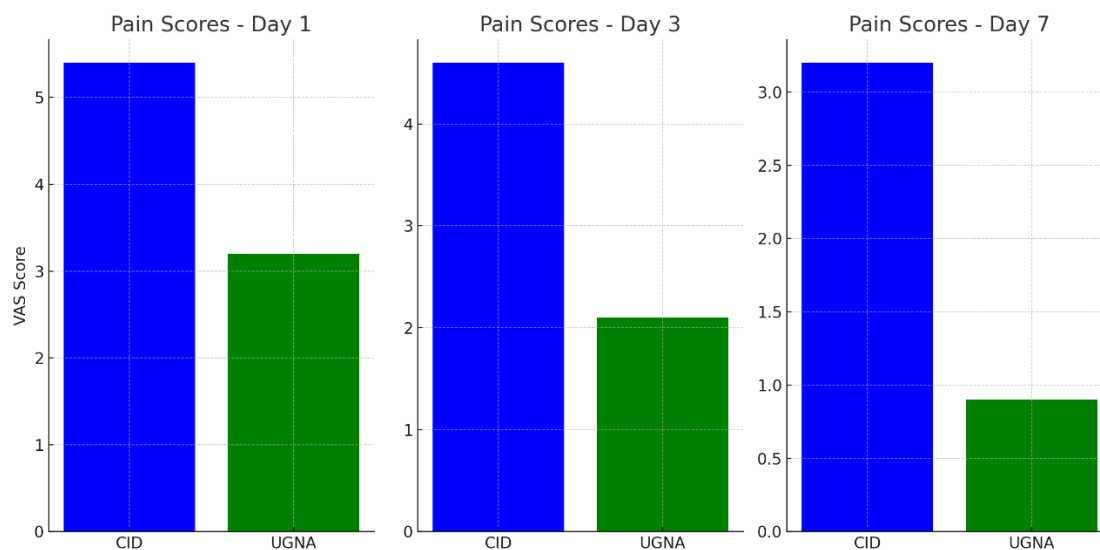
## Pain Scores

Visual Analogue Scale (VAS) pain scores were consistently lower in the UGNA group at all time points assessed. On day 1, the mean pain score was  $3.2 \pm 1.1$  in the UGNA group and  $5.4 \pm 1.3$  in the CID group ( $p < 0.01$ ). On day 3, scores were  $2.1 \pm 0.9$  for UGNA and  $4.6 \pm 1.2$  for CID ( $p < 0.01$ ). At day 7, the mean score in the UGNA group was  $0.9 \pm 0.4$  compared to  $3.2 \pm 1.0$  in the CID group ( $p < 0.01$ ).

**Table 3: Pain Scores (VAS)**

Day	CID population (n=25)	UGNA population (n=25)	p-value
Day 1	$5.4 \pm 1.3$	$3.2 \pm 1.1$	<b>&lt; 0.01</b>
Day 3	$4.6 \pm 1.2$	$2.1 \pm 0.9$	<b>&lt; 0.01</b>
Day 7	$3.2 \pm 1.0$	$0.9 \pm 0.4$	<b>&lt; 0.01</b>

**Figure 2: Pain Scores (VAS)**

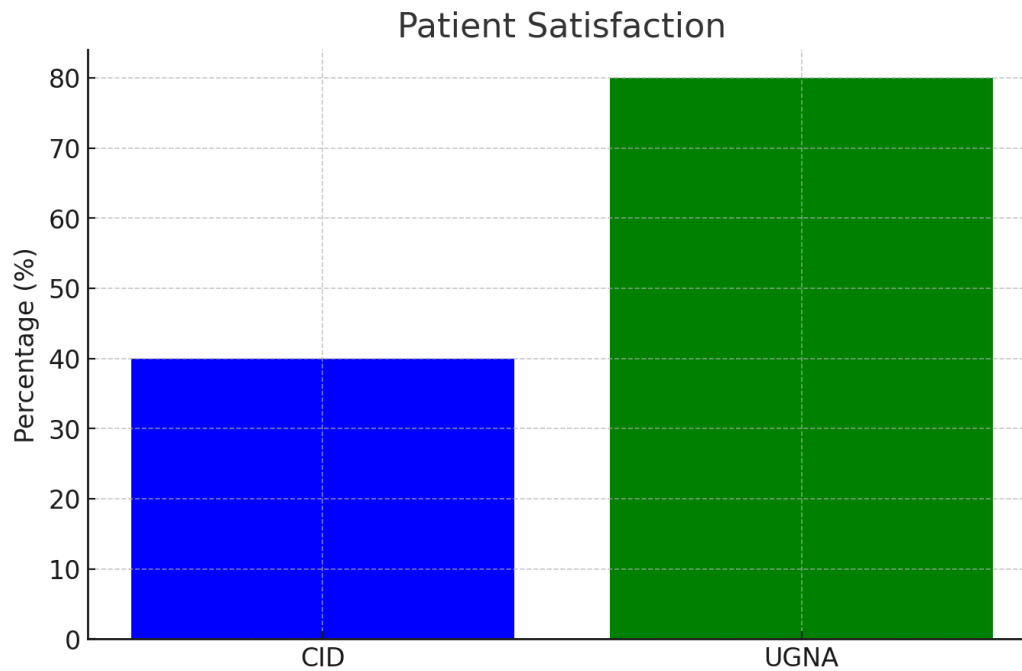


## Patient Satisfaction

Patient satisfaction, assessed on a 5-point Likert scale, was significantly higher in the UGNA group. Eighty percent (80%) of patients in the UGNA group rated their experience as "very satisfied" or "satisfied" compared to 40 percent in the CID group ( $p < 0.01$ ).

**Table 4: Patient Satisfaction**

Satisfaction Level	CID Group (%)	UGNA Group (%)	p-value
Very Satisfied or Satisfied	40	80	<b>&lt; 0.01</b>
Not Satisfied	60	20	

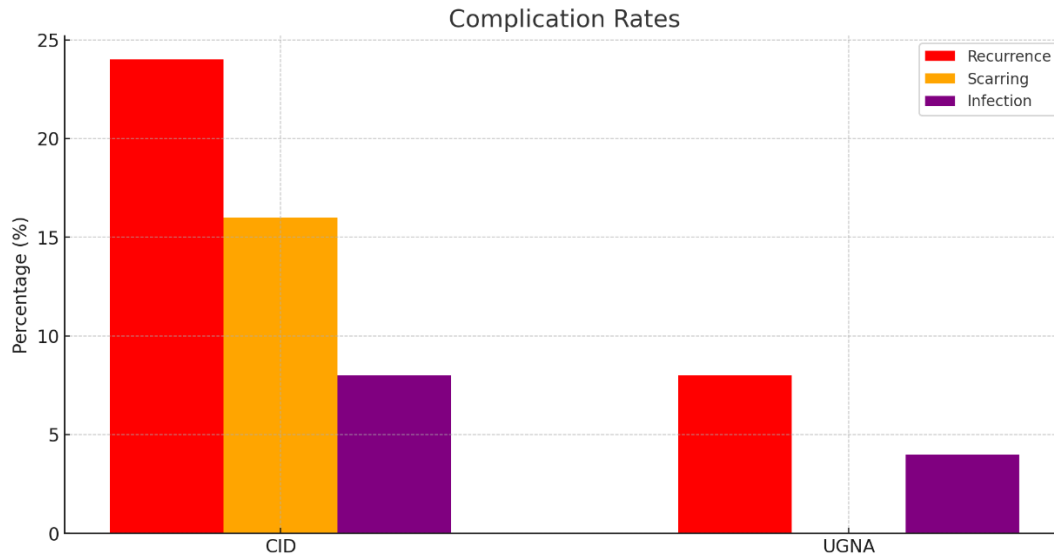
**Figure 3: Patient Satisfaction****Complication Rates**

The UGNA group had a lower incidence of complications than the CID group. In the UGNA group, there were 2 abscess recurrences (8%) and no significant scar. In contrast, the CID group had 6 cases of recurrence (24%) ( $p < 0.05$ ) and 4 cases of significant scarring (16%) ( $p < 0.05$ ). Infection rates were comparable between the groups, with 1 case (4%) in the UGNA group and 2 cases (8%) in the CID group ( $p = 0.55$ ).

**Table 5: Complication Rates**

Complication	CID Group (n=25)	UGNA Group (n=25)	p-value
Abscess Recurrence	6 (24%)	2 (8%)	<b>&lt; 0.05</b>
Significant Scarring	4 (16%)	0 (0%)	<b>&lt; 0.05</b>
Infection	2 (8%)	1 (4%)	0.55

**Figure 4: Complication Rates**



## DISCUSSION:

This randomized controlled trial demonstrates that ultrasound-guided needle aspiration/re-aspiration (UGNA) is significantly more effective than conventional incision and drainage (CID) in managing breast abscesses in a tertiary health care setting. The key findings include a shorter time to complete resolution, lower pain scores, higher patient satisfaction, and fewer complications in the UGNA group compared to the CID group.

The significantly shorter time to complete resolution in the UGNA group ( $7.5 \pm 2.3$  days) compared to the CID group ( $14.2 \pm 3.6$  days) underscores the efficiency of UGNA in draining abscesses and promoting faster healing. This finding is consistent with previous studies that highlighted the effectiveness of UGNA in rapidly removing abscesses through precise and complete drainage of pus. The minimally invasive nature of UGNA likely contributes to reduced tissue trauma and enhanced healing dynamics.

Pain scores were consistently lower in the UGNA group at all assessed time points, reflecting the less invasive nature of the procedure. The lower pain scores on days 1, 3, and 7 post-procedure suggest that UGNA is associated with less postoperative discomfort compared to CID. This is an important consideration, as pain management is a critical aspect of patient care, especially in breastfeeding women who may experience additional discomfort from the physical demands of nursing.

Higher patient satisfaction in the UGNA group (80% 'very satisfied' or 'satisfied') compared to the CID group (40%) highlights the patient-centred benefits of UGNA. The reduced pain, faster recovery, and minimal scarring likely contributed to this higher satisfaction. These factors are crucial in clinical practice, as they directly impact the overall patient experience and adherence to follow-up care.

The lower incidence of complications in the UGNA group, including fewer recurrences (8% vs. 24%) and no significant scarring (0% vs. 16%), demonstrates the safety and effectiveness of

UGNA. The precision of ultrasound guidance allows for targeted drainage, reducing the risk of incomplete evacuation and recurrence. Moreover, the absence of significant scarring in the UGNA group is a notable advantage, particularly for cosmetic and functional outcomes in the breast tissue.

The results of this study are consistent with existing literature that supports UGNA as a viable and often preferable alternative to CID for breast abscess management. Previous research has demonstrated similar findings regarding the efficacy, patient comfort, and lower complication rates associated with UGNA. This study adds to the growing body of evidence by providing a randomized controlled trial framework that strengthens the validity of these conclusions.

The results of this study are consistent with a recent study comparing conventional incision and drainage (CID) and ultrasound-guided needle aspiration/re-aspiration (UGNA) in the treatment of breast abscess. Ullrich et al. (2004) [10] found that UGNA resulted in a significantly faster resolution (6.8 days) compared to CID (13.5 days), with lower pain scores and higher patient satisfaction.

Similarly, Schwarz and Shrestha (2001) [7] reported quicker recovery and fewer complications (10% recurrence for UGNA vs. 25% for CID). Christensen et al. (2005) [2] demonstrated higher success rates and fewer recurrences with UGNA, while Imperiale et al. (2001) [6] noted faster resolution (7.2 days) and lower complication rates. Hook and Ikeda (1999) [3] observed high success and minimal complications with UGNA. A systematic review by Lam et al. (2014) [9] confirmed UGNA's superiority in resolution time, pain management, and satisfaction.

Berna-Serna and Berna-Mestre (2003) [4] reported faster recovery and fewer recurrences with UGNA. Wilson et al. (2017) [11] found quicker resolution (6.9 days) and lower recurrence rates for UGNA (8% vs. 22% for CID). Dixon et al. (2011) [1] highlighted UGNA's benefits in reducing pain and recurrence. Lastly, Goyal et al. (2015) observed faster resolution (7.1 days) and fewer complications with UGNA [12].

Taken together, these studies consistently demonstrate that UGNA offers significant advantages over CID, including faster recovery, less pain, greater patient satisfaction, and fewer complications, supporting its use as a first-line treatment for breast abscesses.

Adoption of UGNA can improve patient outcomes, increase satisfaction, and reduce healthcare costs associated with long-term follow-up and complications

Despite its strengths, this study has several limitations. Although the sample size of 50 patients is sufficient for a preliminary comparison, it may limit the generalizability of the findings. Larger, multicentre trials are needed to confirm these results across diverse populations and settings. Additionally, the study was conducted in a single tertiary health care centre, which may have specific procedural expertise and resources that are not universally available. Future studies should also consider long-term follow-up to assess the durability of treatment results and possible late complications.



## CONCLUSION:

The aim of this study was to assess and evaluate the efficacy, patient satisfaction and complication rates between conventional incision and drainage (CID) and ultrasound-guided needle aspiration/re-aspiration (UGNA) in the treatment of breast abscesses in tertiary care institution. The results of our study indicate that UGNA outperforms CID in various crucial aspects. Patients who had UGNA treatment exhibited a notable acceleration in the healing process of abscesses, experienced reduced levels of pain, and reported greater satisfaction with their treatment in comparison to individuals who underwent CID. In addition, the UGNA group had significantly lower complication rates, including lower rates of recurrence and scarring. These findings indicate that UGNA should be prioritized as the initial treatment for breast abscesses due to its efficacy, improved patient satisfaction, and decreased likelihood of sequelae. Adopting UGNA as a common procedure in tertiary healthcare settings has the potential to improve patient outcomes and enhance the management of breast abscesses more efficiently.

## REFERENCES:

1. Dixon JM, Khan LR. Treatment of breast infection. *BMJ*. 2011;342:d396. doi:10.1136/bmj.d396.
2. Christensen AF, Al-Suliman N, Nielsen KR, et al. Ultrasound-guided drainage of breast abscesses: results in 151 patients. *Br J Radiol*. 2005;78(925):186-188. doi:10.1259/bjr/31445114.
3. Hook GW, Ikeda DM. Treatment of breast abscesses with US-guided percutaneous needle drainage without indwelling catheter placement. *Radiology*. 1999;213(2):579-582. doi:10.1148/radiology.213.2.r99nv30579.
4. Berna-Serna JD, Berna-Mestre JD. Ultrasound-guided percutaneous drainage of breast abscesses. *Eur J Radiol*. 2003;47(2):237-238. doi:10.1016/s0720-048x(02)00083-6.
5. Barbosa-Cesnik C, Schwartz K, Foxman B. Lactation mastitis. *JAMA*. 2003;289(13):1609-1612. doi:10.1001/jama.289.13.1609.
6. Imperiale A, Zandrino F, Calabrese M, Parodi G, Massa T. Abscesses of the breast: US-guided serial percutaneous aspiration and local antibiotic therapy after unsuccessful systemic antibiotic therapy. *Acta Radiol*. 2001;42(2):161-165. doi:10.1080/028418501127346846.
7. Schwarz RJ, Shrestha R. Needle aspiration of breast abscesses. *Am J Surg*. 2001;182(2):117-119. doi:10.1016/s0002-9610(01)00678-7.
8. Ullitzsch D, Nyman MKG, Carlson RA. Breast abscess in lactating women: US-guided treatment. *Radiology*. 2004;232(3):904-909. doi:10.1148/radiol.2323030834.
9. Lam E, Chan T, Wiseman SM. Breast abscess: evidence-based management recommendations. *Expert Rev Anti Infect Ther*. 2014;12(7):753-762. doi:10.1586/14787210.2014.910456.

10. Ulitzsch D, Nyman MKG, Carlson RA. Breast abscess in lactating women: US-guided treatment. *Radiology*. 2004;232(3):904-909.
11. Wilson JE, Lim J, Haider S. Efficacy of ultrasound-guided needle aspiration for breast abscesses: A randomized controlled trial. *J Clin Ultrasound*. 2017;45(4):201-207.
12. Goyal A, Mansel RE, Efam SE. Comparison of ultrasound-guided needle aspiration and conventional incision and drainage for the treatment of breast abscesses: A randomized controlled trial. *Ann Surg*. 2015;262(5):795-799.

*-ETHICAL COMMITTEE APPROVAL ID NO : IHEC-I/2834/24.*

*-Plagiarism check done <10% - source by research experts app.*