

<https://doi.org/10.33472/AFJBS.6.6.2024.90-99>



African Journal of Biological Sciences



Histopathological and Molecular study of effects of Nickel Chloride on liver of the adult male mice

Nuha Shaker Ali^{1*}

¹University of Al-Qadisiyah, Dentistry College, the Basic Sciences department, IRAQ

*Corresponding author: nuha.albadry@qu.edu.iq

Article History

Volume 6, Issue 6, Feb 2024

Received: 01 Mar 2024

Accepted : 08 Mar 2024

doi:10.33472/AFJBS.6.6.2024.90-99

Abstract:

Nickel Chloride is a toxic chemical reagent used in many applications. Nickel Chloride causes health problems in animals and humans. The current study aims to determine the effectiveness of Nickel Chloride on the histological changes in the mice liver and determines the gene expression of the TP53 gene (Tumor Protein P53) and TERT gene (Telomerase Reverse Transcriptase) in study groups. Twenty adult male mice with (20-30) grams in weight, (16) weeks in age were divided into two groups, each group consisting of ten mice. The first group (G1) was administered Nickel Chloride (40) Mg/kg/BW for 45 days orally, while the control group (G2) was administered PBS. The results showed that the histopathological changes included liver sections of the first group with severe necrosis of hepatocytes, hydropic degenerated hepatocytes, and dilated sinusoids, but some viable cells were seen. Furthermore, the liver tissue demonstrated severe dilatation of sinusoids, hepatocytes atrophy, severe hemorrhage, engorged central vein, and loss of normal striation of the hepatocytes. On the other hand, the control group showed that liver sections have normal architectures with normal hepatocytes. Moreover, the results demonstrated that the gene expression of the TP53 gene and TERT gene were increased in the experimental group compared with the control group. In the end, Nickel Chloride causes histopathological changes in the liver of the mice, such as necrosis and hydropic of the hepatocyte, dilated sinusoids, severe dilatation of sinusoids, hemorrhage, and loss of normal hepatocytes striation. Also, Nickel Chloride causes to increase the gene expression of TP53 gene and TERT gene in mice that received Potassium Dichromate.

Keywords: Histopathological, Nickel Chloride, liver, mice

Introduction:

The Nickel Chloride have negative effect on the public health and the environmental aspects. The nickel compounds are used in the industry for make the plate and screw. NiCl has function of some enzymes and proteins (Ling, et, al. 2022). When Nickel Chloride accumulate inside the body at high concentration, it become toxic for the body tissues and causes histopathological changes of the many organs in the mice (Gui-Hong, et, al. 2014).

The pathological effects of Nickel chloride on the liver in mice depending on various factors such as the dosage, duration of exposure, and individual susceptibility. Nickel chloride is used in industrial processes, electroplating, and as a catalyst. When exposed to nickel chloride, mice and other animals may experience toxic effects, including potential liver damage (Anoosha, et, al. 2018).

Chronic exposure to high levels of nickel chloride in the mice has been associated with hepatotoxicity, which refers to liver damage. The liver plays a crucial role in detoxification, metabolism, and various other physiological processes, and any impairment can have systemic effects (Liu, et, al. 2013). Nickel chloride can induce oxidative stress in the liver, leading to an imbalance between the production of ROS and the antioxidant defense system. ROS are highly reactive molecules, cellular damage, inflammation, lipid peroxidation, DNA damage, and changes in the liver enzymes. Nickel chloride have carcinogens effects (Gathwan, et, al. 2013).

The liver toxicity of nickel chloride can depend on the route and duration of exposure. Inhalation of nickel chloride dust or fumes may result in different effects compared to oral exposure, for example. The toxicological studies evaluate various histopathological changes of Nickel chloride on the liver function, oxidative stress markers, and gene expression, to assess the impact of nickel chloride on the liver (Al-fatlawi, 2017). Nickel chloride causes severe liver lesion by altering marker enzymes and histopathological alterations. Nickel Chloride is cause hepatotoxicity, DNA strand breaks, and chromosomal aberrations in human and animals. Nickel chloride is carcinogens and allergens by forming ROs. Liver are organs that affect by Nickel chloride (Guo, et, al. 2016).

Histopathology is tool that used for determination the effect of heavy metals such as nickel on the body tissue (Danadevi, et, al. 2004). NiCl₂ causes apoptosis in the liver by increasing Bax, Bak, caspase-3, caspase-9 and PARP mRNA expression and decreasing Bcl-2, Bcl-xL, Mcl-1. NiCl₂ increasing p53, and p21. NiCl₂ induces apoptosis through mitochondria (Guo, et, al. 2016). The current study aims to investigate the impact of Nickel Chloride on the histopathologica changes of the liver in mice and determine the gene expression of the TP53 and TERT gene.

Materials and methods:**Animal and study design:**

Twenty adult male mice with (20-30) grams in weight, (16) weeks in age were divided into two groups, each consisting of ten mice. The first group administrated Nickel Chloride (40) Mg/kg/BW orally for 45 days, while the second group (control group) administrated Pbs. After

finishing the administration period, all the animals are sacrificed; the liver sample is divided into two parts, for the histopathological examination (formalin 10%), for RNA Extraction (TRIzol) to determine the genes expression.

Histopathological examination:

The tissue processing involves several steps:

- 1- **Fixation:** The tissue sample is first collected and immediately placed in a fixative solution, which preserves the tissue structure and prevents degradation. Common fixatives include formalin, ethanol, and methanol.
- 2- **Dehydration:** The tissue sample is then dehydrated by being immersed in a series of alcohol solutions with increasing concentrations (e.g., 70%, 80%, 90%, and 100% ethanol). This step removes the water from the tissue, making it easier to embed in paraffin wax.
- 3- **Clearing:** The dehydrated tissue is then transferred to a clearing agent, such as xylene or other organic solvents, to remove any remaining alcohol and to make the tissue transparent.
- 4- **Infiltration:** The cleared tissue is then placed in a bath of melted paraffin wax, which permeates the tissue and replaces the clearing agent. This step helps to support the tissue and make it easier to section.
- 5- **Embedding:** The infiltrated tissue is then placed into molds containing fresh paraffin wax and allowed to solidify. The paraffin-embedded tissue block is then ready for sectioning.
- 6- **Sectioning:** The tissue block is sliced into thin sections (4-8) microns by using a microtome. The sections are then placed on glass slides.
- 7- **Staining:** staining the the sections are done by dyes, to enhance the contrast the different components within the tissue such as hematoxylin and eosin.
- 8- **Coverslipping:** A coverslip is placed over the stained tissue section to protect it and preserve the staining.
- 9- The tissue has been processed and mounted on slides, ready for microscopic examination and analysis.

Extracted RNA:

The RNA extraction is done by (Accuzol® kit. Bioneer). As follows, the sample 200µl are incubated for four h with Accuzol reagent I ml, then the tubes are shaken. Add the chloroform (200) µl on the tubes with mixing by the vortex. The mixture was cooled inside the ice for five minutes. Then centrifuged at (12000) rpm, then cooled at (4) C°, adding the isopropanol (500) µl on the transmitted supernatant layer in new Eppendorf with continued inverting, then cooled at (4) C°. Next, centrifuge the mixture at (12) thousand rpm for 10 minutes. Remove the supernatant layer, add ethanol (1) ml with mixing, and repeat the centrifuge step. Then remove, the supernatant layer, and the RNA pellet was dry by the air directly. Then add DEPC water to the samples to dissolve the RNA pellet, then keep it at (-20).

cDNA synthesis:

cDNA forming was done by a High-Capacity cDNA kit (Applied Biosystems). RNA sample was added to the tube, and a mix with reverse transcriptase buffer, dNTP mix, reverse transcriptase random primers, MultiScribe reverse transcriptase, and DNA-free water. The mixture was placed at 25 °C for ten minutes, the heating at 37 °C for three hours, then heated at 85 °C for five seconds, then cooled at (4) °C.

Primers design:

The primers used in the present study are designed for TP53 gene and TERT gene, which done by several steps; the whole sequence is provided from the NCBI website (<https://www.ncbi.nlm.nih.gov>). The whole sequence was transferred to the website primer 3 plus (<https://www.bioinformatics.nl/cgi-bin/primer3plus/primer3plus.cgi>) to pick specific primers of TP53 gene and TERT gene

Table (1): shows the Sequence, Amplicon size, and Genebank of the used primers in the study

Gene		Primer Sequence	Amplicon Amplicon size	Gene ID
TP53	F	GAGAGACCGCCGTACAGAAG	245 bp	NC_000077.7
	R	CCTTGGTACCTTGAGGGTGA		
TERT	F	TGGTGAAGAGAGCCCAGACT	176 bp	NC_000079.7
	R	TCAGCAAAAAGGAGCCAAGT		

Quantification by RT-PCR:

The quantitative of mRNA was done by real-time PCR to produce CDNA. The reaction mix has primers (F and R), SYBR Green, DNA-free water, and cDNA sample. The thermocycling conditions were showed in Table (2).

Table (2): shows temperature, time, and cycle number for PCR stages

The stage	Temp./ C ⁰	Time/ minutes	Cycle number
The initial stage	95	10	1
The denaturation stage	95	15	40
The annealing/ extension	60	1	
The final stage	74	4	

Real-time PCR data analysis:

RT-PCR was analyzed depending on the ($\Delta\Delta CT$) method as follows:

$$\Delta CT = CT \text{ gene of interest} - CT \text{ keeping house gene}$$

$$(\Delta\Delta CT) = CT \text{ of the corresponding groups} - \Delta CT \text{ of control}$$

$$\text{The fold change (FC)} = 2^{-\Delta(\Delta CT)}$$

Statistical analysis:

The DATA were analyzed by ANOVA (one-way and two-way) depending on SPSS, V27; the USA). LSD test was used to determine the significant difference between the groups at the significant level at ($P \geq 0.05$) (Schiefer, 1980).

The results:

1- The histopathological examination:

The first group (administrated Nickel Chloride) showed that liver sections have severe necrosis of hepatocytes, hydropic degenerated hepatocytes, and dilated sinusoids were evident, but some viable cells were seen. Furthermore, the liver demonstrated severe dilatation of sinusoids, hepatocytes atrophy, severe hemorrhage, engorged central vein, and loss of normal striation of the hepatocytes sheets, as shown in tables (1), and (2). The control group showed that the liver sections have normal architectures with normal hepatocytes, as shown in figures A, B, and C (3).

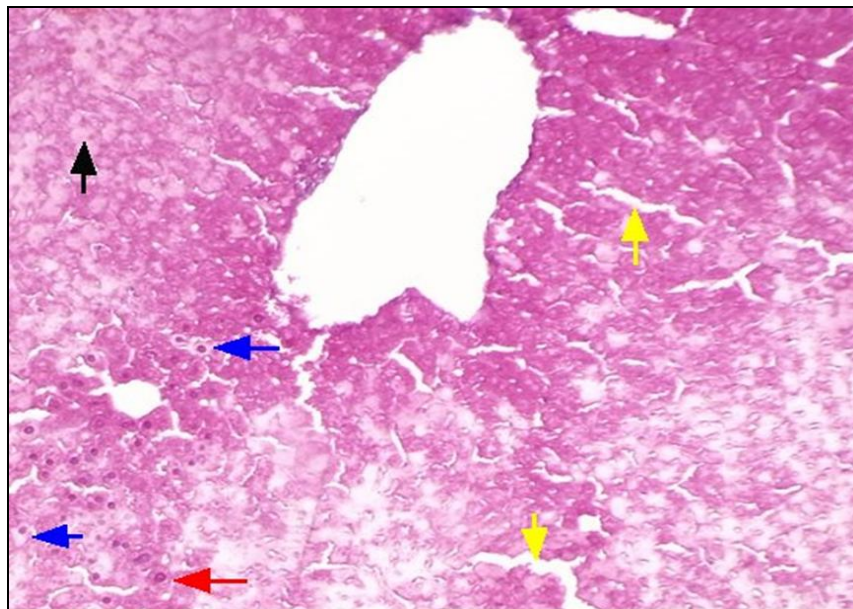


Figure (1): liver Section shows severe necrosis of hepatocytes (black arrow), hydropic degenerated hepatocytes (blue arrows), and dilated sinusoids (yellow arrows) were evident, but some viable cells were seen (red arrow), the first group (G1). H&E, 100X.

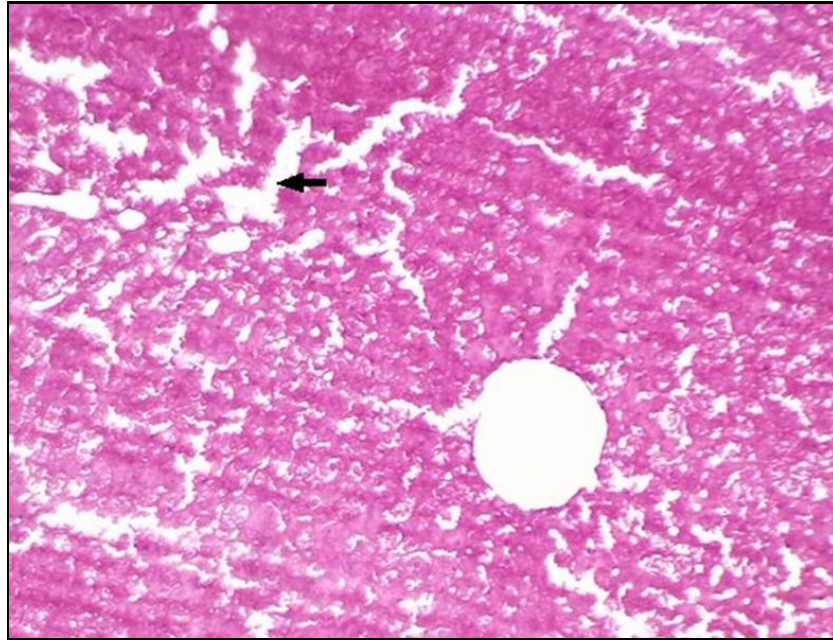


Figure (2): liver section shows severe dilatation of sinusoids (black arrows) and hepatocytes atrophy, the first group (G1) . H&E, 40X.

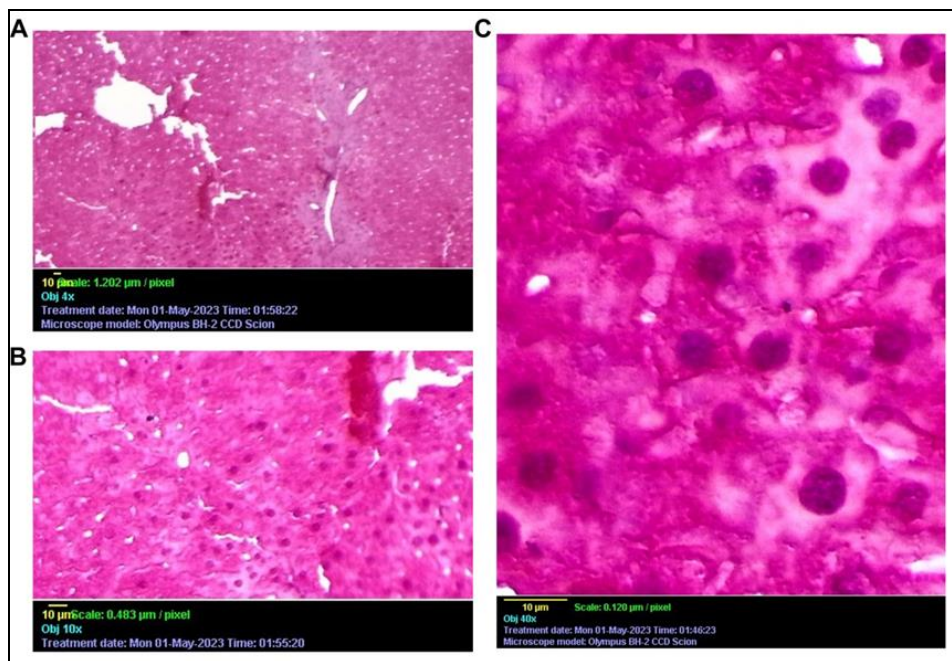


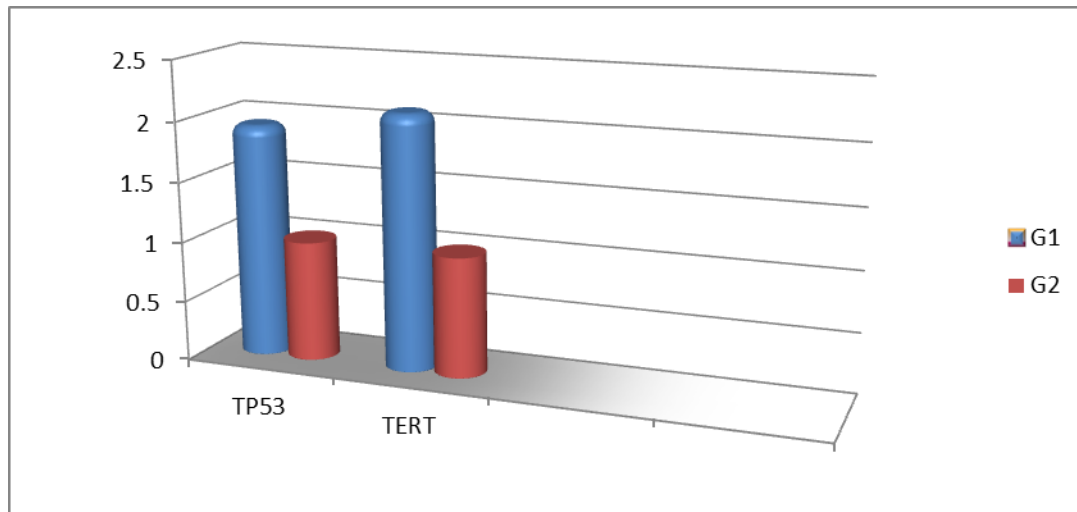
Figure (3): shows normal hepatocytes with normal liver architecture in three capture A, B, and C (control group) (G2) . H&E, 400X.

2- The gene expression:

The first group (G1) which administrated Nickel Chloride showed increase the gene expression of TP53 gene and TERT gene than in the control group, as table (3) and figure (3).

Table (3): shows the foldchange of the TP53, and TERT gene in the study groups

The gene	G1	G2
TP53	1.94 A	1 B
TERT	2.12 A	1 B

**Figure (4): shows level the foldchange (the gene expression) of TP53, and TERT gene in the study groups****Discussion:**

According to our results, Nickel Chloride causes severe necrosis of hepatocytes, hydropic degenerated hepatocytes, dilated sinusoids, severe dilatation of sinusoids, hepatocytes atrophy, severe hemorrhage, and loss of normal striation of the hepatocytes sheets, as compared with the control group.

The nickel chloride at sub-lethal doses have effects on bone-marrow chromosomes of the mice, and causes chromosomal anomalies (Mohanty, 1987). In a study that included mice were administrated NiCl₂ (170 mmol/kg) and killed at 6, 12, 24, and 48 h after injection. Ni-induced hepatic and results in hydroxyl radical (Chen, et, al. 1998). NiCl₂ causes DNA breaks, chromosome aberrations, and lipid peroxidation in the liver at the large dose. NiCl₂ accumulate in liver cells nuclei. NiCl₂-induced DNA strand breakage caused due to Fenton reaction, and hydroxyl radicals (Tammy J. et, al. 1992).

In th broiler chickens, NiCl₂ in the liver increased hepatic apoptosis, and activated the pathway of the mitochondria-mediated apoptotic. Fas, and FasL expression were increased. NiCl₂ causes increasing p53, p21 gene expression (Guo, H et, al. 2016). In a study used mice for evaluation of nickel on the liver structure, and Ni increases in liver necrosis, and apoptotic.

NiCl₂ causes hepatocyte degeneration, cellular swelling, nuclear pycnosis, and blood vessels congetion in liver (Gathwan, et, al. 2013), and that agreement with our results.

The serum antioxidant level decreased after taking nichel chroide at doses of 5, 15, and 25 mg/kg compared with the control. Level of MDA increased at the dose of 25 mg/kg, as compared to the control. Level of GST decreased at doses of 15 and 25 mg/kg. Nickel NPs induce the production of ROs, and low antioxidant in the liver tissue (Anoosha, et, al. 2020).

DNA damage induced by NiCl₂ in WBC of mice. the mice were administered orally NiCl₂ at doses of 3.4, 6.8, 13.6, 27.2, 54.4 and 108.8 mg/kg/ BW, showed that significant increase in DNA damage. The comet assay is a sensitive and rapid method to detect DNA damage due to Ni salts (Danadevi, et, al. 2004). Nickel salts induced toxicity and carcinogenicity, with generation reactive oxygen species. Nickel have haematotoxic, immunotoxic, neurotoxic, genotoxic, reproductive toxic, pulmonary toxic, nephrotoxic, hepatotoxic and carcinogenic agent. The histopathological changes occur in the liver which treated by a Nickel chloride are included degeneration, nuclear pycnosis, cellular swelling, necrosis, and congestion of blood vessels (Al-fatlawi, 2017), as come in our results.

Based on our findings, Nickel Chloride causes increase the gene expression of TP53 gene and TERT gene as compared with the control group. Nickel chloride was considred as carcinogens and causes fibrogenesis and tumorigenesis, as well as, Nickel chloride can effect on the gene expression of many gene particulary that related with the metabolic pathways (Wu, ch, et, al. 2017). The Nickel compounds increase histone ubiquitination, and that will further our understanding of the epigenetic mechanisms of nickel-mediated carcinogenesis (Qingdong, et, al. 2006). Nickel (Ni) are risk toxic industrial chemicals, Nickel causes the toxicity of the cells and tissues. Nickel induced oxidative stress with both similar and unique genes. As well as, causes DNA damage. Nickel induced a hypoxic, replacing iron in key proteins, and apoptosis (Permenter et, al. 2011). Nickel cause a toxicities in humans which leading into the cancer. Nickel chloride have negative impact on energy metabolism and global gene expression (Bannon, D. et, al. 2020).

Nickel chloride has adverse effects on several the groups in the mice. The Nickel chloride at dose 0, 7.5, 15 or 30 mg/kg body weight orally are dminstrated to the mice respectively. The sperm motility and number were reduced, and the malformation rates of the sperms were increased as compared with the control (G1) (Yue, et, al. 2021).

Conclusion:

In the end, Nickel Chloride causes histopathological changes in the liver tissue in mice, such as necrosis and hydropic of the hepatocyte, dilated sinusoids, severe dilatation of sinusoids, hemorrhage, and loss of normal hepatocytes striation; also, Potassium Dichromate causes to increase the gene expression of TP53 gene and TERT gene in mice that received Potassium Dichromate.

References:

Al-fatlawi, A. C. (2017). Histopathological changes of heavy metals Nickel Chloride (II) and Potassium dichromate (VI) on the Liver and Kidney of Swiss Male Mice. *kerbala journal of pharmaceutical sciences*, (13).

Anoosha, F., Seyedalipour, B., & Hoseini, S. (2020). Toxicity of Nickel Nanoparticles and Nickel Chloride on Activity of Antioxidant Enzymes and Level of Lipid Peroxidation in Liver and Serum of Rats. *ISMJ*, 23(1), 14-26.

Anoosha, Farnosh, Bagher Seyedalipour, Ali Taravati, and Monireh Movahedi. Comparative study on toxicity of Ni nanoparticle and Nickel chloride on liver enzymes and tissue in Rats." *jsums* (2018).

Bannon, D. I., Bao, W., Turner, S. D., McCain, W. C., Dennis, W., Wolfinger, R., ... & Abounader, R. (2020). Gene expression in mouse muscle over time after nickel pellet implantation. *Metallomics*, 12(4), 528-538.

Chen CY, Huang YL, Lin TH. Lipid peroxidation in liver of mice administrated with nickel chloride: with special reference to trace elements and antioxidants. *Biol Trace Elem Res*. 1998 Feb;61(2):193-205. doi: 10.1007/BF02784030. PMID: 9517490.

Danadevi K, Rozati R, Saleha Banu B, Grover P. In vivo genotoxic effect of nickel chloride in mice leukocytes using comet assay. *Food Chem Toxicol*. 2004 May;42(5):751-7. doi: 10.1016/j.fct.2003.12.013. PMID: 15046821.

Gathwan, K.H., Al-Karkhi, I.H.T. & Jaffar AL-Mulla, E.A. Hepatic toxicity of nickel chloride in mice. *Res Chem Intermed* 39, 2537–2542 (2013). <https://doi.org/10.1007/s11164-012-0780-x>

Gui-Hong Zheng, Chan-Min Liu, Jian-Mei Sun, Zhao-Jun Feng, Chao Cheng, Nickel-induced oxidative stress and apoptosis in *Carassius auratus* liver by JNK pathway, *Aquatic Toxicology*, Volume 147, 2014, Pages 105-111, ISSN 0166-445X, <https://doi.org/10.1016/j.aquatox.2013.12.015>.

Guo H, Cui H, Fang J, Zuo Z, Deng J, Wang X, Zhao L, Chen K, Deng J. Nickel chloride (NiCl₂) in hepatic toxicity: apoptosis, G2/M cell cycle arrest and inflammatory response. *Aging (Albany NY)*. 2016 Nov 5;8(11):3009-3027. doi: 10.18632/aging.101108. PMID: 27824316; PMCID: PMC5191883.

Ling Wei, Zhicai Zuo, Zhuangzhi Yang, Heng Yin, Yue Yang, Jing Fang, Hengmin Cui, Zongjun Du, Ping Ouyang, Xia Chen, Jian Chen, Yi Geng, Yanqiu Zhu, Zhengli Chen, Chao Huang, Fengyuan Wang, Hongrui Guo, Mitochondria damage and ferroptosis

involved in Ni-induced hepatotoxicity in mice, *Toxicology*, Volume 466, 2022, 153068, ISSN 0300-483X, <https://doi.org/10.1016/j.tox.2021.153068>.

Liu, C. M., Zheng, G. H., Ming, Q. L., Chao, C., & Sun, J. M. (2013). Sesamin protects mouse liver against nickel-induced oxidative DNA damage and apoptosis by the PI3K-Akt pathway. *Journal of agricultural and food chemistry*, 61(5), 1146-1154.

Mohanty, P. K. (1987). Cytotoxic effect of nickel chloride on the somatic chromosomes of Swiss albino mice *Mus musculus*. *Current Science*, 1154-1157.

Permenter MG, Lewis JA, Jackson DA (2011) Exposure to Nickel, Chromium, or Cadmium Causes Distinct Changes in the Gene Expression Patterns of a Rat Liver Derived Cell Line. *PLoS ONE* 6(11): e27730. <https://doi.org/10.1371/journal.pone.0027730>

Qingdong Ke and others, Alterations of histone modifications and transgene silencing by nickel chloride, *Carcinogenesis*, Volume 27, Issue 7, July 2006, Pages 1481–1488, <https://doi.org/10.1093/carcin/bgl004>

Schiefer, W.C. *Statistics for the biological sciences*; 2nd ed. Addison. Wesley pub comp, California, London, 1980.

Tammy J. Stinson, Sarah Jaw, Elizabeth H. Jeffery, Michael J. Plewa, The relationship between nickel chloride-induced peroxidation and DNA strand breakage in rat liver, *Toxicology and Applied Pharmacology*, Volume 117, Issue 1, 1992, Pages 98-103, ISSN 0041-008X, [https://doi.org/10.1016/0041-008X\(92\)90222-E](https://doi.org/10.1016/0041-008X(92)90222-E).

Wu, CH., Hsiao, YM., Yeh, KT. et al. Upregulation of microRNA-4417 and Its Target Genes Contribute to Nickel Chloride-promoted Lung Epithelial Cell Fibrogenesis and Tumorigenesis. *Sci Rep* 7, 15320 (2017). <https://doi.org/10.1038/s41598-017-14610-7>

Yue Yang, Zhicai Zuo, Zhuangzhi Yang, Heng Yin, Ling Wei, Jing Fang, Hongrui Guo, Hengmin Cui, Ping Ouyang, Xia Chen, Jian Chen, Yi Geng, Zhengli Chen, Chao Huang, Yanqiu Zhu, Wentao Liu, Nickel chloride induces spermatogenesis disorder by testicular damage and hypothalamic-pituitary-testis axis disruption in mice, *Ecotoxicology and Environmental Safety*, Volume 225, 2021, 112718, ISSN 0147-6513, <https://doi.org/10.1016/j.ecoenv.2021.112718>.