


<https://doi.org/10.33472/AFJBS.6.4.2024.219-230>



## African Journal of Biological Sciences



Research Paper

Open Access

### THE SIGNIFICANCE OF RADIOLOGICAL ASSESSMENT IN DETERMINING SURGICAL APPROACHES FOR THORACOLUMBAR SPINE TRAUMA MANAGEMENT

**Mukhsin M. Radjabov**

PhD student, Bukhara Branch of the Republican Scientific Center for Emergency Medicine, Bukhara, 200100, Uzbekistan

**Abdurakhmon U. Norov**

DSc., Professor, Bukhara Regional Multidisciplinary Medical Center, Bukhara, 200100, Uzbekistan

Article History

Volume 6, Issue 4, Feb 2024

Received: 17 Feb 2024

Accepted : 01 Mar 2024

doi:10.33472/AFJBS.6.4.2024.219-230

#### ABSTRACT

**Background:** Thoracolumbar spine injuries are common and often require surgical intervention for optimal patient outcomes. Radiological imaging plays a crucial role in the assessment and management of these injuries. This study aims to investigate the significance of various radiological modalities in guiding surgical treatment decisions for thoracolumbar spine traumas.

**Methods:** A comprehensive review of 180 patients with thoracolumbar spine injuries was conducted. Radiological assessments were performed using X-ray, computed tomography (CT), and magnetic resonance imaging (MRI). The study focused on evaluating the extent of spinal cord injury, vertebral fractures, kyphotic deformity, ligamentous injuries, and neural compression. The data collected from these imaging modalities were correlated with anatomical and biomechanical considerations to determine the appropriate surgical approach.

**Results:** Radiological assessments revealed diverse injury patterns within the thoracolumbar spine. Vertebral fractures ranged from minor compression to severe comminution, with L1 being the most commonly affected vertebra. Kyphotic deformities were observed in a significant number of cases, with varying degrees of severity. Ligamentous injuries and neural compression were also prevalent, particularly in patients with severe vertebral fractures. The extent and location of these radiological findings varied across different levels of the thoracolumbar spine.

**Conclusion:** Radiological imaging, including X-ray, CT, and MRI, plays a pivotal role in defining the surgical management strategy for thoracolumbar spine injuries. Precise radiological assessments provide critical insights into the nature and severity of the injury, helping clinicians make informed decisions regarding surgical interventions. By considering anatomical and biomechanical factors, surgeons can tailor their approach to each patient's unique injury pattern, ultimately improving patient outcomes and minimizing complications in the treatment of thoracolumbar spine injuries.

**KEYWORDS:** Thoracolumbar spine, Trauma management, Radiological assessment, Surgical approaches, Spinal injuries.

## INTRODUCTION

Spinal cord and spinal injuries, though relatively rare, present formidable medical challenges, occurring in approximately 0.7% to 4.0% of all injury cases, and their incidence is on the rise [1,5,7,8]. The complexity of these injuries often makes it impractical to rely solely on clinical data for surgical decision-making. To achieve precise diagnoses of spinal and spinal cord injuries, a comprehensive array of contemporary radiological diagnostic methods, including spondylography, multislice computed tomography (MSCT), and magnetic resonance imaging (MRI), must be employed [2,3,4,6]. Consequently, neurosurgeons must have access to a detailed understanding of not only the status of the spinal cord but also any damage sustained by the bony structures of the spine before embarking on surgical interventions [9,10,11].

In the contemporary landscape of medical practice, characterized by remarkable technological and methodological advancements, there exists a compelling mandate to critically scrutinize the various phases of radiological diagnostics [12,15]. This entails a process of continual refinement, augmentation, and elucidation of diagnostic criteria. Additionally, it calls for the development of a meticulously optimized, systematic protocol for the evaluation of patients who have sustained injuries to the thoracolumbar spine.

The principal objective of this study is to embark on a comprehensive and in-depth assessment of the capabilities inherent to modern radiological diagnostic methods in shaping the surgical treatment strategies tailored for thoracolumbar spine injuries. By undertaking this multifaceted investigation, we aspire to furnish invaluable insights into the pivotal and multifaceted role played by advanced radiological techniques in the intricate decision-making processes that underpin the surgical management of patients afflicted by such intricate and potentially life-altering injuries. Ultimately, the outcomes of this research endeavor are envisaged to serve as a cornerstone for the ongoing refinement, evolution, and enhancement of medical practices within the realm of spine and spinal cord injury management.

The study encompasses several pivotal research objectives that aim to propel the management of spine and spinal cord injuries to new heights. These objectives include developing radiological diagnostic criteria to establish comprehensive radiological diagnostic criteria that will serve as valuable guides in determining the most appropriate surgical treatment strategies. The study also focuses on enhancing surgical stabilization techniques, particularly for intricate traumatic fractures in the thoracolumbar spine, to ensure robust stability of the affected musculoskeletal segment while minimizing tissue trauma. Additionally, the research aims to improve

the differentiated surgical treatment approach for traumatic fractures of the thoracolumbar spine, taking into account the specific type of injury, its severity, and its stability, ultimately resulting in improved surgical outcomes. Furthermore, the study seeks to identify clear indications for various surgical approaches, including decompressive-stabilization, stabilization, and minimally invasive techniques, in the context of traumatic fractures of the thoracolumbar spine. This effort aims to reduce postoperative complications and optimize patient care. These research objectives collectively contribute to the scientific novelty of the study, with the potential to significantly advance the field of spine and spinal cord injury management, ultimately benefiting patients facing these challenging conditions.

## **METHODS AND DESIGN**

This research adopts a retrospective study design to analyze a cohort of patients with thoracolumbar spine injuries. The study population includes individuals who underwent radiological assessments and surgical interventions for their injuries. Data collection encompassed various radiological modalities, including spondylography, computed tomography (MSCT), and magnetic resonance imaging (MRI). The study's primary focus is to evaluate the efficacy of these modern radiological methods in determining the surgical treatment approach for thoracolumbar spine injuries.

## **DATA COLLECTION**

The scientific work is based on analyzing the diagnostics and surgical treatment results of 180 patients with acute vertebral and spinal cord injuries treated at the Bukhara branch of the Russian Research Center for Emergency Medicine from 2015 to 2020. By age, patients ranged from 19 to 77 years; the average age of patients was 37.2 years. In the study group, there were 80 sick men and 100 women, which amounted to 44.4% and 55.6%, respectively.

Among the causes of injury, patients with domestic trauma predominated - 71 patients (39.5%). The next group included victims of road traffic accidents - 55 (30.5%), other causes of injury (street and sports) accounted for 18 (33.4%) cases.

## **RADIOLOGICAL PARAMETERS**

X-rays of the spine were performed on all victims within one day of injury. First of all, the level of damage was determined on radiographs with the study of parameters characterizing the stability of the spinal motion segment. Of particular importance were the height and width of the vertebral bodies and intervertebral discs; the size of the interpedicular space and the symmetry of the vertebral pedicles; rotation of the spinous processes, which is an indicator of hidden torsion injuries, interspinous distance. According to Cobb's method, the degree of kyphotic deformation of the damaged part of the spine was determined (1948).

MSCT was performed on all 180 victims within 2-4 days after injury. MSCT of damaged segments was performed upon admission and at the stages of treatment. This type of study made it possible to determine the type of fracture according to F. Magerl's classification to clarify the nature of damage to the bone formations of the spine for differential diagnosis of previously existing spinal deformities from fresh injuries. MSCT reveals a fracture of the vertebral body, the condition of bone fragments, deformation of the spinal canal, fractures of the articular, transverse, and spinous processes, and arches - details of damage to the bone structures of all three columns of the spinal column.

In patients with severe neurological symptoms, MRI was used for a period of 3 days to several months after injury. The studies were performed in T1 and T2 modes. Sections were made in 2 mm increments. Neuroimaging of the spinal cord was carried out in the axial and frontal planes. The obtained tomograms were used to assess the nature and extent of traumatic changes in the spinal cord before surgery and the degree of their regression in the immediate and long-term postoperative observation periods. In addition, for subsequent analysis, a comparison was made of the level of damage, the degree of spinal canal compression, the size of the focus of the spinal cord contusion, and the severity of clinical symptoms. Magnetic resonance imaging had advantages over MSCT in detecting changes in soft tissue structures: ligaments, synovium (inner lining of the articular membrane), cartilage, nerve trunks, and muscles.

## **RESULTS AND DISCUSSION**

The examination of X-ray images from patients has enabled us to evaluate multiple parameters that provide insights into the degree of trauma stability and shed light on the nature of injuries, contingent upon the mechanism of the traumatic event.

One pivotal parameter for gauging the spinal stability of injured individuals is the dimensions of the vertebral body, specifically its height and width. To derive a comprehensive assessment, we conducted measurements on the compressed vertebral body and its two adjacent counterparts in both the ventral and dorsal aspects, involving the measurement of the distance between the cranial and caudal endplates. Subsequently, we determined the appropriate body height by calculating the arithmetic mean between the heights of the two adjacent bodies. The degree of compression was quantified as the difference between the proper body height and the measured height, expressed as a percentage.

In evaluating the extent of deformation, we relied on a relative index rather than absolute values, namely the Relative Index of Wedge Deformation (RIWD). The RIWD was ascertained through the ratio of the vertebral body's height in the anterior regions (H-anterior) to its height in the posterior regions (H-posterior),

expressed as a percentage. The formula employed for calculating RIWD is as follows:

$$\text{RIWD} = \left( 1 - \frac{\text{H-anterior}}{\text{H-posterior}} \right) * 100 \%$$

In cases of uniform compression like crash fractures or bi-convex fractures, the deformation index was assessed by comparing the average height (H-avg.) of the fractured vertebra to the average height (H-avg.) of adjacent vertebrae, expressed as a percentage. To calculate the uniform deformation index (UDI), the following formula was employed:

$$\text{UDI} = \left( 1 - \frac{2 * \text{H-avg. (fractured vertebra)}}{\text{H-avg. (above vertebra) + H-avg. (below vertebra)}} \right) * 100$$

Wedge deformation of the vertebrae was observed in all examined patients, accounting for 100% of cases (180 patients). The degree of compression varied from 5% to 80%. The largest group, comprising 70 patients (38.9%), consisted of those with a Wedge Deformation Index ranging from 26% to 50%.

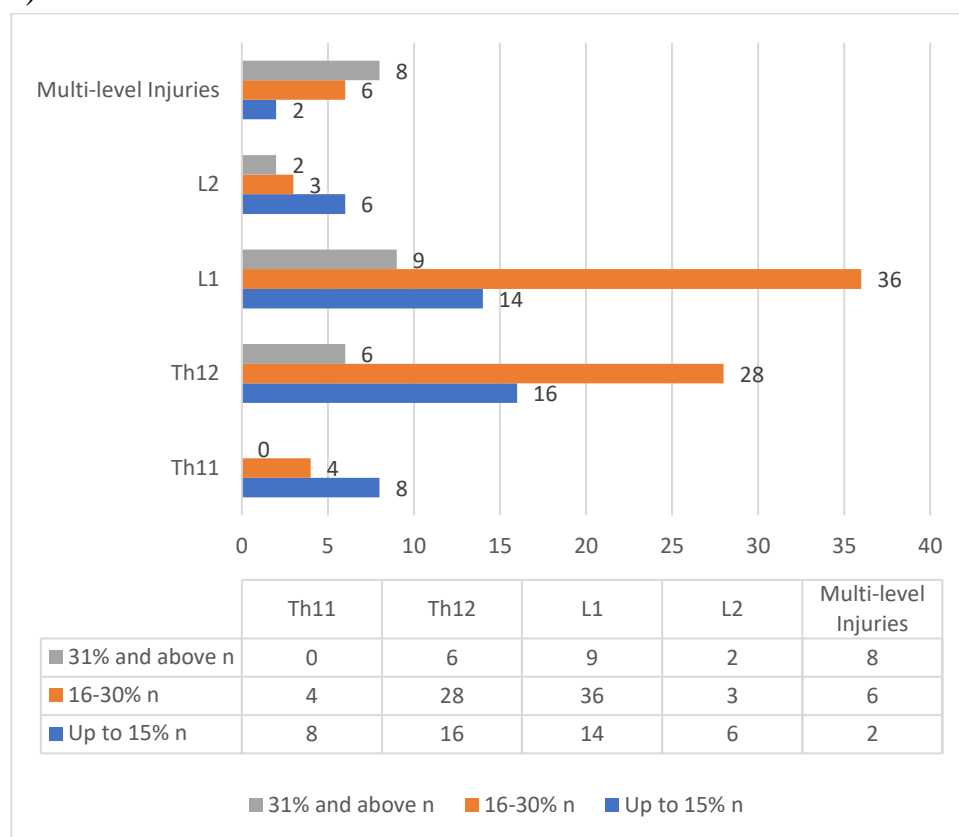
An indicator of the integrity of the central support column is the measurement of the interpedicular distance (ID). To determine the degree of increase in distance between the vertebral pedicles at the level of injury, we used the Interpedicular Distance Index (IDI), which was expressed as a percentage and calculated using the following formula:

$$\text{IDI} = \left( 1 - \frac{2 * \text{ID fractured vertebra}}{\text{ID above vertebra} + \text{ID below vertebra}} \right) * 100$$

Data analysis revealed that among the examined group of patients, an increase in interpedicular distance occurred in 118 patients (65.5%). Patients with an increase in distance between vertebral pedicles ranging from 5% to 20% constituted the largest subgroup, totaling 57 patients (32%). In 48 patients (26.7%) with severe spinal cord and spine injuries, an increase in interpedicular distance ranging from 21% to 40% was predominantly observed. Patients with severe injuries to all supporting structures (an increase in intervertebral distance exceeding 41%) amounted to 13 patients (7.2%), primarily represented by patients with injuries to L1 and L2 vertebrae (5 and 8 patients, respectively). In this group of patients, all exhibited varying degrees of neurological deficit.

When analyzing X-rays in the lateral projection, one of the significant indicators of injury stability was the angle of kyphotic deformation of the spine. Measurement was performed using the well-known Cobb method (1948). The distribution of patients based on the magnitude of post-traumatic kyphotic deformity is presented in Figure 1.

Figure 1.  
Indicators of Kyphotic Deformation Depending on the Level of Spinal Injury  
(n=180).



Thus, kyphotic deformation of the thoracolumbar spine was observed to some extent in 148 patients (82.2%). In 32 patients (17.2%), vertebral injuries were not accompanied by the development of pathological kyphosis. The highest percentage of injuries was observed in 77 patients (42.8%), characterized by moderate kyphotic deformity (16-30°). Among them, 36 patients had injuries to the L1 vertebra (20%). Severe post-traumatic spinal deformities (31° and above) were much less common, occurring in 25 cases (14%). In this group, patients with injuries to the Th12 and L1 vertebrae were distributed unevenly, accounting for 6% and 9% respectively. The group of patients with kyphotic deformity ranging from 1-15° accounted for 25.5% of cases and mainly consisted of patients with Th12 and L1 vertebrae injuries at 8.9% and 7.8%, respectively.

It is important to note that injuries in the thoracolumbar transition at the L2 vertebra level, accompanied by the formation of post-traumatic kyphosis, were rare, occurring in 11 patients (6.1%). Furthermore, the degree of deformation primarily ranged up to 15°. Kyphotic deformity of the spine was diagnosed in 16 patients with multi-level injuries, with the magnitude ranging from 16-30° in 6 patients (3.3%) and exceeding 30° in 8 patients (4.4%).

The posterior ligamentous complex is one of the important structures for the stability of the spinal motor segment. The primary load is borne by the supraspinous

and interspinous ligaments. The condition of these structures in X-rays is characterized by the magnitude of the interspinous distance. We measured the interspinous distance on axial radiographs as the distance between the tips of the spinous processes. The degree of increase in this parameter at the level of injury was determined by the ratio of the actual measurement obtained to the expected value, which represents the average interspinous distance at adjacent levels.

Analysis of the measurements showed that an increase in the interspinous distance or damage to the posterior ligamentous complex in spinal injuries at the thoracolumbar transition was observed in 89 patients (49.5% of cases). In most cases, disruptions in the integrity of the posterior ligamentous complex occurred with injuries to the L1 vertebra in 33 patients (18.3%), primarily with moderate and severe increases in the interspinous gap. Trauma to the Th12 vertebra, as a rule, was associated with moderate increases in the interspinous distance (1-30% and 31-60%) in 29 patients (16.2% of cases). Injuries to the L2 vertebra mostly (7 patients, 3.9%) were characterized by non-severe and moderate (4 patients, 2.2% of cases) disruptions of the posterior ligamentous complex. Furthermore, it should be noted that vertebral injuries in the thoracolumbar transition of the spine, not accompanied by an increase in the interspinous distance, were prevalent in patients with injuries to the L2 vertebra.

In addition, spondylography was used to determine the presence and degree of anterior-posterior or lateral vertebral dislocation. Measurements were taken on radiographs in lateral and anterior-posterior projections, and the degree of dislocation was expressed as a percentage in relation to the adjacent vertebrae. According to our data, vertebral dislocations and subluxations in the thoracolumbar transition occurred in 18 patients (10% of cases). It should be noted that lateral vertebral dislocation was observed in only 9 patients (5% of cases), and always in combination with anterior-posterior dislocation.

In the analysis of the data, it was found that dislocations were most commonly observed in injuries to the L1 vertebra in 23 patients (12% of cases). However, in terms of the frequency of injuries at each specific level, it is important to note that dislocations most frequently occurred with trauma to the Th12 vertebra. Displacements of the Th11 and L2 vertebrae were found in 12 patients (6.8% of cases), with 6 patients in each group, but they differed in severity. The degree of dislocation in Th12 vertebral injuries in 20 patients (11.1%) was mostly within moderate ranges.

Among all the available radiological methods for examining patients with spinal injuries, multidetector computed tomography (MDCT) is often preferred as the most informative method. MDCT examination allows for the precise determination of the normal morphometric parameters of the thoracolumbar

vertebrae, as well as the characterization of changes that occur in cases of injury [13,14,18].

MDCT examinations were performed on all patients with traumatic vertebral injuries in the thoracolumbar transitional region of the spine and on all patients after surgical interventions. The examination of the vertebrae was conducted using spiral or stepwise modes, followed by multiplanar and 3D reconstruction. Measurements of the parameters of interest were made based on both MDCT scans and 3D reconstructions.

The examination of each of the 180 patients involved MDCT scanning of the transitional region (Th11-L2). Measurements were taken in the axial, sagittal, and coronal planes. Parameters of both injured and uninjured vertebrae were examined.

The analysis of injuries was conducted in two stages. The first stage involved reviewing a series of cross-sectional images in both 'bone' and 'soft tissue' modes. The parameters of window width and center for the 'bone window' were not fixed and were adjusted for each individual case, taking into account the severity of traumatic changes in the vertebrae. Subsequently, the images were examined in the 'soft tissue' window. During this stage, the condition of soft tissue structures within the spinal canal and paravertebral soft tissues was analyzed. The second stage of the analysis involved obtaining secondary reconstructed images using the software's function in two standard planes, and, if necessary, in arbitrarily selected planes.

Quantitative measurements were performed on the ventral, midline, and dorsal heights of the injured vertebra, adjacent intervertebral discs, critical distance, Urbani wedge, and bone block density at various stages of treatment. Measurements of the ventral, midline, and dorsal heights of the vertebra, as well as the ventral and midline heights of adjacent intervertebral discs, were conducted based on multiplanar reconstructions. The degree of pathological or traumatic vertebral rotation was measured in axial views.

The rotational component was most frequently diagnosed in cases of L1 vertebral injuries, occurring in 29 out of 53 patients, which accounted for 54.7% of cases. It was less common in cases of L2 vertebral injuries, where it was observed in 48.4% of cases (15 cases out of 31). It is worth noting that the degree of vertebral rotation in injuries at these levels was generally characterized by significant values. Injuries to the Th12 vertebra were rarely complicated by vertebral rotation, occurring in 19 out of 63 patients (30.1% of cases). Trauma to the Th11 vertebra occurred only in 2 cases out of 15, accounting for 13.3% with minimal rotational components.

The size of the spinal canal and potential canal stenosis were measured in axial sections. The area of the spinal canal and the degree of stenosis were measured using a specialized computer program developed by our team.

The data analysis revealed that the most severe traumatic narrowing of the



spinal canal (51% and above) was observed at the levels of the Th12 and L1 vertebrae in 15 patients (8.3%) and 16 patients (8.9%), respectively, primarily due to vertebral body fractures and the Urbani wedge. Narrowing of the spinal canal at the level of the Th11 vertebra was diagnosed in 14 patients (7.8% of cases), with half of them experiencing severe stenosis of the spinal canal. Stenosis at the level of the L2 vertebra was noted in 20 patients (11.1%), with 11 patients having more than 50% narrowing of the spinal canal.

To objectify the assessment of bone density in the absence of a densitometer and quantitative MDCT, we used the determination of radio density of bone tissue based on MDCT data, expressed as an attenuation coefficient. As a result of the study, we obtained data that we used to assess the degree of decreased bone density and for preoperative planning.

Magnetic Resonance Imaging (MRI) was performed on 120 patients with injuries to the transitional thoracolumbar region of the spine who were subsequently operated on based on established indications. The examinations were conducted in T1 and T2 modes, and visualization of the spinal cord was performed in axial and frontal planes. Among the examined patients, 84 individuals exhibited neurological symptoms to varying degrees, while the remaining 36 patients with uncomplicated thoracolumbar spine injuries were included as the control group. Additionally, in 12 cases, MRI was performed for L2 vertebral injuries, with the evaluation focused solely on the degree of compression of the cauda equina nerve roots.

According to the MRI data, the majority of the 88 patients (73.3%) with complicated thoracolumbar vertebral injuries exhibited pathological changes in the spinal cord of traumatic origin (Table 1). Patients with total and severe neurological symptoms (Groups A, B, C) consistently presented MRI evidence of spinal cord injury. Absence of focal contusion in the presence of partial neurological deficits (Group D) was observed in 14 injured individuals, with 7 of them having an L1 vertebral injury. Examination of the control group of patients with uncomplicated injuries (Group E) did not reveal any pathological changes in the spinal cord.

Table 1.

Correlation of MRI Findings of Spinal Cord Contusion and Severity of Neurological Symptoms (n=88).

Level of Injury					
	A	B	C	D	E
Th11	3	4	4	-	-

Th12	4	4	6	-	-
L1	2	4	7	14(*3)	12(*12)
L2	1	2	3	10(*4)	8(*8)
Total	10	14	20	24(*7)	20 (*20)

(\*) - the number of patients with no MRI signs of spinal cord injury.

The MRI examination allowed us to identify several types of spinal cord injury. We classified them as follows: the presence of blood impregnation in the brain tissue, accompanied by perifocal edema, in other words, the presence of a focal spinal cord contusion. Among the patients, 22 individuals (25%) had a contusion zone occupying only a part of its cross-section, while total damage across the entire cross-section of the spinal cord was diagnosed in 11 patients (12.5%). Severe injuries to the thoracolumbar vertebrae often led to anatomical damage to the spinal cord, which is the crushing of its substance, and MRI examination in all cases provided an objective picture. Total spinal cord damage was always accompanied by a large zone of substance edema, affecting 1-2 adjacent spinal cord segments. The severe spinal cord injury pattern was most commonly associated with Th11 vertebra injuries (80%). At the Th12 vertebra level, we observed an equal distribution between total and partial types of spinal cord injury (50% each). For L1 vertebra injuries, mild forms of damage prevailed (81.8%).

Detecting bone injuries with minor visible morphological changes, such as vertebral compression and cortical plate rupture, can be challenging using computed tomography (CT)[16,17]. Magnetic resonance imaging (MRI) is a highly sensitive method for identifying such injuries. It can reveal bone marrow edema and hemorrhaging as hyperintense signals on fluid-sensitive sequences, such as Short-Tau Inversion Recovery (STIR). Injuries to prevertebral soft tissues are primarily manifested on MRI as abnormal thickening. This manifestation is often associated with trauma due to hyperextension and vertebral body fractures. When muscles are tense, edema appears as high signal intensity on STIR images, whereas hemorrhage into muscles may result in non-uniform signal intensity, depending on the extent and stages of hemorrhaging mixed with edema. Isolated muscle injuries are typically not clinically significant, but they can explain the source of pain in the absence of other significant injuries.

## CONCLUSION

Thus, radiological diagnostic methods have allowed us to identify patterns of injuries specific to each of the thoracolumbar vertebrae and correlate them with the

anatomical and biomechanical characteristics of this region of the spine. The obtained results were subsequently used to systematize injuries in the thoracolumbar transition zone and to determine the surgical treatment approach for this category of patients.

## REFERENCES

1. Abudou M, Chen X, Kong X. Surgical versus non-surgical treatment for thoracolumbar burst fractures without neurological deficit. *Cochrane Database Syst Rev.* 2013 Jun 6;(6):CD005079. doi: 10.1002/14651858.CD005079.pub3.
2. Rantanen J, Hurme M, Falck B, et al. The lumbar multifidus muscle five years after surgery for a lumbar intervertebral disc herniation. *Spine.* 1993;18.
3. Aebli N. Cardiovascular changes during multiple vertebroplasty with and without vent-hole. *Spine.* 2003;28(14):1504-1512.
4. Wu H, Zhao DX, Jiang R. Surgical treatment of Denis type B thoracolumbar burst fracture with neurological deficiency by paraspinal approach. *Braz J Med Biol Res.* 2016;49(11):e5599.
5. Xu BS, Tang TS, Yang HL. Long-term results of thoracolumbar and lumbar burst fractures after short-segment pedicle instrumentation, with special reference to implant failure and correction loss. *Orthop Surg.* 2009;1:85-93. DOI: 10.1111/j.1757-7861.2009.00022.
6. Alleyne CH, Corporectomy and stabilization with methylmethacrylate in patients with metastatic disease of the spine: a technical note. *J Spinal Disord.* 1995;8(6):439-443.
7. Yang M, Ding GZ, Xu ZJ. Surgical outcome in thoracolumbar fractures managed by short-segment pedicle instrumentation. *Ann Acad Med Singapore.* 2014 Jan;43(1):24-32.
8. Altay M, Ozkurt B, Aktekin CN. Treatment of unstable thoracolumbar junction burst fractures with short- or long-segment posterior fixation in Magerl type A fractures. *Eur Spine J.* 2007 Aug;16(8):1145-1155.
9. Xue F, Fu ZG, Zhang DY, et al. Minimal invasive internal fixation with U-shaped break-off pedicle screws for treatment of thoracolumbar fractures. *Beijing Da Xue Xue Bao.* 2013 Oct 18;45(5):728-731.
10. Aly TA. Spinal shortening and monosegmental posterior spondylodesis in the management of dorsal and lumbar unstable injuries. *J Neurosci Rural Pract.* 2011 Jan;2(1):17-22. doi: 10.4103/0976-3147.80082.

11. Rehman R, Azam F. Treatment of traumatic unstable thoracolumbar junction fractures with transpedicular screw fixation. *J Pak Med Assoc.* 2011;61(10):1005-1008.
12. Anekstein Y, Brosh T, Mirovsky Y. Intermediate screws in short segment pedicular fixation for thoracic and lumbar fractures: a biomechanical study. *J Spinal Dis Tech.* 2007;20(1):72-77.
13. Antoni M, Charles YP, Walter A. Fusion Rates of Different Anterior Grafts in Thoracolumbar Fractures. *J Spinal Disord Tech.* 2015 Nov;28(9):E528-533. doi: 10.1097/BSD.0b013e3182aab2bf.
14. Reinhold M, Knop C, Beisse R, Audige L, Kandziora F, Pizanis A, Pranzl R, Gercek E, Schultheiss M, Weckbach A, Buhren V, Blauth M. Operative treatment of traumatic fractures of the thoracic and lumbar spinal column: Part I: Epidemiology. *Unfallchirurg.* 2009;112(1):33-45.
15. Aras EL, Bungler C, Hansen ES. Health-care costs of conservative management of spine fractures in trauma patients. *Eur Spine J.* 2016 Oct 21. DOI: 10.1007/s00586-016-4806-8.
16. Barbagallo GM, Yoder E, Dettori JR, Albanese V. Percutaneous minimally invasive versus open spine surgery in the treatment of fractures of the thoracolumbar junction: a comparative effectiveness review. *Evid Based Spine Care J.* 2012 Aug;3(3):43-49. doi: 10.1055/s-0032-1327809.
17. Avilés C, Flores S, Molina M. Conservative versus operative treatment for thoracolumbar burst fractures without neurologic deficit. *Medwave.* 2016 Mar 15;16 Suppl 1:e6383. doi: 10.5867/medwave.2016.6383.
18. Ayberk G, Ozveren M, Altundan N, et al. Three column stabilization through posterior approach one: transpedicular placement of distractable cage with transpedicular screw fixation. *Neurol Med Chir (Tokyo).* 2008;1:8-14.